

# Cardiothoracic Anesthesia, Respiration and Airway

## Early clinical experience with a new videolaryngoscope (GlideScope®) in 728 patients

*[Expérience clinique préliminaire avec un nouveau vidéolaryngoscope (GlideScope®) chez 728 patients]*

Richard M. Cooper MSc MD,\*† John A. Pacey MD,‡ Michael J. Bishop MD,§ Stuart A. McCluskey PhD MD\*

**Purpose:** To evaluate a new videolaryngoscope and assess its ability to provide laryngeal exposure and facilitate intubation.

**Methods:** Five centres, involving 133 operators and a total of 728 consecutive patients, participated in the evaluation of a new videolaryngoscope [GlideScope® (GS)]. Many operators had limited or no previous GS experience. We collected information about patient demographics and airway characteristics, Cormack-Lehane (C/L) views and the ease of intubation using the GS. Failure was defined as abandonment of the technique.

**Results:** Data from six patients were incomplete and were excluded. Excellent (C/L 1) or good (C/L 2) laryngeal exposure was obtained in 92% and 7% of patients respectively. In all 133 patients in whom both GS and direct laryngoscopy (DL) were performed, GS resulted in a comparable or superior view. Among the 35 patients with C/L grade 3 or 4 views by DL, the view improved to a C/L 1 view in 24 and a C/L 2 view in three patients. Intubation with the GS was successful in 96.3% of patients. The majority of the failures occurred despite a good or excellent glottic view.

**Conclusions:** GS laryngoscopy consistently yielded a comparable or superior glottic view compared with DL despite the limited or lack of prior experience with the device. Successful intubation was generally achieved even when DL was predicted to be moderately or considerably difficult. GS was abandoned in 3.7% of patients. This may reflect the lack of a formal protocol defining failure, limited prior experience or difficulty manipulating the endotracheal tube while viewing a monitor.

**Objectif :** Évaluer un nouveau vidéolaryngoscope et tester sa capacité à fournir une exposition du larynx et à faciliter l'intubation.

**Méthode :** Cinq centres, impliquant 133 opérateurs et 728 patients consécutifs, ont participé à l'évaluation du nouveau vidéolaryngoscope [GlideScope® (GS)]. De nombreux opérateurs avaient une expérience nulle ou limitée du GS. Nous avons noté les données démographiques et les caractéristiques des voies aériennes, la classification Cormack-Lehane (C/L) des visualisations et la facilité à intuber avec le GS. Un échec était défini comme un abandon de la technique.

**Résultats :** Six patients ont été exclus à cause de données incomplètes. Une excellente (C/L 1) ou une bonne (C/L 2) exposition du larynx a été obtenue chez 92 % et 7 % des patients respectivement. Chez les 133 patients soumis aux deux tests avec le GS et à la laryngoscopie directe (LD), le GS a donné des résultats comparables ou une vue supérieure. Parmi les 35 patients avec un grade 3 ou 4 de C/L par LD, la visualisation s'est améliorée à 1 C/L chez 24 patients et à 2 C/L chez trois patients. L'intubation avec le GS a été réussie chez 96,3 % des patients. La majorité des échecs sont survenus malgré une bonne ou une excellente visualisation glottique.

**Conclusion :** La laryngoscopie avec le GS fournit toujours une vision glottique comparable ou supérieure à la LD malgré l'expérience nulle ou limitée avec l'appareil. L'intubation a été généralement réussie même lorsqu'on prévoyait une difficulté modérée ou importante de la LD. Le GS a été abandonné chez 3,7 % des patients. Cela pourrait correspondre au manque de protocole formel définissant l'échec, à l'expérience antérieure limitée ou à la difficulté de manipuler le tube endotrachéal tout en surveillant l'écran.

From the Department of Anesthesia, Toronto General Hospital,\* University of Toronto, Toronto, Ontario; Saturn Biomedical Systems,† Faculty of Medicine,‡ University of British Columbia, Vancouver, British Columbia, Canada; and the Departments of Anesthesiology and Medicine, University of Washington and Veterans Affairs Puget Sound Health Care System,§ Seattle, Washington, USA.

Address correspondence to: Dr. Richard M. Cooper, Department of Anesthesia and Pain Management, Toronto General Hospital, 200 Elizabeth Street, 3 EN-421, Toronto, Ontario M5G 2C4, Canada. Phone: 416-340-3242; Fax: 416-340-3698; E-mail: richard.cooper@uhn.on.ca

Funding: none

Conflicts: J. A. P. is the developer of the GlideScope® and CEO of Saturn Biomedical Systems, its manufacturer. R. M. C. is a consultant to and investor in Saturn Biomedical Systems. R. M. C. has received travel subsidies from Saturn.

Accepted for publication August 5, 2004.

Revision accepted November 8, 2004.

**D**ESPITE careful airway assessment, direct laryngoscopy (DL) occasionally yields unexpectedly poor laryngeal views.<sup>1</sup> Such difficulties, even if ultimately successful, may result in multiple laryngoscopic attempts and be associated with hypertension, oxygen desaturation, airway and dental injuries, intensive care unit admission, neurologic impairment and death.<sup>2,3</sup> The search for alternatives to DL has resulted in numerous supra-glottic devices for routine use and airway rescue. Intubation techniques include blind nasal and digital intubation, the Intubating Laryngeal Mask Airway (LMA; blind, lightwand- or fiberoptic-assisted), use of a gum-elastic bougie, lightwand and ferro-magnetic intubation, flexible fiberoptic intubation and a variety of rigid fiberoptic techniques. Many of these may be impractical due to the time required to perform them, their complexity, reliability, high cost or limited availability of the equipment. Some do not provide visualization of the endotracheal tube (ETT) as it passes through the glottis. Even flexible fiberoptic intubation, the gold standard for managing the complex airway, becomes essentially a blind procedure after the scope enters the trachea, using the sophisticated device as a stylet over which the ETT is railroaded.

Rigid fiberoptic laryngoscopes offer the advantage of providing a non-line-of-sight view of the airway and visual control of ETT advancement. Examples include the Bullard laryngoscope (ACMI, Circon, Santa Barbara, CA, USA), the WuScope (Achi Corporation, Freemont, CA, USA) and the Upsherscope Ultra (Mercury Medical, Clearwater, FL, USA). It has been demonstrated that success of one of these devices was unrelated to traditional predictors of difficulty,<sup>4</sup> however despite this, they are not widely used.<sup>5,6</sup> It would appear that these useful techniques have a learning curve which results in frustration and abandonment by many prospective operators before they acquire competence.

Recently, miniature video-chips called "charge coupled devices" (CCD) have become widely available. A robust, high-resolution fog-resistant camera is small enough to be embedded into a laryngoscope blade. This allows for the transmission of a video-image to a monitor, enabling the operator to visualize an object not necessarily in the line-of-sight. The operation of this laryngoscope is sufficiently similar to conventional laryngoscopy that we anticipated easy adoption by new operators. We hypothesized that even novice users would obtain a better laryngeal view compared with DL. We compared the laryngeal views provided by the videolaryngoscope with historical data and a limited number of side-by-side comparisons. We also determined the ease and rate of successful tracheal intubation.




FIGURE 1 The GlideScope® videolaryngoscope is shown. Note the 60° upward angulation of the blade. A power cord/video cable, emerging from the handle, attaches to a dedicated LCD monitor. Illumination is provided by two light emitting diodes (red and blue). A small black and white charge coupled device (CCD) camera is lateral to the diodes (reprinted with permission, *Can J Anesth* 2003; 50: 612).

## Methods

The GlideScope® (GS) videolaryngoscope (Saturn Biomedical Systems, Burnaby, BC, Canada) was developed by one of the authors (J. A. P.). It is similar to a Macintosh blade but the blade has a pronounced 60° angulation. A video camera is situated on the inferior aspect of the blade at its inflection point (Figure 1). The view obtained is oriented anteriorly and the camera is sufficiently remote from the glottis to provide a wide visual field. Two light emitting diodes adjacent to the video-chip provide adjustable illumination. A black and white image is displayed on a dedicated lightweight 7-inch (17.8 cm) monitor (Figure 2) and can also be displayed on other devices or recorded using a standard video output port (NTSC). Following a controlled clinical evaluation by two of the authors (J. A. P. and R. M.

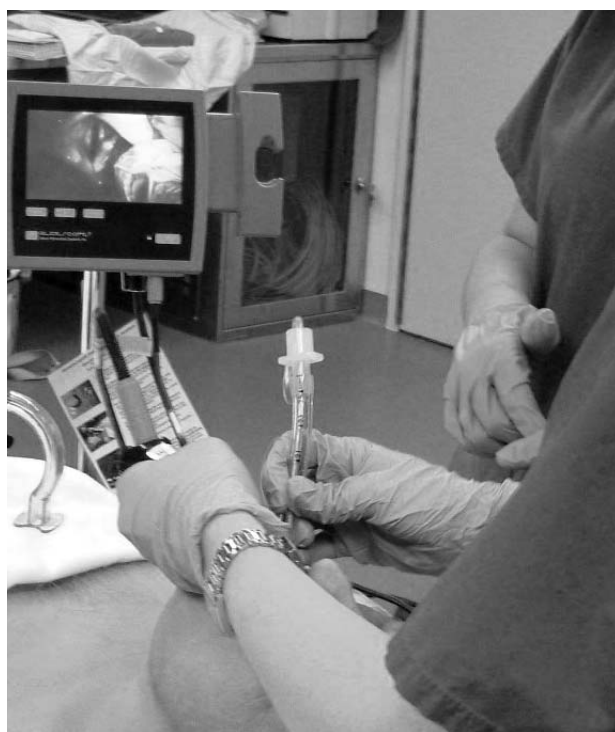

FIGURE 2 Laryngoscopy and endotracheal tube (ETT) insertion. The GlideScope® (GS) has been inserted into the vallecula and the epiglottis is seen at the top of the monitor. The ETT cuff is seen as it approaches the glottis [Cormack-Lehane (C/L I view)]. Note that the laryngoscope has been introduced in the midline, as has the ETT.

C.) or under their direct supervision, the GS was made available to anesthesiologists at The University Health Network (consisting of Toronto General Hospital, Toronto Western Hospital and Princess Margaret Hospital, Toronto, ON, Canada), Burnaby Hospital (Burnaby, BC, Canada) and Veterans Affairs Puget Sound Health Care System (Seattle, WA, USA) for use in their clinical practice.

With Institutional Ethics Board approval, data were contemporaneously recorded by the laryngoscopist or an assistant on a datasheet and subsequently transferred to a database (Microsoft Access, Microsoft Corporation, Redmond, WA, USA). A formalized study protocol was not used but information was collected identifying the operator, patient demographics (age, height and weight) and airway assessment features (modified Mallampati score,<sup>7</sup> inter-incisor gap, thyromental distance and cervical mobility). Operators, or in




FIGURE 3 The endotracheal tube on the left has a malleable stylet configured in a shape similar to the distal GlideScope® (GS) blade. The endotracheal tube on the right is fitted with a Parker Flex-It™ stylet which provides adjustable, anterior angulation.

the case of students and respiratory therapists, the attending anesthesiologist were requested to predict the difficulty intubating had DL been used (grade I = easy, II = slightly difficult, III = moderately difficult, IV = very difficult), to identify the Cormack-Lehane (C/L) view<sup>8</sup> with GS laryngoscopy and the ease or difficulty of intubating with the GS. If DL had been performed, either prior to or subsequent to videolaryngoscopy, the anesthesiologist was requested to record the C/L grade for comparison.

Instruction was available if requested, although it was not provided in a standardized fashion. During the early stages of this evaluation an experienced user, if available, offered suggestions about the GS technique. The recom-

TABLE I Airway characteristics

	<i>Unfavourable characteristics</i>	<i>Favourable characteristics</i>
Inter-incisor gap	≤ 3 cm = 31 (4.5)	> 3 cm = 651 (95.5)
Thyromental distance	< 6 cm = 204 (30.9)	≥ 6 cm = 457 (69.1)
Cervical spine mobility	Reduced = 113 (15.6)	Normal = 609 (84.4)
Mallampati view	III + IV = 119 + 28 = 147 (20.4)	I + II = 279 + 295 = 574 (79.6)
Predicted difficulty for DL (83.8)	III + IV = 82 + 13 = 95 (15.4)	I or II = 351 + 166 = 517

As some of the data are lacking, the totals in each row do not equal the total numbers of patients studied. The numbers in parentheses are percentages. Prediction of difficulty for direct laryngoscopy (DL) was defined as easy (I), somewhat difficult (II), moderately difficult (III) or very difficult (IV).

TABLE II Mallampati class vs GS laryngeal view

<i>Cormack-Lehane view</i>	<i>C/L 1</i>	<i>C/L 2</i>	<i>C/L 3</i>	<i>C/L 4</i>	<i>Totals (%)</i>
Mallampati I	245	9	0	0	254 (36.6)
Mallampati II	269	25	1	3	298 (42.9)
Mallampati III	104	11	0	0	115 (16.6)
Mallampati IV	21	3	2	1	27 (3.9)
Totals (%)	639 (92)	48 (7)	3 (< 0.05)	4 (< 0.05)	

Relationship between the modified Mallampati oropharyngeal view and the GlideScope® (GS) Cormack-Lehane (C/L) laryngoscopic view. 21/27 (77%) patients with a Mallampati class IV view had a C/L grade 1 view. Overall, 92% of the study patients had a C/L grade 1 view and 99% had a grade 1 or 2 view using the GS.

mended technique was as follows: an ETT was prepared with a malleable stylet, using a 60° curvature or a Parker Flex-It™ stylet (Parker Medical, Englewood, CO, USA); (Figure 3). The patient was positioned according to the preference of the user. Following preoxygenation, general anesthesia and neuromuscular blockade were induced if clinically appropriate; a rapid sequence technique was utilized if indicated; the GS was inserted in the midline; the uvula was identified and used as the first landmark to ensure the blade was in the midline and correctly oriented; the blade was preferentially introduced into the vallecula or posterior to the epiglottis if the latter obscured the glottis. After advancing the tip of the ETT through the vocal folds, the stylet was withdrawn. In some cases, slight rotation of the ETT was required after removing the stylet to facilitate passage into the trachea. The GS was withdrawn after visual confirmation of tracheal placement. Auscultation and capnography were performed as additional tests of appropriate tube placement.

Patient selection was at the discretion of the anesthesiologist though sometimes the device was unavailable. Shortly after its introduction, many operators selected the GS for intubations anticipated to be difficult, when bag-mask ventilation was not expected to be problematic.

The user was requested to describe the intubation as “easy,” “awkward” or “failed.” Failure of GS intubation was not defined by protocol – the technique

was regarded as a failure if it was abandoned in favour of an alternative method. In a few cases, an alternative technique was resorted to if the first GS attempt was unsuccessful. No recommendations were provided regarding the number of recommended or permitted GS attempts.

All attempted GS intubations between November 2001 and March 2003 were included. Data were excluded when the user or outcome information could not be determined from the care-provider or datasheets. Statistical analysis was performed using a statistical software program (SAS version 8.20, SAS Institute, Cary, NC, USA). Data are expressed as mean ± SD.

## Results

### Operators

The laryngoscopists ranged from medical and respiratory therapy students with no prior laryngoscopy experience to senior attending anesthesiologists. A total of 133 operators were involved, performing or participating in laryngoscopies on from one to 115 patients. There were insufficient data to determine whether the extent of prior experience with DL resulted in better glottic visualization with GS or a greater likelihood of successful intubation.

TABLE III Comparisons of DL and GS views

View by DL	View by G/S			
	C/L 1	C/L 2	C/L 3	C/L 4
C/L 1 <i>n</i> = 65 (48.9)	60	3	0	0
C/L 2 <i>n</i> = 33 (24.8)	30	3	0	0
C/L 3 <i>n</i> = 20 (15.0)	15	1	2	2
C/L 4 <i>n</i> = 15 (11.3)	9	2	0	4
Totals <i>n</i> = 133	114 (85.7)	9 (6.8)	2 (1.5)	6 (4.5)

Comparisons of laryngeal views [Cormack-Lehane (C/L)] obtained by direct laryngoscopy (DL) and GlideScope® (GS) in 133 patients. Of special interest are the 35 patients with a C/L grade 3 or 4 by DL. In 27 (77%) an excellent or good laryngeal view was obtained by GS. Overall a C/L grade 1 view was obtained in 48.9% of patients by DL and 85.7% of patients by GS. In 4.5% of patients, no view was obtained either because of severe anatomical distortion (1) or, more frequently, difficulty inserting the GS into the oropharynx.

TABLE IV "Risk" characteristics *vs* laryngeal view and intubation success with the GlideScope®

Category	Number	C/L 1-2	C/L 3-4	Intubation-S	Intubation-F
Weight $\geq$ 100 kg	104	102	2	101	3
BMI $>$ 40	30	28	2	29	1
Reduced C/S	100	97	3	95	5
Inter-incisor gap $\leq$ 3 cm	31	29	2	28	3

Morbid obesity, reduced cervical extension or a small oral aperture did not appear to be associated with difficult visualization or intubation. C/L = Cormack-Lehane; BMI = body mass index; C/S = cervical spine mobility; S = successful; F = failed.

### Patients

Between November 2001 and March 2003, data were collected on 728 consecutive GS laryngoscopies. Outcome data (laryngeal view or success of tracheal intubation) or user identification were unavailable in six instances and these data have not been included in the analysis. The patient demographics were as follows (mean  $\pm$  SD): age 54.4 ( $\pm$  15.5); body weight 70.3 ( $\pm$  18.8) kg; height 168.1 ( $\pm$  11.3) cm and body mass index 27.8 ( $\pm$  6.2) kg·m<sup>-2</sup>. The airway characteristics are displayed in Table I. Operators provided their prediction of difficulty had DL been used for 617 (85%) patients. DL was expected or known (based on previous records) to be easy in 351 (57%) cases, slightly difficult in 166 (27%), moderately difficult in 82 (13%) and very difficult in 18 (3%).

### Laryngeal views

As shown in Table II, GS videolaryngoscopy resulted in C/L views of grade 1 or 2 in 99% of the patients studied. More specifically, the 115 patients with Mallampati oropharyngeal class III views had C/L grade 1 or 2 glottic views in 91.3% and 8.7% of cases respectively (Table II). In the 27 patients with Mallampati class IV views, GS videolaryngoscopy resulted in a C/L grade 1, 2, 3 and 4 views in 21 (78%), three (11%), two (7.4%) and one (3.7%) patients respectively.

Table III compares the laryngeal view in the 133 patients in whom both DL and GS laryngoscopy were performed. Overall, DL resulted in a C/L grade 1 view in 48.9% *vs* 85.7% using G/S. More importantly, in the 35 patients in whom no glottic exposure was achieved by DL, a grade 1 or 2 view was obtained 77% of the time with the GS.

Of the 18 patients expected to be very difficult, DL was performed in ten, resulting in a C/L grade 3 view in two and a grade IV view in eight, confirming the operators' expectations. By contrast, GS videolaryngoscopy resulted in C/L grade 1, 2 and 4 views in 13, two and two of these patients respectively. In one case, the operator was unable to insert the videolaryngoscope. In these 18 patients, videolaryngoscopy was associated with easy intubations in ten patients, was awkward but successful in five patients, and unsuccessful in three patients. One unsuccessful application involved a patient who had undergone radical reconstructive surgery, including mandibulectomy, hemiglossectomy and a total of 56 oropharyngeal resections. No anatomical structures could be identified with the videolaryngoscope but the patient was successfully intubated with a fiberoptic bronchoscope (FOB).

Thirty morbidly obese patients (body mass index  $>$  40 kg·m<sup>-2</sup>) underwent videolaryngoscopy. A C/L grade 1 or 2 view was obtained in all but two and an alternative intubation technique was required in one.

### Intubation

Inability to perform tracheal intubation with the GS occurred in 26/ 722 patients (3.7%). Failure however was defined as abandonment of the technique, which occasionally occurred after a single attempt. In two cases, it was not possible to insert the videolaryngoscope. Fourteen of the 26 failed intubations (54%) occurred despite achieving a C/L 1 view. Generally, failures resulted from the inability to direct the ETT toward a clearly seen larynx. In six cases, a grade 3 or 4 view was obtained. All patients who could not be intubated by videolaryngoscopy were successfully intubated using a variety of devices according to the operator's preference. These included DL, an articulated laryngoscope, lightwand, gum elastic bougie or a flexible FOB.

The laryngeal views and success rates for tracheal intubation in specific clinical settings are summarized in Table IV.

### Discussion

When performing DL, we endeavour to create a line-of-sight between the operator's eye and the patient's larynx. A study by Adnet *et al.* concluded that in conscious volunteers with normal anatomy, neither the sniffing, simple extension nor neutral positions provided alignment of the laryngeal, pharyngeal and oral axes.<sup>9</sup> To achieve glottic visualization, soft and skeletal tissues must be distracted and compressed.<sup>8</sup> Such manipulations are not always successful. Even when they are, they likely add stress and may result in injury to soft tissues that might be avoidable with a technique not dependent upon achieving a line-of-sight. Though successful intubation by DL is often possible without visualizing the larynx, this can prolong laryngoscopy, increase the number of attempts, result in esophageal intubation or injury, arterial desaturation, hypertension and unexpected admissions to the intensive care unit.<sup>2</sup>

The current study describes the early experience with a new videolaryngoscope (GS) at five hospitals involving 133 operators and 722 consecutive uses. There was no formalized training and, in many cases, the operators had little or no prior experience with the GS. Patients were selected according to the preference of the operator and the availability of the device. Most operators familiar with DL found the transition to the GS relatively seamless. In fact, shortly after the device became available, the GS was often requested to manage patients expected to be difficult or very difficult to intubate.

Although specific data were not collected, the investigators had the impression that naïve laryngoscopists were very successful at visualizing the larynx

and intubating the trachea. This contrasts with the learning curve for conventional (Macintosh) DL among first year anesthesiology residents. Konrad *et al.* observed that such trainees required a mean of 57 attempts before achieving a 90% success rate.<sup>10</sup> Another study of novice intubators, previously exposed to extensive manikin training and attempting to intubate only patients with no suggestion of a potential difficulty, found that a 90% success rate was achieved after about ten intubations though 47 attempts were required to achieve a "good intubation" 90% of the time.<sup>11</sup> By contrast, at one of our participating institutions (VA Puget Sound HCS) 15 intubations were performed by operators with no prior GS experience. All were successful, and all but one operator achieved a C/L 1 view. At the same centre, medical students performed four of the intubations and all were achieved on the first attempt. All four students found the GS easier to use than the Macintosh laryngoscope.

GS laryngoscopy was considered a failure when the technique was abandoned, which occasionally happened after a single attempt. Most studies of DL would not have regarded this as a failure; comparisons of our failure rate with published reports of DL failure are therefore misleading. A variety of definitions are used to define difficult laryngoscopy or failed intubation: a C/L 3 or 4 view obtained using DL has an incidence of up to 8.5%;<sup>2</sup> two unanticipated, unsuccessful attempts at DL has an incidence of up to 0.9%;<sup>12</sup> "failed intubation" defined by greater or equal to three or more attempts at DL has an incidence of 1.15 to 3.8%.<sup>2</sup> A standardized intubation difficulty score<sup>13</sup> might have provided a better reflection of the degree of difficulty encountered with the GS and the need for additional maneuvers to achieve success. It would also afford a better comparison between published DL and the current GS experience. Nonetheless, the above-mentioned study limitations are likely to be relevant to other new users.

We asked the laryngoscopists to estimate the degree of difficulty they would anticipate had DL been chosen. Most operators likely formulate a subjective assessment based upon specified objective observations. We know that "objective measurements" suffer from significant inter-observer variability,<sup>14</sup> but we suspect most airway managers routinely make such assessments rather than employing complex predictive schemes. Both subjective assessments and complex scores are imperfect and result in unanticipated difficult laryngoscopies. In 16% of cases, the operators stated that they expected DL would be moderately or very difficult. These expectations were confirmed in

all the patients in whom DL was performed (10/10). We did not determine whether DL had been performed to confirm a clinical suspicion or as the first choice, which proved to be unsuccessful. Compared with other studies,<sup>15,16</sup> a significantly higher proportion of patients in our study had a modified Mallampati oropharyngeal view of III or IV. El Ganzouri *et al.* observed that 21% of such patients had C/L class 3 or 4 views while in our study, GS laryngoscopy resulted in only 2% (3/142) incidence of such views. Indeed, using the GS 88% (125/142) of these patients had a C/L grade 1 view.

While the primary purpose of laryngoscopy is to achieve tracheal intubation, in the strict sense, laryngoscopy that fails to visualize the larynx is a failed laryngoscopy whether or not intubation is successful. However, successful visualization that does not result in intubation is of limited value. Even among inexperienced users, GS laryngoscopy resulted in a higher incidence of good or excellent laryngeal views compared with DL, however, the intubation failure rate in our study was higher than most studies of DL. This may have resulted from i) insufficient familiarity with or confidence in the device; ii) lack of an agreed upon definition of failure; iii) a higher percentage of patients with difficult airways; and iv) a separate skill required to advance the tracheal tube toward and through the glottis. We attempted to collect the data resulting from each clinical use. A large number of operators had no or very limited prior experience. Since some inexperienced operators lacked confidence in the device or in their skill, they abandoned it early, rather than risk patient injury by persevering. A significant proportion of failed intubations occurred despite good or excellent glottic visualization. Indeed, 14/26 failures occurred despite a C/L grade 1 view. During the study, some operators repeatedly found intubation challenging while others experienced no such difficulty. It is possible that this results from the unfamiliar technique of manipulating the ETT while viewing the events on the monitor. It is also consistent with our observation subsequent to the study that most operators successfully acquired the skill and the problem of manipulating the ETT was virtually extinguished.

Laryngeal exposure was rarely the cause of a failed intubation, but the inability to deliver the ETT to a visualized larynx is both frustrating and largely avoidable. The GS should be inserted in the midline. It is helpful to identify the uvula and ensure that it is centered on the monitor before advancing the scope around the tongue. We recommend advancing the laryngoscope anterior to the epiglottis. Efforts to maximize glottic exposure may place the blade too

close to the glottis, demanding greater precision in placing the ETT. In addition, this tends to elevate the superior glottic structures thereby increasing the angle of incidence between the advancing ETT and the axis of the larynx. We strongly recommend the use of a malleable stylet or a device like the Parker Flex-It™ directional stylet since the ETT must be presented to the glottis, which may not be in the line of sight. The shape of the stylet can determine the success or failure of this maneuver, though many operators have successfully employed shapes other than the 60° curvature we have recommended. Insertion and advancement of the ETT may result in distortion of the malleable stylet. Placement of the ETT/stylet in the midline, beneath the phalange of the GS will minimize contact with the teeth which can distort the stylet. If the larynx is anterior to the ETT, four possible corrections can be considered: i) the curvature of the stylet can be increased; ii) external laryngeal pressure can be applied; iii) the laryngoscope blade can be slightly withdrawn which tends to reduce tilting of the laryngeal axis; or iv) very rarely, a gum elastic bougie can be introduced into the visualized trachea. If a bougie is used, the GS should be used to monitor the progress of the ETT as it is “railroaded” through the larynx. This differs significantly from intubation over a flexible fiberoptic scope wherein ETT advancement is usually not visualized.

The clinical role of the GS requires validation. This study would suggest that it could easily be incorporated into routine clinical practice. Compared with DL, GS laryngoscopy consistently affords a comparable or better glottic view, even in patients in whom DL is challenging.<sup>17</sup> Although obtaining an excellent glottic view requires minimal practice, success with intubation may improve with prior manikin experience. Early clinical experience should be acquired in patients expected to be easily intubated by DL. The GS may prove to be particularly useful in the unanticipated difficult airway as a rescue device or when airway secretions make fiberoptic intubation difficult. The CCD camera is resistant to fogging and secretions do not appear to interfere with the glottic view. In addition, bariatric surgery, obstetrical surgery and cervical spine restrictions<sup>18</sup> are specific settings where GS laryngoscopy may offer advantages over other techniques. Videolaryngoscopy is useful in the demonstration of airway anatomy or the direct supervision and monitoring of the progress of students<sup>19–22</sup> though videolaryngoscopes requiring the identical technique may be better suited for teaching DL. The role of the GS in patients known to have a difficult airway appears very promising but should be determined by experienced operators under controlled settings.<sup>17,23</sup>

## Acknowledgements

The authors would like to acknowledge the contribution of Sean Serell MD for his efforts at the Seattle site. In addition, we are grateful for the support of the Respiratory Therapist staff at the University Health Network who greatly assisted in making this study possible.

## References

- 1 Crosby ET, Cooper RM, Douglas MJ, *et al.* The unanticipated difficult airway with recommendations for management. *Can J Anaesth* 1998; 45: 757–76.
- 2 Rose DK, Cohen MM. The airway: problems and predictions in 18,500 patients. *Can J Anaesth* 1994; 41: 372–83.
- 3 Domino KB, Posner KL, Caplan RA, Cheney FW. Airway injury during anesthesia. A closed claims analysis. *Anesthesiology* 1999; 91: 1703–11.
- 4 Cooper SD, Benumof JL, Ozaki GT. Evaluation of the Bullard laryngoscope using the new intubating stylet: comparison with conventional laryngoscopy. *Anesth Analg* 1994; 79: 965–70.
- 5 Rosenblatt WH, Wagner PJ, Ovassapian A, Kain ZN. Practice patterns in managing the difficult airway by anesthesiologists in the United States. *Anesth Analg* 1998; 87: 153–7.
- 6 Jenkins K, Wong DT, Correa R. Management choices for the difficult airway by anesthesiologists in Canada. *Can J Anesth* 2002; 49: 850–6.
- 7 Samsoon GL, Young JR. Difficult tracheal intubation: a retrospective study. *Anaesthesia* 1987; 42: 487–90.
- 8 Cormack RS, Lehane J. Difficult tracheal intubation in obstetrics. *Anaesthesia* 1984; 39: 1105–11.
- 9 Adnet F, Borron SW, Dumas JL, Lapostolle F, Cupa M, Lapandry C. Study of the “sniffing position” by magnetic resonance imaging. *Anesthesiology* 2001; 94: 83–6.
- 10 Konrad C, Schupfer G, Wietlisbach M, Gerber H. Learning manual skills in anesthesiology: is there a recommended number of cases for anesthetic procedures? *Anesth Analg* 1998; 86: 635–9.
- 11 Mulcaster JT, Mills J, Hung OR, *et al.* Laryngoscopic intubation. Learning and performance. *Anesthesiology* 2003; 98: 23–7.
- 12 Combes X, Le Roux B, Suen P, *et al.* Unanticipated difficult airway in anesthetized patients. Prospective validation of a management algorithm. *Anesthesiology* 2004; 100: 1146–50.
- 13 Adnet F, Racine SX, Borron SW, *et al.* A survey of tracheal intubation difficulty in the operating room: a prospective observational study. *Acta Anaesthesiol Scand* 2001; 45: 327–32.
- 14 Karkouti K, Rose DK, Ferris LE, Wigglesworth DE, Meisami-Fard T, Lee H. Inter-observer reliability of ten tests used for predicting difficult tracheal intubation. *Can J Anaesth* 1996; 43: 554–9.
- 15 El-Ganzouri AR, McCarthy RJ, Tuman KJ, Tanck EN, Ivankovich AD. Preoperative airway assessment: predictive value of a multivariate risk index. *Anesth Analg* 1996; 82: 1197–204.
- 16 Mallampati SR, Gatt SP, Gugino LD, *et al.* A clinical sign to predict difficult tracheal intubation: a prospective study. *Can Anaesth Soc J* 1985; 32: 429–34.
- 17 Cooper RM. Use of a new videolaryngoscope (GlideScope®) in the management of a difficult airway. *Can J Anesth* 2003; 50: 611–3.
- 18 Agro F, Barzoi G, Montecchia F. Tracheal intubation using a Macintosh laryngoscope or a GlideScope® in 15 patients with cervical spine immobilization (Letter). *Br J Anaesth* 2003; 90: 705–6.
- 19 Levitan RM. A new tool for teaching and supervising direct laryngoscopy. *Acad Emerg Med* 1996; 3: 79–81.
- 20 Shulman GB, Nordin NG, Connelly NR. Teaching with a video system improves the training period but not subsequent success of tracheal intubation with the Bullard laryngoscope. *Anesthesiology* 2003; 98: 615–20.
- 21 Weiss M, Schwarz U, Dillier CM, Gerber AC. Teaching and supervising tracheal intubation in paediatric patients using videolaryngoscopy. *Paediatr Anaesth* 2001; 11: 343–8.
- 22 Kaplan MB, Ward DS, Berci G. A new videolaryngoscope—an aid in intubation and teaching. *J Clin Anesth* 2003; 14: 620–6.
- 23 Doyle DJ, Zura A, Ramachandran M. Videolaryngoscopy in the management of the difficult airway (Letter). *Can J Anesth* 2004; 51: 95.