Impacted and ankylosed teeth: Why, when, and how to intervene

Jüri Kurol
Malmö, Sweden

For patients in the deciduous dentition, early treatment often means treatment of lateral crossbites. With lateral crossbites occurring in 10% to 15% of children, one might ask: why treat these children early? One common answer is because of the risk for unilateral masticatory function and growth restriction, which might later lead to temporomandibular joint problems or facial asymmetry. However, little scientific evidence is available about future problems, especially on an individual basis.

The best age for crossbite treatment has been discussed. Some advocate maxillary expansion in the early mixed dentition. We can treat in the deciduous dentition by grinding, but the long-term effects are not well documented. In a study, the success rate of grinding to correct a crossbite was about 60%. However, in this report, spontaneous correction occurred in up to 45% of the untreated patients.[1] This means that treatment of lateral crossbite in the deciduous dentition might, in many cases, be unnecessary.

More information is needed about the long-term risks of untreated lateral crossbites, the effectiveness of different treatment methods, and whether to treat early or late. The questions of why, when, and how to intervene are important for all tooth eruption and occlusal problems in the developing dentition.

Professor emeritus, Department of Orthodontics, Malmö University, Malmö, Sweden.
Presented at the Symposium for Early Treatment, January 21-23, 2005; Las Vegas, Nev.
Reprint requests to Dr Jüri Kurol, Långevägen 24, SE-45791 Tanumshede, Sweden; e-mail, j.kurol@telia.com.
Am J Orthod Dentofacial Orthop 2006;129:S86-90
0889-5406/$32.00

doi:10.1016/j.ajodo.2005.11.008

Impacted teeth—mesiodens

Many times, a mesiodens is diagnosed when radiographs are taken at an early age because the permanent maxillary incisors have not erupted. These mesiodentes are, of course, surgically removed.

The question is, what risk do we run with mesiodentes that are not interfering with tooth eruption and development, and are left in place? The risks of enlarged follicles, cysts, and resorption of the permanent incisor roots should be considered.[2] However, in a recent study of 43 patients who were followed radiographically, no complications were found because of mesiodentes.[3] Therefore, in my opinion, early surgery is indicated only when the mesiodentes interfere with tooth eruption, occlusal development, or orthodontic tooth movement. In fact, cysts related to a mesiodens might be derived from the incisal canal (Fig 1). With time, the mesiodens seems to be stationary. During vertical growth and development in the anterior maxillary region, it might seem to move slightly apically (Fig 2).[4] However, true movement is a rare complication with a mesiodens (Fig 3). Movement is sometimes notable, but it normally has no serious consequences for the patient.

Many mesiodentes erupt spontaneously and are then extracted. Those not erupting, especially those in inverted positions, might be left and periodically radiographed for possible movement. Pathology such as resorption of permanent teeth, cysts, or follicular enlargement is extremely rare and does not warrant early removal in all young affected patients. Mesiodentes left alone might even resorb spontaneously with time.[3]

Ankylosed deciduous molars

With a permanent successor in a normal position, the expected future development of an ankylosed deciduous molar should be a 6-month delayed shedding compared with normal shedding time.[4,5] Early treatment in the form of extraction of the ankylosed deciduous molar is thus unnecessary. Instead of phase 1 or phase 2 treatment, consider "phase 0": don't do anything.

With the permanent successor missing, spontaneous

Fig 1. Mesiodens and cyst in boy, age 10 years 10 months. At surgery, cyst was found to be related to incisal canal and not to mesiodens and follicle.

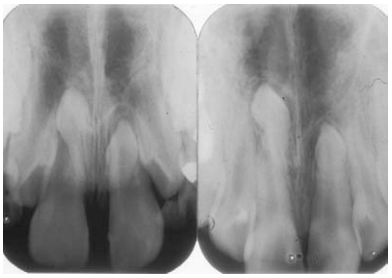

Fig 2. Mesiodentes in girl from 8 to 13 years of age. Vertical growth and development led to closure of diastema; no pathology related to mesiodens can be seen.

exfoliation is not likely. However, root resorption might continue, and an impaired vertical position might occur due to the ankylosis (Fig 4). This development might be slow after 12 or 13 years of age.[6] The problem is predicting which ankylosed molars will, with time, have good bone support, minimal infraocclusion, and good roots (Fig 5).

One recommendation is to accept the situation or, with moderate loss of height, restore occlusal height. With severe infraocclusion, extractions are recommended as early as possible to use spontaneous mesial migration of permanent molars. Thus, with early ankylosis and infraocclusion, a serious negative development can be expected, and extraction of these ankylosed deciduous molars with the successor missing must be considered.

Ankylosed permanent molars

With early ankylosis, the negative effects on occlusal development can be great (Fig 6). Extrusion of an ankylosed molar is not possible, so extraction is, unfortunately, the most common treatment.[7]

An early extraction decision is important for future restoration of the occlusion. With late ankylosis and only slight infraocclusion, the permanent molar can be left with no future periodontal problems. With ankylosed permanent second molars, the timing of extraction might depend on the developmental status of the third molar. An impaired prognosis has been found for early extraction of ankylosed second molars when the third molar crown is not completed or the third molar is tipped over 45°.[7] Luxation before orthodontic extrusion of ankylosed permanent molars often results in reankylosis and failure.

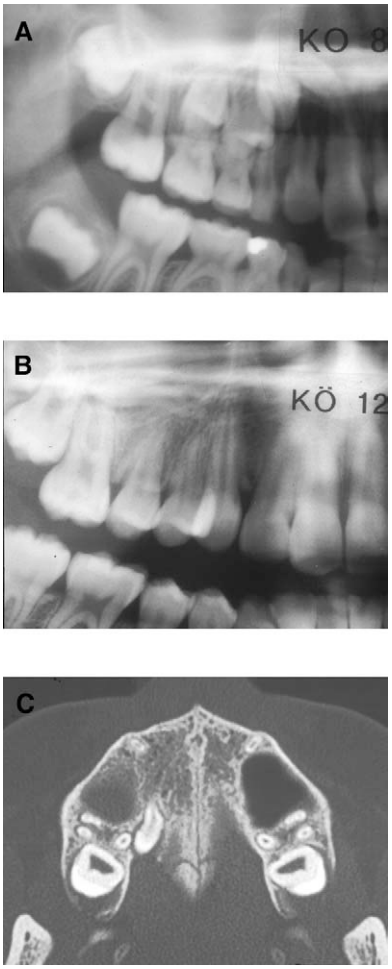

Fig 3. Mesiodens in inverted position. **A,** High and apical to lateral incisor root at age 8 years. **B,** Crown tip of conical mesiodens reaches mesial aspect of erupting permanent second molar at 12 years 8 months. **C,** CT scan close to nasal floor shows position of mesiodens, which was easily removed surgically. No pathology was found.

Impacted maxillary canines

If left undiagnosed and untreated, an ectopic maxillary canine will move farther medially, with the

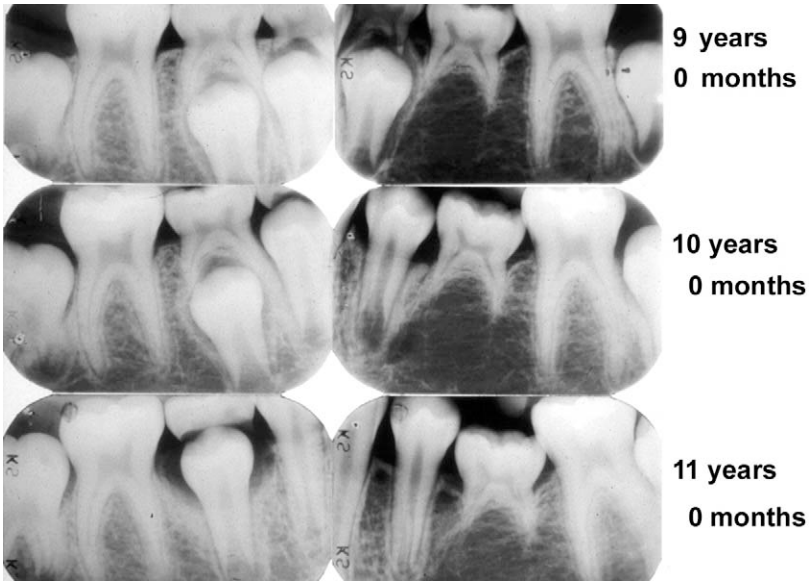

Fig 4. Root resorption in ankylosed deciduous second molars with and without permanent successor, from age 9 to 11 years.

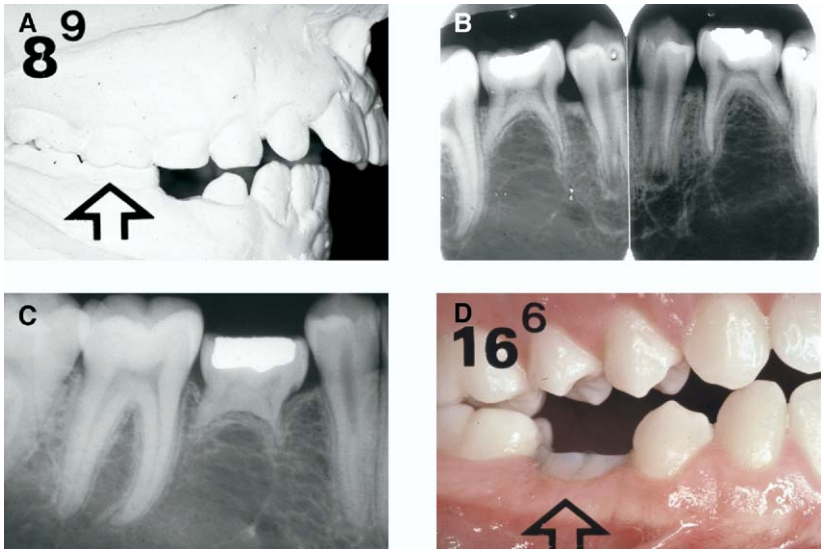

Fig 5. Development of deciduous second molar with missing permanent successor. **A,** At 8 years 9 months of age with normal occlusion; **B,** slight root resorption at 10 years 7 months; **C,** 14 years 9 months of age progressing root resorption; **D,** at 16 years 6 months, severe vertical loss of height is clinically notable.

impaired position leading to a more difficult orthodontic treatment. The risk of incisor root resorption will also increase.[8] Therefore, early diagnosis is essential.[4] Early diagnosis can be made by palpating the canine buccal area. A bulge will be palpable about 1.5 years before oral eruption (Fig 7). Most impactions are unilateral and can easily be distinguished by the palpation method, which should start at age 9 or 10 years, depending on occlusal status and somatic maturity. Other indications for a future impaction include the association with other tooth and developmental disturbances such as ectopic first molars, agenesis of premolars, ankylosis of deciduous molars, or peg-shaped lateral incisor crowns (Fig 8).[9]

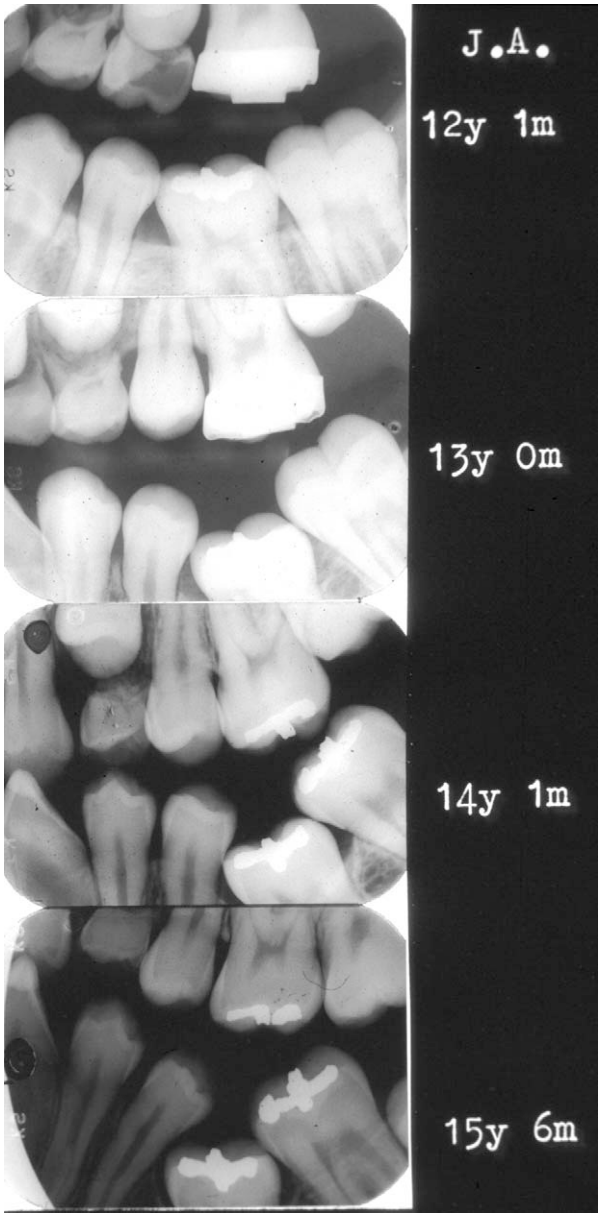

Fig 6. Ankylosis of mandibular first permanent molar and occlusal development from 12 years 1 month of age to 15 years 6 months. Note loss of space, overeruption, and tipping of neighboring teeth.

After early diagnosis, removal of the deciduous canine has been found to be effective for palatal impactions in the 10-to-13-year age group in almost 80% of patients.[10] This extraction method can be recommended as the first choice in these instances.

Orthodontists frequently encounter patients with impacted or ankylosed teeth. Treatment decisions must be based on the best prerequisites, ie, early diagnosis and knowledge of when to treat, how to treat, and, not

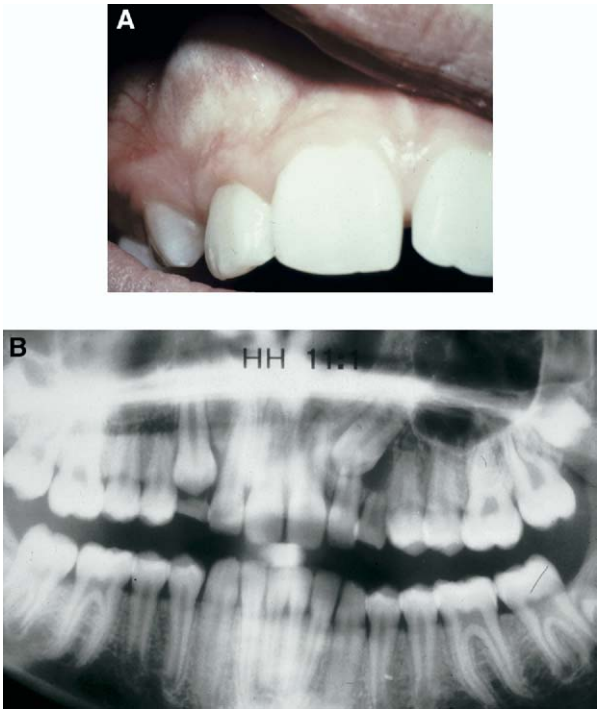

Fig 7. A, Palpable bulge in buccal sulcus about 1.5 years before oral eruption of maxillary canine. **B,** Unilateral palatal impaction of left maxillary canine at age 11 years. Contralateral canine is distinctly palpable. Diagnosis was first made clinically by asymmetry in palpation between the buccal canine areas.

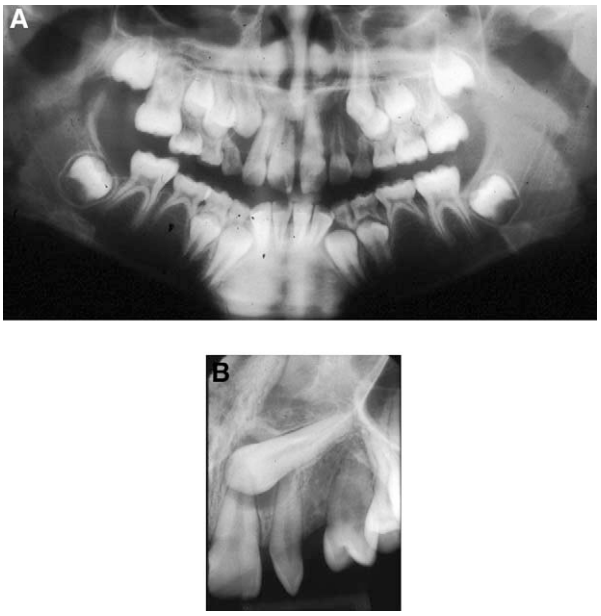

Fig 8. A, Aberrant maxillary canine eruption showing ectopic first permanent molars, infraocclusion of deciduous molars, and agenesis of premolars. **B,** Impaction of canine associated with peg-shaped lateral incisor crown.

least, why to treat. The consequences of not treating are often obvious, but they can be obscure. In some patients, treatment can be postponed—phase 0 treatment. If we recognize unsuitably or unnecessarily early treatments, a second or even third phase of treatment might be avoided.

REFERENCES

1. Kurol J, Berglund L. Longitudinal study and cost-benefit analysis of the effect of early treatment of posterior cross-bites in the primary dentition. Eur J Orthod 1992;14:173-9.
2. Andreason JO, Sewerin I. Impacted supernumerary teeth. In: Andreasen JO, Kolsen Petersen J, Laskin DM, editors. Textbook and color atlas of tooth impactions. Copenhagen: Munksgaard; 1997. p. 93-112.
3. Tyrologou S, Koch G, Kurol J. Location, complications and treatment of mesiodentes—a retrospective study in children. Swed Dent J 2005;29:1-9.
4. Kurol J. Early treatment of tooth-eruption disturbances. Am J Orthod Dentofacial Orthop 2002;121:588-91.
5. Kurol J, Koch G. The effect of extraction of infraoccluded deciduous molars: a longitudinal study. Am J Orthod 1985;87:46-58.
6. Kurol J, Thilander B. Infraocclusion of primary molars with aplasia of the permanent successor. A longitudinal study. Angle Orthod 1984;54:283-94.
7. Andreasen JO, Kurol J. The impacted first and second molar. In: Andreasen JO, Kolsen Petersen J, Laskin D, editors. Textbook and color atlas of tooth impactions. Diagnosis, treatment and prevention. Copenhagen: Munksgaard; 1997. p. 197-218.
8. Ericson S, Kurol J. Resorption of maxillary lateral incisors caused by ectopic eruption of the canines. A clinical and radiographical analysis of predisposing factors. Am J Orthod Dentofacial Orthop 1988;94:503-13.
9. Kurol J, Ericson S, Andreasen JO. The impacted maxillary canine. In: Andreasen JO, Kolsen Petersen J, Laskin D, editors. Textbook and color atlas of tooth impactions. Diagnosis, treatment and prevention. Copenhagen: Munksgaard; 1997. p. 126-65.
10. Ericson S, Kurol J. Early treatment of palatally erupting maxillary canines by extraction of primary canines. Eur J Orthod 1988;10:283-95.