

# A histological study of human wrinkle structures: comparison between sun-exposed areas of the face, with or without wrinkles, and sun-protected areas

J.L.CONTET-AUDONNEAU, C.JEANMAIRE AND G.PAULY

*Institut de Recherche en Biologie et Dermatologie, 5–7 rue de Seichamps, 54425 Pulnoy, France*

*Centre de Recherches des Laboratoires Serobiologiques SA, 3 rue de Seichamps, 54425 Pulnoy, France*

Accepted for publication 12 December 1998

## Summary

Wrinkles are a major topic in dermocosmetology; the purpose of this work has been to go deeper into the knowledge of cutaneous damage underlying these modifications of skin surface. Up to now, the number of published works about the histological structure of wrinkles is not very large. Therefore to complete the findings, we studied 46 subjects of both sexes, between 57 and 98-year-old, enabling us to obtain 157 skin biopsies of wrinkles (face) and sun-protected areas (abdomen). We used different histological techniques involving histochemistry, immunohistochemistry, electron microscopy and quantification by image analysis in addition to classic standard techniques. This study has allowed us to confirm published structural modifications of wrinkles, but also to display many other original alterations. The increased thinning of the epidermis atrophied with age is confirmed by the study of desmoplakins outlining the cellular contours of keratinocytes. Such a thinning is accompanied by a decrease in several markers of epidermal differentiation at the bottom of the wrinkles: filaggrin, keratohyalin granules and transglutaminase I, disturbing desquamation and the capacity of the horny layer to retain water. The dermoepidermal junction is modified by a decrease of collagen IV and VII, which, combined with fewer and fewer oxytalan fibres under wrinkles, weakens this interface. The deposition of abnormal elastotic tissue in the dermis, with an interruption of these deposits under wrinkles and an atrophy of dermal collagen more pronounced under wrinkles, boosts the magnitude and depth of wrinkles. The composition of the other dermal constituents is also altered with, more particularly, a marked decrease of chondroitin sulphates in the papillary dermis under wrinkles, combined with an asymmetrical variation of glycosaminoglycans on both edges of wrinkles. The atrophy of the hypodermis, also more marked under wrinkles, with a thickening of fibrous lines, also makes the depth of wrinkles more pronounced. Wrinkle formation appears at the same time as numerous modifications in different cutaneous structures, which may be mutually amplified. Such a study by pointing out altered elements in skin physiology, makes the development of specific treatments possible in order to mitigate this unwelcome cutaneous deterioration.

*Key words:* collagen IV, collagen VII, glycosaminoglycans, histological study, wrinkles

Wrinkles are folds of the skin, more frequent on the face and the hands, more numerous with age. Wrinkles are therefore an outward sign of cutaneous ageing appearing preferentially on sun-exposed areas (actinic ageing). Moreover, they can be increased by various intrinsic (hereditary, racial, hormonal, pathological) or extrinsic factors (irradiation, pollution, temperature, hygrometry).<sup>1</sup>

Wrinkles are a major topic in dermocosmetics as it is

Correspondence: G.Pauly.

fundamental to understand thoroughly the underlying cutaneous changes associated with these modifications of cutaneous relief. Previous work has described changes in the epidermis, which becomes thinner during chronological ageing. This thinning is worse at the deepest portion of the wrinkle, with or without reduction of the number of cellular layers.<sup>2,3</sup> The dermoepidermal junction (DEJ) becomes flatter during ageing; this flattening, as well as the reduction of

collagen VII, are considered to be factors in the formation of wrinkles.<sup>4–6</sup> The dermis and hypodermis become atrophied during ageing, with a reduction of collagen,<sup>2,7</sup> of certain glycosaminoglycans (GAG)<sup>8–11</sup> and of the adipose tissue of the hypodermis.<sup>2,12</sup> These reductions lead to wrinkle formation. On the other hand, elastic tissue hypertrophy produces huge amounts of elastotic material, which increases the magnitude of the wrinkles.<sup>2,7,13–15</sup>

Fibres like candelabra extend perpendicularly from the lamina densa of the DEJ into the papillary dermis where they merge with a horizontal network of elastin-containing fibres to form a continuous dermal elastic fibre network. These fibres are named oxytalan fibres.<sup>16</sup> These elastic fibres are mainly composed of elastin and two glycoproteins named fibrillin and microfibril-associated glycoprotein (MAGP). During ageing, oxytalan fibres decrease or disappear totally.<sup>13,17</sup>

In photoaged skin, the elastic tissue undergoes hyperplasia<sup>18</sup> with a marked proliferation of elastic tissue in the reticular dermis named actinic elastosis.<sup>19</sup> On the other hand, there is a severe decrease or disappearance of oxytalan fibres, forming a Grenz zone in the papillary dermis.<sup>19</sup> Severe depletion and reorganization of fibrillin at the DEJ of both mild and severely photoaged skin indicates that the fibrillin microfibrillar network of the papillary dermis is particularly susceptible to degradation by ultraviolet (UV) irradiation.<sup>20</sup> Their variations at the level of wrinkles have not been reported yet.

Lapière,<sup>1</sup> Pierard and Lapière,<sup>21</sup> and Elnekave<sup>12</sup> have also described the trabeculae in the retinacula cutis, which are broader and much shorter beneath the wrinkle; these modifications amplify the depth of wrinkles. However, there are very few comprehensive publications concerning the histological structure of wrinkles. This gave us the incentive to carry out this research.

## Materials and methods

### *Subjects*

Biopsies were obtained from the skin of elderly people recently deceased, who had donated their bodies to the departments of anatomy and pathology of the Universities of Medicine in Paris V and Nancy. The 157 biopsies came from wrinkles of the face (crow's feet, forehead, cheek, chin), from the neck and from a area usually not sun-exposed (abdomen). The biopsies of 46 people (17 men and 29 women) aged from 57 to 98 years (mean age 80 years), and without local or

infectious pathology, were investigated. For wrinkles, biopsies were taken transversely to the principal axis, including the skin of both sides.

### *Histological techniques*

We used different histological techniques involving histochemistry, immunohistochemistry (IHC), electron microscopy and quantification by image analysis, in addition to classic standard techniques. Only significant results are presented for the 10 techniques. The wrinkles were investigated by light microscopy (LM), confocal laser scanning microscopy (CLSM), scanning electron microscopy (ScEM), and transmission electron microscopy (TEM). Tissues were either frozen immediately in liquid nitrogen for immunofluorescence study, or fixed [paraformaldehyde (PF), Bouin Holland (BH) or Gendre (G)] and embedded in paraffin for light microscopy, or fixed for TEM.

### *Light microscopy*

The paraffin blocks were cut, perpendicularly to the principal axis of the wrinkle, into sections of 7 µm thickness, and then stained by various techniques: haematoxylin-eosin-saffron (PF) and Masson's trichrome (BH) were used for standard studies, picrofuchsin (BH) and Sirius red (BH) for the collagen study, Weigert (PF) and orcein (PF), with and without oxidation, for elastic network study, PAS Dimédon (G) for glycogen, blue alcian and PAS-blue alcian (PF) at different pH for GAG study.

### *Electron microscopy*

The samples of tissue were fixed in 2.5% glutaraldehyde in phosphate buffer (pH 7.5) for 2 h at room temperature. Subsequently, they were postfixated in osmium tetroxide 1% for 1 h at room temperature. The samples of tissue were dehydrated through a graded series of ethanols, then immersed in propylene oxide and embedded in Epon 512. These samples were either cut into sections of 1 µm thickness (these sections were stained by methylene-azur II blue-basic fuchsin for LM observation), or cut at 60 nm thickness, mounted on Formvar-coated copper grids and stained with uranyl acetate and lead citrate for TEM observation. A part of frozen biopsies were fixed, critically point-dried, and coated with a thin layer of gold palladium for the ScEM study. The biopsies taken from the skin of the abdomen of each person served as individual controls.

An additional control was provided by biopsies done during surgical operations of 10 young adults.

#### *Immunohistochemistry*

Primary monoclonal antibodies used in this study include antibodies (MIB1) against cellular proliferation associated antigen Ki67 (diluted 1:50), and HB8 against a small epitope expressed on elastic fibre glycoprotein (diluted 1:30, Immunotech SA, Marseille, France), and antibodies against: flaggrin (diluted 1:100), transglutaminase 1 (diluted 1:20, Clinisciences, Montrouge, France), desmoplakins I and II (diluted 1:40, Boehringer Mannheim, Mannheim, Germany), collagen VII (diluted 1:250, Serotec, Oxford, U.K.), collagen IV (diluted 1:250) and chondroitin sulphates (diluted 1:200, Sigma, St Quentin Fallavier, France). Cryostat sections of 10 µm of thickness were stained for immunofluorescence studies. In brief, frozen sections were fixed in acetone (excepted flaggrin fixed in a mixture of picric acid and paraformaldehyde) for 10 min, then air-dried, stained in a humid chamber with monoclonal antibody for 18 h at 4 °C. After being washed in phosphate-buffered saline (PBS) pH 7.2, antibodies were revealed by a specific immunoglobulin marked by fluorescein isothiocyanate diluted 1:50, applied for 30 min. Sections were washed again, counterstained with Evans blue and mounted in buffered glycerine. Negative controls for the specificity of staining consisted in replacing the primary antibody or the secondary antibody by PBS. Sections were analysed by confocal laser scanning microscopy (Zeiss, Le Pecq, France) and pictures were recorded for quantification and illustrations.

#### *Quantification of immunohistochemical preparations*

Pictures obtained with CLSM were converted to colour numeric images, in RGB, with 8 bits per channel, and 256 shades of colour. These images were analysed using mathematical morphology software (Quantimet Q570, Cambridge, Rueil-Malmaison, France).

First, the area containing the structure to be studied was delimited and measured (area A), the epidermis was manually delimited, the DEJ was manually drawn, then a similar dilatation was applied towards the epidermis and dermis to allow the full covering of the immunostaining. In the dermis, the measurement area was obtained with an even depth down in the dermis from the DEJ, using a dilatation of 40 µm for the measure of oxytalan fibres and a dilatation of 65 µm for the measure of chondroitin

sulphates. Secondly, the immunofluorescent dye (green), corresponding to the antibody studied was detected in this area A and measured as area B. Then the area fraction occupied by the structure was calculated (B/A in %). Results were expressed in percentage of reactive surface for each zone: bottom of the wrinkle, flanks of the wrinkle, sun-exposed zone adjacent to the wrinkle and control sun-protected zone (abdomen). The counting of the number of cellular living layers in the epidermis was made manually, on pictures with desmoplakin immunostaining, by two examiners.

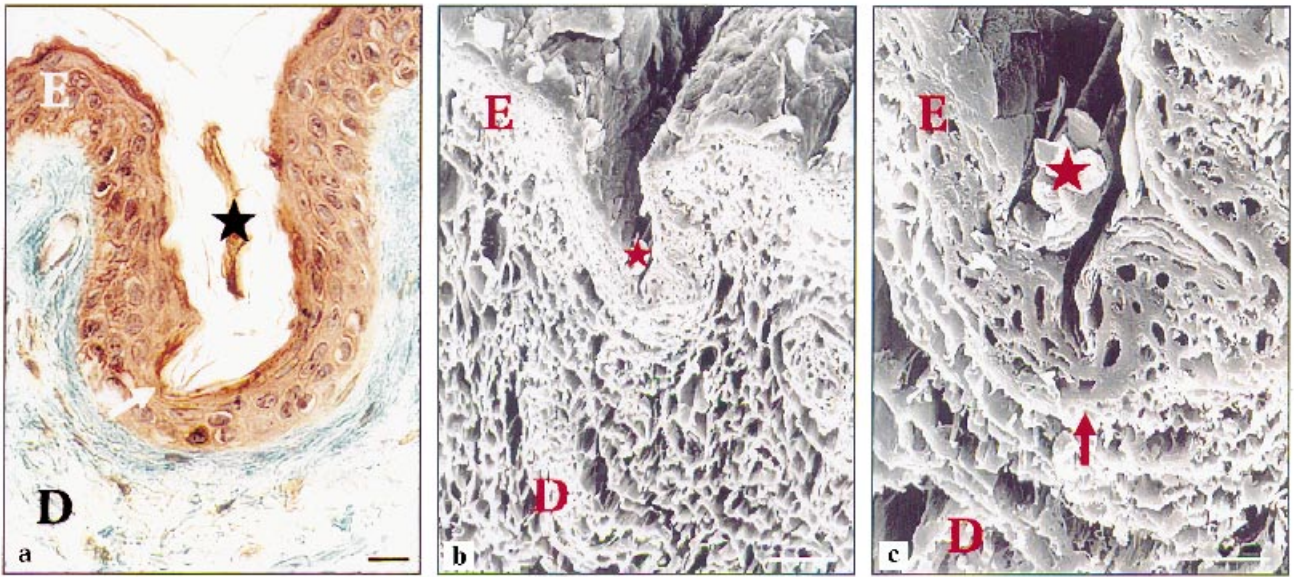
#### *Statistics*

The results represent means of percentage of reactive surface obtained from several subjects ± standard error mean (SEM). The significance of differences between wrinkles and other zones was examined with the Wilcoxon signed rank test, using the software Statview F (version 4.5). We considered  $P < 0.05$  to be significant.

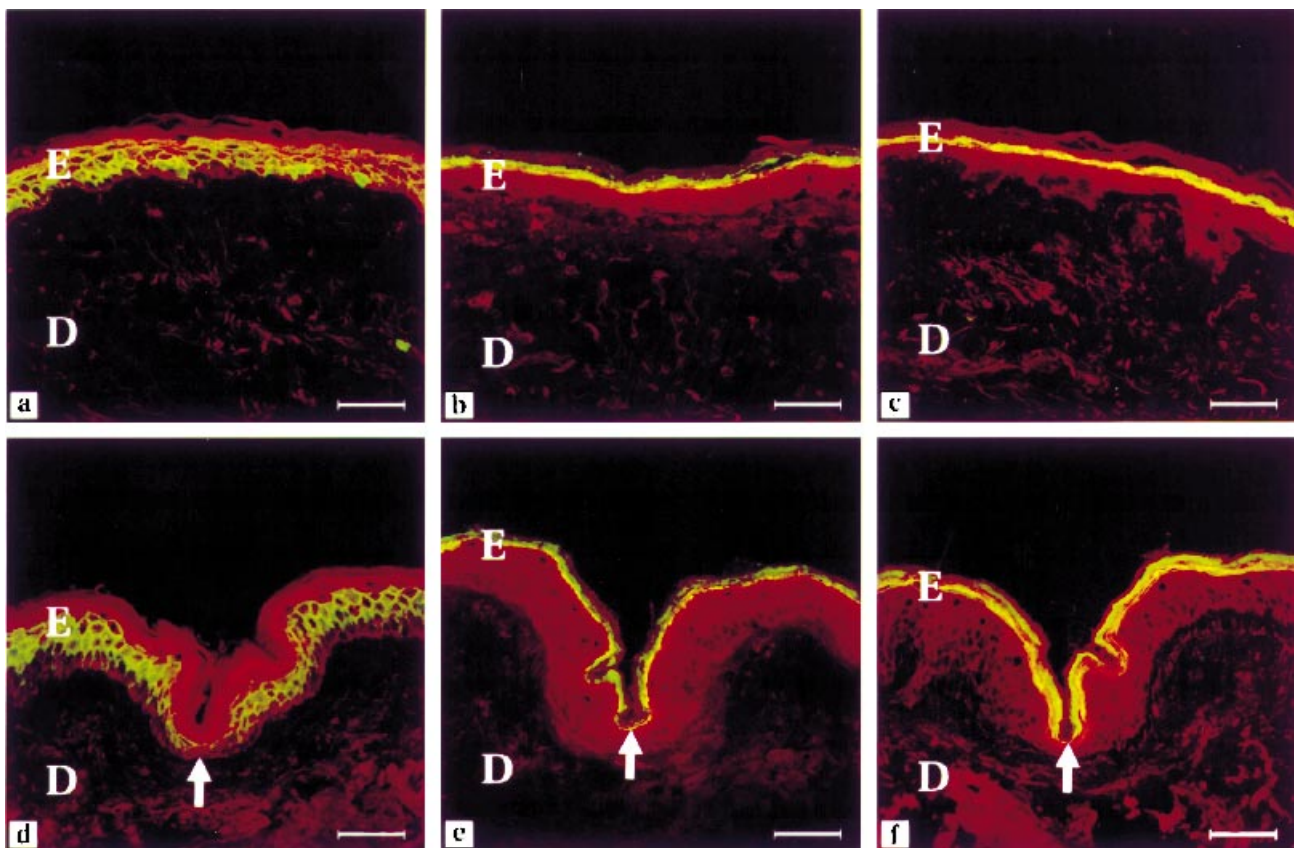
#### **Results**

The epidermis of aged skin is thinned. The thickness of human skin and epidermis are variable, depending on the body localization. We have confirmed the marked atrophy of abdomen skin and epidermis in relation with ageing (data not published). On the other hand, the estimation of this atrophy was more difficult on the face, because of the marked variations in thickness between the studied zones: forehead, crow's feet, cheek, chin. However, on each wrinkle biopsy, we have observed that the thickness of epidermis stratum spinosum is generally thinner at the bottom of the wrinkle than on the wrinkles' flanks (Fig. 1a). The desmoplakins detection (entering into desmosomes composition) enabled us to visualize distinctly the cellular contours of keratinocytes and to prove that the reduction of epidermis thickness corresponds to reduction of the number of cellular layers (Fig. 2d).

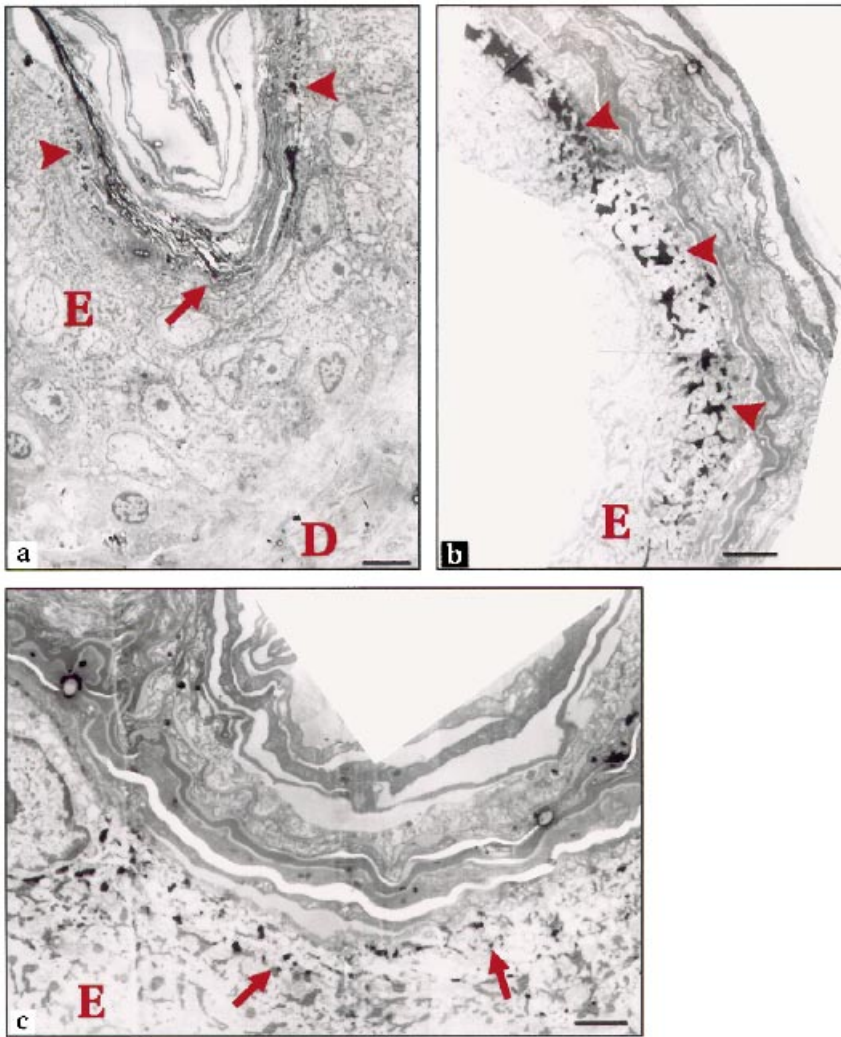
On the other hand, the stratum corneum of the wrinkle is often thickened by an accumulation of corneocytes forming a real horny plug (Fig. 1a), well characterized by ScEM (Fig. 1b,c). This disruption of desquamation has been confirmed by variations of several elements marking the cellular differentiation of stratum granulosum: keratohyalin granules are more abundant on the flanks of the wrinkle and less numerous at the bottom of the same wrinkle (Fig. 3a–c). Filaggrin and transglutaminase I displayed by IHC were significantly decreased at the bottom compared with the



**Figure 1.** (a) Thinning of the epidermis more pronounced at the bottom of the wrinkle (arrow) and presence of a horny plug (star); scale bar = 20  $\mu\text{m}$ . (b,c) Wrinkle with horny plug (star) observed with SEM. Scale bar: b = 200  $\mu\text{m}$ , c = 50  $\mu\text{m}$ . E = epidermis, D = dermis.



**Figure 2.** Epidermis. Comparison of immunolabelling (green) of desmoplakins (a,d), filaggrin (b,e) and transglutaminase (c,f) between non-sun-exposed skin (abdomen a–c) and wrinkle (d–f). The epidermis is thinned at the bottom of the wrinkle (d) (arrow). Filaggrin and transglutaminase are distinctly reduced at the bottom of the wrinkle (e,f) (arrow) in comparison with abdomen skin. (a–c) Scale bar = 50  $\mu\text{m}$ .



**Figure 3.** Keratohyalin granules in transmission electron microscopy. On the one hand, keratohyalin granules are reduced at the bottom of the wrinkle (a,c, arrow) and on the other hand, they are increased at flanks of the wrinkle (a,b, arrowhead). Scale bar: a = 5  $\mu$ m, b and c = 2  $\mu$ m. E = epidermis, D = dermis.

flanks of the wrinkle and with control zones (Fig. 2b,c,e,f). On the other hand, cellular activity, evaluated by Ki 67, was not significantly modified.

The DEJ flattens and becomes linear during ageing. This is due to a disappearance of dermal papillae and epidermal buds. At the bottom of the wrinkle, the DEJ shows modifications of collagens IV and VII that decreased distinctly and significantly in relation to the flanks and to control zones (Fig. 4a,b,d,e).

In the dermis, we have found some modifications due to ageing (collagen atrophy, which is more marked under the wrinkle) as well as changes of the elastic tissue, which was strongly modified in zones exposed to actinic radiation with the formation of voluminous masses of elastotic tissue. This elastotic tissue forms real pads on each side of the wrinkle and is interrupted at the bottom of the wrinkle.

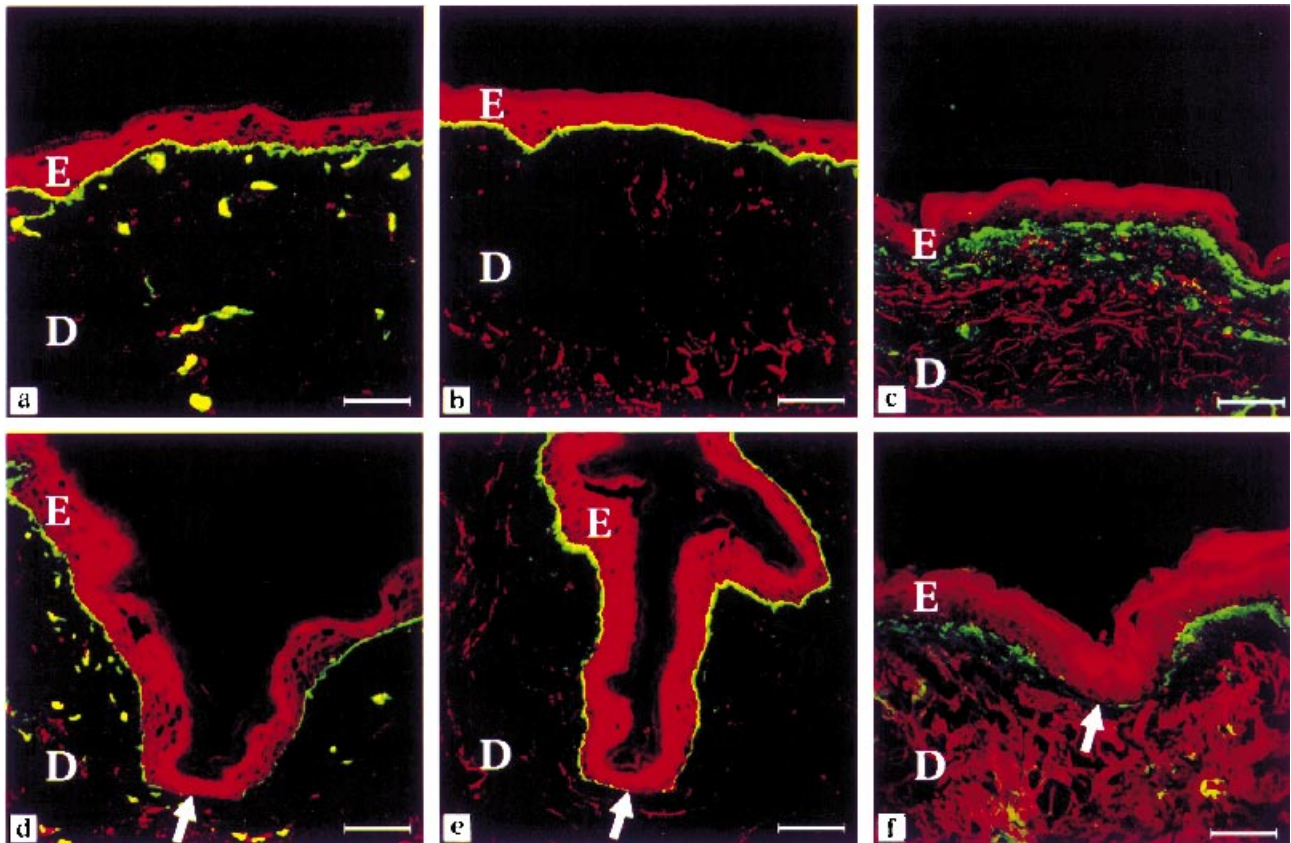
The oxytalan fibres were already decreased under

sun-exposed epidermis in comparison with non-sun-exposed skin (abdomen). They were even more sparse under the bottom of the wrinkle, with a trend to early disappearance due to age (Fig. 5a–c). This reduction was statistically significant.

The GAG chondroitin sulphates were modified with age and solar irradiation. Moreover, chondroitin sulphates were strongly decreased under the bottom of the wrinkle with asymmetric variations of both wrinkle flanks, in comparison with control zones (Fig. 4c,f). We have also confirmed the atrophy of the hypodermis with fibrous trabeculae thickening, more pronounced under the wrinkle. The results are summarized in Figure 6.

## Discussion

This study reveals new details about the structure of the permanent wrinkles in the ageing process.<sup>2,7,13–15</sup> Both

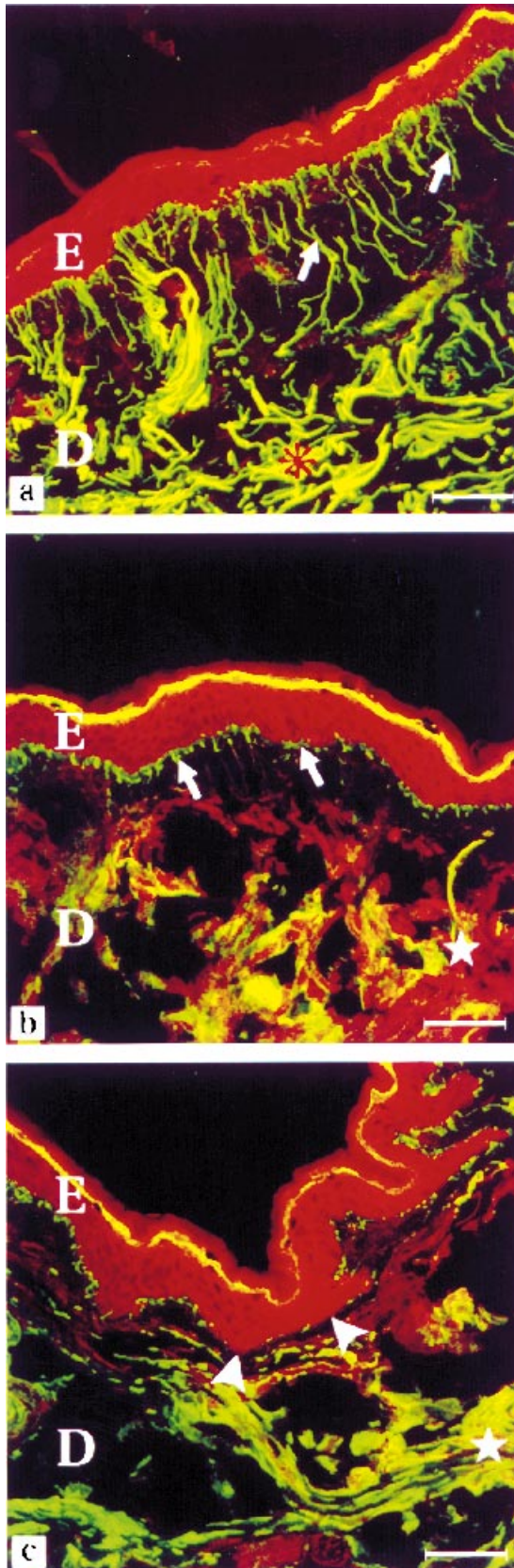


**Figure 4.** Dermal–epidermal junction and dermis. Comparison of immunolabelling (green) of collagen IV (a,d), collagen VII (b,e) and chondroitin sulphates (c,f) between non-sun-exposed skin (abdomen = a–c) and wrinkle (d–f). A marked reduction of labelling at the bottom of the wrinkle (arrow, d–f) in comparison with the skin of the abdomen (a–c) has been observed; for the last wrinkle (f), which is around the mouth, the epidermis is thicker, but the diminution of chondroitin sulphates at the bottom of the wrinkle is more important in this location. Scale bar = 50  $\mu$ m. E = epidermis, D = dermis.

ageing and actinic irradiation induce an atrophy of all cutaneous structures, with the exception of dermal elastic tissue, which presents an important elastotic hypertrophy. At the level of the wrinkle, all these changes are even more pronounced, except solar elastosis which either decreases or disappears under the wrinkle.<sup>14</sup> In the epidermis, desmoplakins are proteins entering the composition of desmosomes. Detected by IHC, they allow us to visualize the contours of keratinocytes and so to demonstrate a reduction in the number of cellular layers. This shows an atrophy of the living layers of epidermis.<sup>2,3</sup> Wright and Shellow<sup>15</sup> only talked about a simple compression of the epidermis, without reduction of the number of cellular layers.

On the other hand, the accumulation of horny cells in some wrinkles indicates a disturbance in differentiation or in the desquamation process. These modifications were identified by the IHC study of profilaggrin/filaggrin. Filaggrin aggregates filaments of keratin, generates

through its degradation a pool of natural moisturising factors, which are indispensable for the preservation of epidermis structure and functions, and takes part in the composition of horny envelopes.<sup>22–24</sup> Studies by Tezuka *et al.*<sup>25</sup> reported the absence of variation of the filaggrin in the skin of face, between young and aged subjects. In the same subject, we have not observed any variation of filaggrin between non-sun-exposed skin of the abdomen and sun-exposed non-wrinkled skin of face. On the other hand, filaggrin is strongly and significantly reduced under the wrinkle, in the same way as are keratohyalin granules. These are clearly visible by electron microscopy thanks to their opacity to electrons. They constitute storage organs of whole presynthesized structural proteins which are necessary during cornification. The main components of keratohyalin granules are filaggrin and loricrin.<sup>26</sup> Moreover, transglutaminase I, responsible for the ‘fragile-type’ horny envelope, is also reduced under the wrinkle.<sup>27–29</sup>

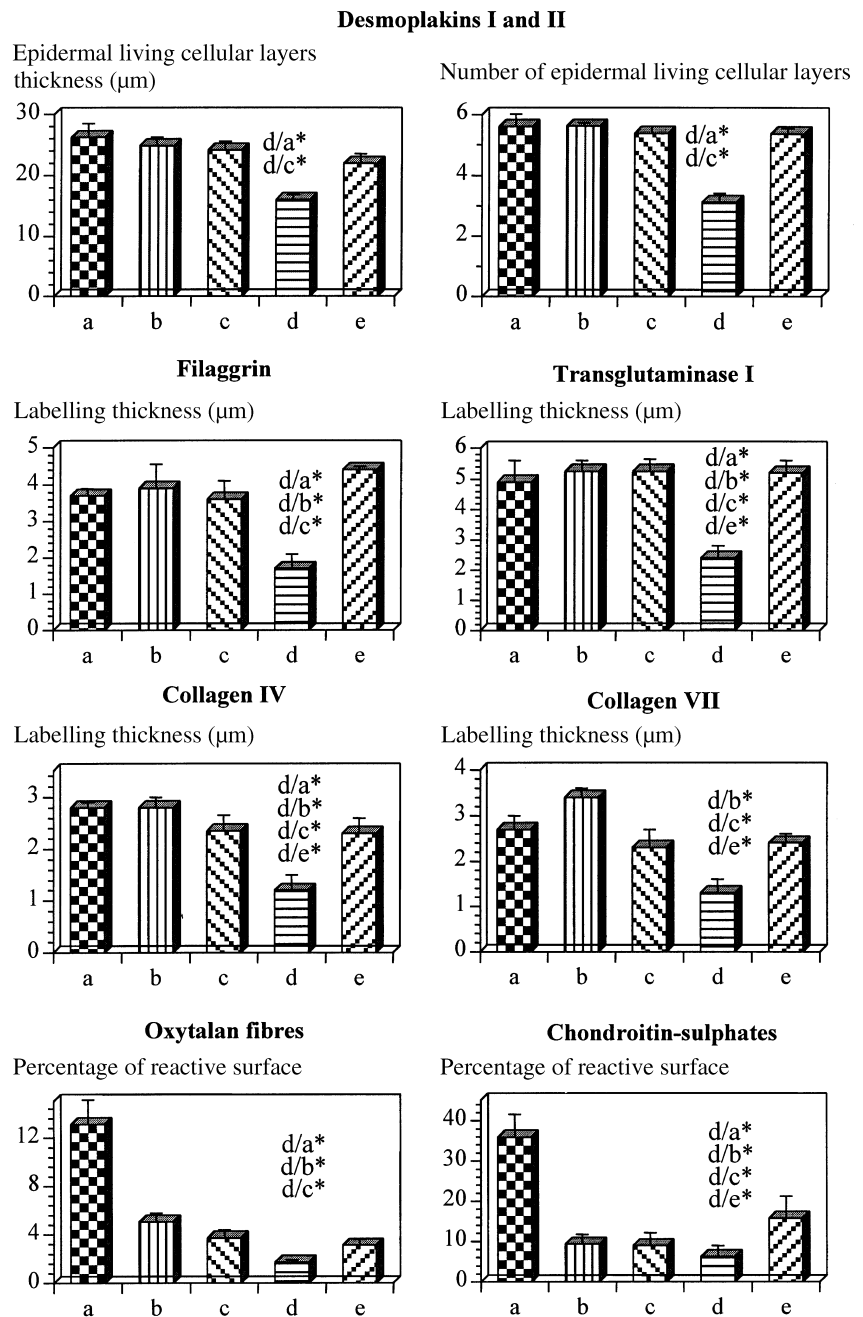


These modifications in the epidermal differentiation markers substantiate disruption of keratinization and desquamation at the level of the bottom of wrinkle, as well as reduction of water retention by the horny layers.

Collagen IV is an important component of the DEJ. The mesh-net formed by its polymerization will be used as a framework for other molecules of the DEJ.<sup>30</sup> In our study we have found no difference in the distribution and the intensity of the collagen IV between the sun-protected skin (abdomen) and the sun-exposed non-wrinkled zones. These results are consistent with a recent investigation of Boorsma *et al.*<sup>31</sup> They examined the distribution of collagen IV in photoaged vs. photo-protected skin using IHC and confocal microscopy. They found no significant alteration in the pattern of collagen IV type deposition in photoaged skin. On the other hand, we observed significant diminution of collagen IV at the bottom of the wrinkles. The collagen IV forms a network, highly cross-linked and is considered to maintain mechanical stability.<sup>30</sup> The diminution of collagen IV weakens this epidermal–dermal interface and can break the mechanical stability.

Collagen VII is the principal constituent of the anchoring fibrils, attachment structures that play a major part in stabilizing the association of basement membrane zone to the underlying papillary dermis.<sup>32,33</sup> Previous studies have shown that UV irradiation could modify the expression of collagen VII. Chen *et al.*<sup>33</sup> demonstrated a UVA-induced enhancement of type VII collagen gene expression correlated with an increase in its proteins secreted into the conditioned medium in human cultured fibroblasts. In contrast, they have found a slight decrease in type VII collagen mRNA level in UVA-irradiated human cultured keratinocytes.<sup>33</sup> Investigation of collagen VII expression in biopsies of photodamaged forearm skin, sun-protected hip and upper inner arm skin from the same subject have also shown variations. In photodamaged skin, the number of anchoring fibrils was significantly lower and

**Figure 5.** Oxytalan fibres. Comparison of elastic fibres aspect and distribution revealed by immunohistochemistry (green) between non-sun-exposed skin (abdomen, a), sun-exposed non-wrinkled skin of face (b), and sun-exposed wrinkled skin of face (c). A distinct diminution of oxytalan fibres (arrow) in sun-exposed skin (b,c) in comparison with the non-sun-exposed skin of the abdomen (a) has been observed. Fibres have nearly disappeared under the wrinkle (c, arrowhead). The reticular fibres (asterisk) are distributed along the dermoepidermal junction in the sun-protected zone (a). In the sun-exposed skin (b,c) elastotic tissue formation was noted (star). Scale bar = 50  $\mu\text{m}$ . E = epidermis, D = dermis.



**Figure 6.** Quantification of different markers of abdomen skin (non-sun-exposed skin, a), sun-exposed non-wrinkled skin of face (b), and sun-exposed wrinkled skin of the face (c–e). At the level of the wrinkle, the bottom of the wrinkle (d) and the two flanks of the wrinkle (c and e) were studied. Data are mean ± SEM (five to eight subjects per marker). Significance level was  $P < 0.05$  (\*), using the Wilcoxon signed rank test. For all these markers, we showed a strong decrease, generally significant, at the bottom of the wrinkle.

keratinocyte expression of collagen VII mRNA was significantly reduced, as compared with sun-protected areas (hip and inner arm). However, they have found a non-significant reduction of immunohistochemical staining for collagen VII in photodamaged skin as compared with sun-protected skin.<sup>5</sup> We demonstrated a diminution of immunohistochemical staining for collagen VII in sun-wrinkled skin by comparison with sun-exposed non-wrinkled or non-sun-exposed skins. This diminution was amplified at the bottom of the

wrinkle. It has not been investigated whether the diminution could result from a collagen VII decrease in synthesis and/or an increased breakdown (by metalloproteinase). The diminution of collagen VII by weakening the bond between epidermis and dermis could contribute to the formation of the wrinkle.<sup>5</sup>

Chondroitin sulphates are important GAGs in dermal function. They consolidate collagen fibres and participate in cutaneous hydration. Chondroitin sulphates are decreased during ageing.<sup>10</sup> This reduction is amplified



by actinic irradiation. Under the wrinkle, the reduction of chondroitin sulphates is even more pronounced, which accentuates disruption at this level. The asymmetric variations on the two flanks of the wrinkle may be explained by a difference of exposure to actinic irradiation.

The dermal elastic network has been visualized thanks to an antibody which labels an elastic fibre glycoprotein.<sup>34</sup> In young skin controls, papillary dermis fibres are very thin and perpendicular to the DEJ. They correspond to oxytalan fibres. At the junction between papillary and reticular dermis, eulanine fibres form a horizontal plexus. In deep skin, they are sustained by mature elastic fibres of the reticular dermis. Those fibres are more voluminous and distributed parallel to the DEJ. Reduction of oxytalan fibres has been observed during chronological ageing.<sup>2</sup> This diminution has been even amplified by actinic exposure. Under the wrinkle, the oxytalan fibres are either more sparse or have disappeared.

Moreover, we have confirmed variation of elastotic tissue (hypertrophied on flanks of the wrinkle and rarefied or absent under the wrinkle),<sup>14</sup> as well as atrophy of the dermal collagen and the hypodermis<sup>2,12</sup> under the wrinkle with fibrous trabeculae thickening,<sup>1,12,21</sup> which again increases the magnitude of wrinkles.

In conclusion, our results confirm that wrinkle formation appears at the same time as numerous modifications in different cutaneous structures, which may be mutually amplified. Pointing out the disturbed elements, in relation to wrinkle formation, this study will probably help to find specific treatments to fight these undesired modifications.

## References

- Lapière CM. Vieillesse de la peau et tissu conjonctif. In: *Symp Soc Cosm Sci: Skin Ageing Causes and Prevention*. Blois, France: Pralon graphic 93250, 1990: 157–70.
- Aubinière E. Rides et élastose. *Rev Prat* 1985; **35**: 1160–8.
- Volarelli FF. Sulla Istologicae, Sulla Patogenesi della Rughe. In: *Cowdry's Problems of Aging* (Chieffi M, ed.), 3rd edn. Baltimore: Williams and Wilkins Co., 1952: 909–23.
- Escande JP, Arnaud Battandier J. Une approche quantitative nouvelle du vieillissement cutané. *Ann Med Int* 1985; **136**: 287–9.
- Craven NM, Watson REB, Jones C *et al.* Collagen VII in photoaged skin. *J Invest Dermatol* 1995; **105**: 488 (Abstr.).
- Craven NM, Watson REB, Jones CJP *et al.* Clinical features of photodamaged human skin are associated with a reduction in collagen VII. *Br J Dermatol* 1997; **137**: 344–50.
- Warren R, Kligman AM, Montagna W *et al.* Age, sunlight, and facial skin: a histologic and quantitative study. *J Am Acad Dermatol* 1991; **25**: 751–60.
- Fleischmajer R, Perlish JS, Bashey RI *et al.* Human dermal glycosaminoglycans and aging. *Biochem Biophys Acta* 1972; **279**: 265–75.
- Smith JG, Davidson EA, Tindall JP, Sams WM. Alterations in human dermal connective tissue with age and chronic sun damage. *J Invest Dermatol* 1962; **39**: 347–50.
- Smith FG, Davidson EA, Taylor RW. Human cutaneous acid mucopolysaccharides. the effects of age, and chronic sun damage. In *Advances in Biology of the Skin* (Montagna W, ed.), Vol. VI Aging. New York: Pergamon Press, 1965: 211–18.
- Willen MD, Sorrell IM, Lekan CC *et al.* Patterns of glycosaminoglycan/proteoglycan immunostaining in human skin during aging. *J Invest Dermatol* 1991; **96**: 968–74.
- Elnekave FL. Origine et formation des rides. *Bull Esth Derm Cosmetol* 1989; **53**: 13–8.
- Bouissou H, Pieraggi MT, Julian M. Les aspects anatomophysiologiques du vieillissement. *Bull Esth Derm Cosmetol* 1987; **32**: 13–20.
- Tsuji T, Yorifuji T, Hayashi Y, Hamada T. Light and scanning electron microscopic studies on wrinkles in aged persons' skin. *Br J Dermatol* 1986; **114**: 329–35.
- Wright ET, Shellow WVR. The histopathology of wrinkles. *J Soc Cosm Chem* 1965; **24**: 81–5.
- Cotta-Pereira G, Guerro-Rodriguez F, Bittencourt-Sampaio S. Oxytalan, elaunin and the elastic fibers in the human skin. *J Invest Dermatol* 1978; **66**: 143–8.
- Kligman AM, Zheng P, Lavker RM. The anatomy and pathogenesis of wrinkles. *Br J Dermatol* 1985; **113**: 37–42.
- Kligman AM. Early destructive effect of sunlight on human skin. *JAMA* 1969; **210**: 2377–80.
- Braverman IM, Fonferko E. Studies in cutaneous aging: I. The elastic fiber network. *J Invest Dermatol* 1982; **78**: 434–43.
- Watson REB, Craven NM, Shuttleworth CA *et al.* Fibrillin in photoaged skin. *Br J Dermatol* 1996; **134**: 573 (Abstr.).
- Pierard GE, Lapière CM. The microanatomical basis of facial lines. *Arch Dermatol* 1989; **125**: 1090–2.
- Simon M. The epidermal cornified envelope and its precursors. In: *Keratinocyte Handbook* (Leigh IM, Lane EB, Watt FM, eds). Cambridge: Cambridge University Press, 1994: 275–92.
- Michel S, Reichert U. L'enveloppe cornée: une structure caractéristique des cornéocytes. *Rev Eur Dermatol MST* 1992; **4**: 9–17.
- Takahashi M, Tezuka T, Kakegawa H, Katunuma N. Linkage between phosphorylated cystatin alpha and filaggrin by epidermal transglutaminase as a model of cornified envelope and inhibition of cathepsin L activity by cornified envelope and the conjugated cystatin alpha. *FEBS Lett* 1994; **340**: 173–6.
- Tezuka T, Qing J, Saheki M *et al.* Terminal differentiation of facial epidermis of the aged: immunohistochemical studies. *Dermatology* 1994; **188**: 21–4.
- Dale BA, Resing KA, Presland RB. Keratohyalin granule proteins. In: *Keratinocyte Handbook* (Leigh IM, Lane EB, Watt FM, eds). Cambridge: Cambridge University Press, 1994: 323–50.
- Schroeder WT, Thacher SM, Stewart Galetka S *et al.* Type I keratinocyte transglutaminase: expression in human skin and psoriasis. *J Invest Dermatol* 1992; **99**: 27–34.
- Rice RH, Mehrpouyan M, Qin Qin Phillips MA. Transglutaminases in keratinocytes. In: *Keratinocyte Handbook* (Leigh IM, Lane EB, Watt FM, eds). Cambridge: Cambridge University Press, 1994: 259–74.
- Kim SY, Chung SI, Yoneda K, Steinert PM. Expression of transglutaminase 1 in human epidermis. *J Invest Dermatol* 1995; **104**: 211–17.
- Timpl R. Macromolecular organization of basement membranes. *Curr Opin Cell Biol* 1996; **8**: 618–24.

- 31 Boorsma J, Watson REB, Craven NM *et al.* Collagen IV in photo-aged skin. *J Invest Dermatol* 1996; **107**: 516 (Abstr.).
- 32 Sakai LY, Keene DR, Morris NP, Burgerson RE. Type VII collagen is a major structural component of anchoring fibrils. *J Cell Biol* 1986; **103**: 1577–86.
- 33 Chen M, Peterson MJ, Li H-L *et al.* Ultraviolet A irradiation upregulates type VII collagen expression in human dermal fibroblasts. *J Invest Dermatol* 1997; **108**: 125–8.
- 34 Schmitt D, Chignol MC, Brochier J, Thivolet J. HB8: a monoclonal antibody recognizing elastic fibre microfibrils. *Br J Dermatol* 1986; **114**: 661–5.