

**Select<sup>®</sup> Shoulder IG System**  
Surgical Procedure Education Manual



# Select Shoulder IG System

## Table of Contents

<b>1) Introduction .....</b>	<b>2</b>
• Acknowledgements .....	2
• Design Rationale .....	2
• Indications and Contraindications .....	2
• Preoperative Planning .....	3
• Patient Positioning, Prepping, Draping .....	4
<b>2) Exposure of the Joint .....</b>	<b>5</b>
• Examination Under Anesthesia .....	5
• Skin Incision and Superficial Dissection .....	5
• Deep Dissection .....	6
• Methods of Subscapularis Z-plasty .....	8
• Method I (Rockwood) .....	8
• Method II (Neer) .....	9
<b>3) Humeral Preparation .....</b>	<b>10</b>
• Humeral Osteotomy .....	10
• Initial Osteotomy I: Conventional .....	11
• Initial Osteotomy II: Extramedullary Osteotomy Guide .....	12
• Humeral Shaft Preparation .....	13
• Proximal Humeral Shaft Preparation and Final Osteotomy .....	14
• Preliminary Humeral Head Broach Trialing .....	16
<b>4) Glenoid Preparation .....</b>	<b>18</b>
• Glenoid Preparation and Selection .....	19
• Pegged Glenoid Preparation .....	19
• Keeler Glenoid Preparation .....	24
<b>5) Final Implantation .....</b>	<b>29</b>
• Humeral Shaft Cement Technique .....	29
• Joint Reduction and Subscapularis Tendon Attachment .....	32
• Revision: Removal of the Implant .....	32
• Head Style Selection .....	33
<b>6) Four-Part Fracture Management .....</b>	<b>34</b>
• Patient Positioning .....	35
• Surgical Technique .....	35
<b>7) Post-Operative Rehabilitation .....</b>	<b>40</b>
• Patient Rehabilitation for Total Shoulder Arthroplasty .....	40
• Patient Rehabilitation for Four-Part Fractures .....	41

Note: The technique description herein is made available to the health care professional to illustrate the author's suggested treatment for the uncomplicated procedure. In the final analysis, the preferred treatment is that which addresses the needs of the specific patient.

## Acknowledgments

Orthopedic surgeons worldwide owe a tremendous debt to Charles S. Neer II, MD, for his untiring work in shoulder surgery.

Dr. Neer's principles of shoulder arthroplasty and soft tissue reconstruction are critical to successful shoulder replacement. These principles are anatomic shape, minimal bone removal, avoidance of mechanical impingement, release of contracture, and repair and rehabilitation of the soft tissues. It is my opinion that this modular design prosthesis facilitates the achievement of these goals.

Many others have worked in this area in both clinical and basic research. Drs. Cofield, Wallace, Friedman, Kessel, Matsen, Harryman, Sidles, Craig, Post, and Bayley, to name a few; have contributed to my understanding of shoulder replacement.

I owe a personal debt to my teacher, Charles A. Rockwood, Jr., MD, for sharing his knowledge, patients and surgical skills with me, and to Dickie Jones, MD.

This new design would not have been possible without Drs. John Itamura, George Blatter, Steve Burkhart, Dan Buss, Kevin Speer, Jim Bradley, James Shankwiler, Jeffery Cantrell, Michael Ciepiela, Michel Arcand and Craig Zeman.

## Design Rationale

The **Select Shoulder IG System** has been designed to address the unique anatomy of the glenohumeral joint to help increase postoperative motion and function in total shoulder arthroplasty, hemiarthroplasty and complex fracture management.

The instrumentation offers several surgical options for humeral preparation and glenoid resurfacing depending upon each surgeon's preference and individual patients' needs. Most importantly, the instrumentation assists in providing predictable, reproducible results.

Since the shoulder must truly maintain a balance between mobility and stability, meticulous attention must be paid to the implant surgical technique, soft-tissue balancing, and repair and rehabilitation. A rehabilitation program should be modified or individualized depending upon the disease process or intraoperative findings. Successful shoulder arthroplasty can be accomplished by paying careful attention to patient selection, patient preparation, intraoperative surgical technique and postoperative rehabilitation.

The following is a general guide to performing total shoulder arthroplasty and should be individualized on a case-by-case basis.

## Indications and Contraindications

**The main indication for prosthetic replacement of the shoulder is pain** emanating from an incongruous glenohumeral joint that is unresponsive to other forms of conservative treatment. Decreased range of motion and tissue insufficiency are less common indications for such surgery.

**Hemiarthroplasty** (Humeral Head Replacement - HHR) is indicated in the following conditions:

- Primary osteoarthritis with a concentric glenoid.
- Osteonecrosis without glenoid involvement.
- Rheumatoid arthritis where glenoid bone stock and rotator cuff deficiency are the rule.
- Four-part fractures and head splitting fractures.
- Surgical neck non-unions in elderly patients.
- Tumor resection.
- Rotator cuff tear arthropathy.
- Chronic dislocations where the impression fracture is greater than 40% of the articular surface.

**Total shoulder arthroplasty** (TSA) is indicated in the following conditions:

- Primary osteoarthritis with destruction of both humeral head and glenoid.
- Osteonecrosis with glenoid involvement.
- Rheumatoid arthritis with rotator cuff integrity.
- Posttraumatic arthritis.
- Rotator cuff tear arthropathy in which a tensionless cuff repair can be obtained with a glenoid component in place.
- Post dislocation or reconstruction arthropathy.
- Failed prosthetic replacement, humeral head resection or arthrodesis.

**Contraindications** to shoulder replacement include:

- Patients in which the symptoms and/or disease process is not severe enough to warrant arthroplasty.
- Patients with active or recent infection.
- Extensive paralysis with complete loss of deltoid and rotator cuff function.
- A charcot joint.
- A patient unwilling or unable to cooperate with a rehabilitation program necessary for proper functioning of the shoulder replacement.

## Preoperative Planning

The patient's shoulder is carefully evaluated radiographically using the following views:

- Anterior/Posterior (A/P) view in internal rotation.
- A/P view in external rotation.
- Axillary lateral view.
- CT Scan to assess the position of the tuberosities, version and the degree and location of glenoid wear.

### The A/P views should be utilized to analyze:

- Osteophyte formation on the humeral head
- Superior head migration
- Acromioclavicular joint status
- Subacromial spur formation
- Humeral shaft deformities
- Thickness and size of the intramedullary humeral canal
- Tuberosity positioning (post-traumatic arthritis)

The **Select Shoulder IG System** offers humeral stem and humeral head X-ray templates at 10 percent magnification to assist in determining prosthetic size and placement.

To properly determine prosthetic size, the axis of the humeral stem should be centered in the humeral canal to achieve correct placement of the stem template on the A/P view of the involved humerus (Figure 1).

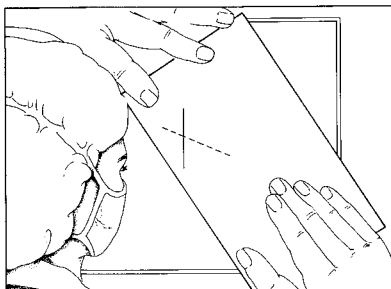


Figure 1

Once the axis of the humeral stem template is correctly positioned on the A/P view, the humeral head template is placed over the stem template, with the dots aligned to indicate appropriate humeral head fit. The humeral head template should align itself against the articulating border of the humeral head X-ray. If severe deformity is present and the patient has unilateral disease, the non-involved humerus should be used for templating.

The humeral stem template is placed over the intramedullary canal of the humerus to determine the size of the stem implant which will provide the patient with maximum proximal and distal cortical fill.

The axillary lateral radiographic views should be utilized to analyze:

- Extent and orientation of glenoid wear.
- Amount of medial migration and bone loss.
- Position of the humeral head relative to the glenoid.
- Amount of anterior or posterior subluxation of the humerus and the position of the tuberosities.

**In the osteoarthritic patient, careful note of posterior glenoid erosion must be made.** If marked posterior erosion is present, alternatives include bone grafting posteriorly versus removing bone selectively from the anterior surface.

### CT Scanning

A CT scan is often extremely helpful in assessing the position of the tuberosities and the amount, extent, and location of glenoid wear. A CT scan also helps one determine preoperatively the patient's retroversion based on the bicipital distance and any alterations of this version which need to be made at the time of surgery (Figure 2).

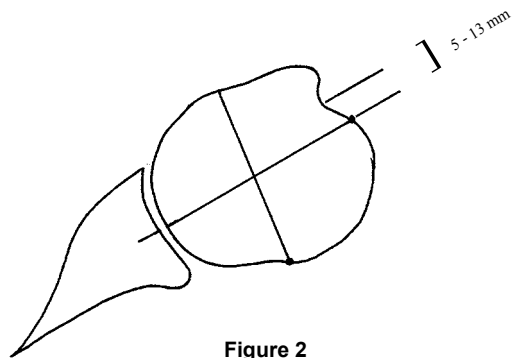


Figure 2

## Patient Positioning, Prepping, Draping

After induction of general endotracheal or scalene block anesthesia, the patient is placed in what is commonly referred to as the “beach chair” position.

This involves flexion of the operating table, elevation of the back and lowering of the legs. Three to four folded towels are placed under the affected scapula to increase glenoid exposure. The use of a headrest provides stabilization for the neck and head during surgery (Figure 3).

The patient’s body is brought as far laterally as possible on the operating table toward the side of the operated extremity (Figure 4). This allows for extension of the shoulder and facilitates humeral shaft exposure and reaming.

A ten-minute iodine prep with sterile orthopedic draping technique is utilized. Unless contraindicated, a first-generation cephalosporin is utilized as a preoperative prophylactic antibiotic.

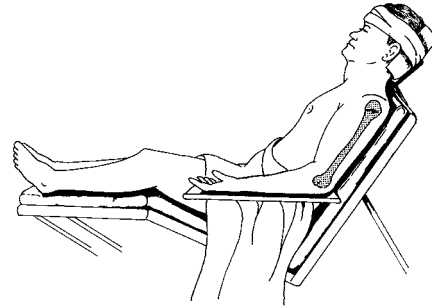


Figure 3

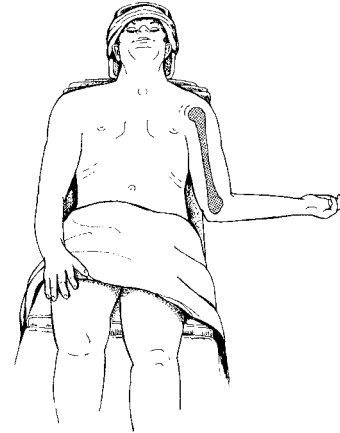


Figure 4

# Exposure of the Joint for Total Shoulder or Hemiarthroplasty

## Examination Under Anesthesia

Preoperative examination under anesthesia is needed to determine the amount of fixed capsular and subscapular contracture.

Sometimes, especially in rheumatoid arthritis, external rotation is significantly improved while the patient is anesthetized, indicating no fixed contracture.

On the other hand, examination under anesthesia may reveal that the arm cannot be brought beyond neutral: in that event, **subscapularis Z-plasty, medialization of the subscapularis, or capsulectomy will be required** to improve postoperative external rotation (see page 8).

## Skin Incision and Superficial Dissection

The bony landmarks are palpated and the skin incision is drawn out on the skin. **The incision runs from the distal clavicle to the deltoid insertion centered over the coracoid process (Figure 5).** The coracoid process is an excellent landmark for the deltopectoral interval.

After the skin incision is marked, the skin of the incision is infiltrated with a .25 marcaine and 1:500,000 epinephrine for early hemostasis and postoperative pain relief.

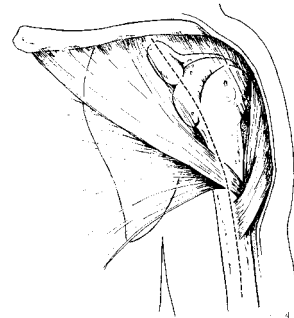


Figure 5

The fascia over the deltopectoral interval is incised and two Gelpie retractors are used to retract the skin. The areolar tissue running obliquely between the muscle planes identifies the deltopectoral groove. In most shoulders, the cephalic vein is found within this groove (Figure 6).

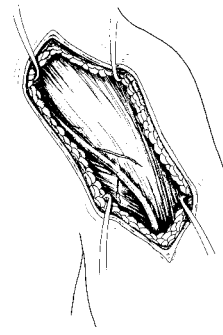


Figure 6

An army-navy retractor is placed initially in the deltopectoral interval. In shoulder replacement, because of the need for proximal dissection, **it is usually easier to take the vein medially with the pectoralis**. Occasionally, the vein requires ligation, but this is not routinely recommended due to a noted increased incidence of postoperative swelling, pain and phlebitis when the vein has to be ligated. Care must be exercised, especially with rheumatoid patients, as the cephalic vein is quite fragile and can be lacerated by overzealous retraction.

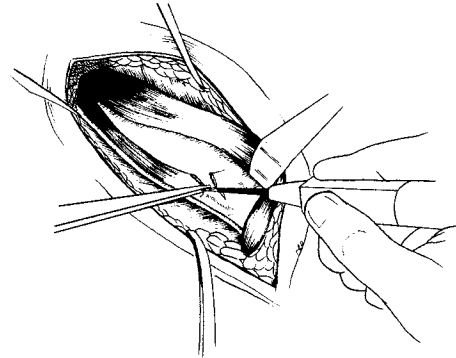


Figure 7

Once deep to the deltopectoral interval, the upper 1cm of the pectoralis major tendon is incised with cautery to aid in exposure (Figure 7).

The clavipectoral fascia is incised and the conjoined tendon visualized (Figure 8). An army-navy retractor is inserted underneath the conjoined tendon. Sharp dissection is carried out on the lateral side of the conjoined tendon only.

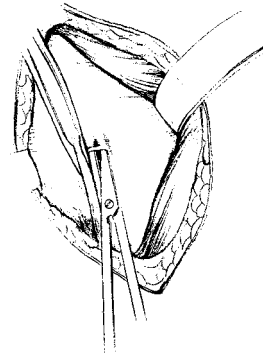


Figure 8

## Deep Dissection

The axillary nerve can be palpated or visualized in the quadrilateral space and the musculocutaneous nerve palpated on the undersurface of the coracobrachialis (Figure 9).

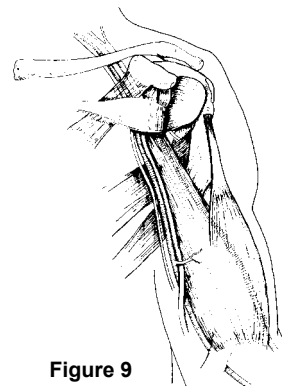


Figure 9

If scarring is not present and external rotation is normal, the subscapularis and capsule can be incised routinely 1.5cm from their insertion and tagged with sutures for reattachment (Figure 10). Alternatively, the subscapularis can be removed from or with bone, and reattached via sutures through bone. A synovectomy in the rheumatoid patient is an important adjunct to shoulder arthroplasty. If scarring and a fixed contracture are present, a Z-plasty can be performed as described starting on page 8.

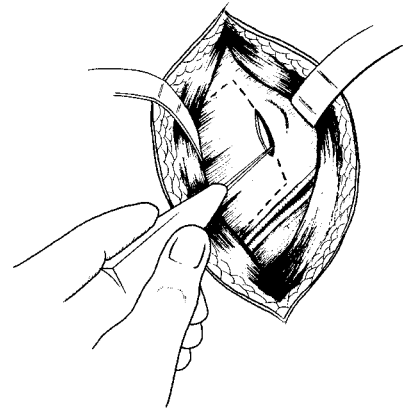


Figure 10

Next, attention is turned proximally. Palpate the rotator cuff to check integrity. If intact, the coracoacromial (CA) ligament is most often incised. However, in the patient with a **massive cuff tear, the CA ligament is preserved to prevent postoperative superior migration.**

Gentle retraction on the conjoined tendon is normally enough to facilitate exposure of both the proximal humerus and glenoid. However, in patients with marked medial glenoid erosion, a portion of the conjoined tendon may be incised or the coracoid osteotomized. **If the coracoid is osteotomized, the assistant holding retractors must be careful to avoid pulling too hard on the conjoined tendon and injuring the brachial plexus.**

A number of soft tissue options are available for lengthening the subscapularis capsule complex. These include incising the subscapularis off of the lesser tuberosity without a cuff and reinserting it medially at the time of closure, and Z-lengthening. For patients with normal external rotation or mild contracture, the subscapularis can be taken down 1cm from the lesser tuberosity and a capsulectomy performed.

Frequently, especially in old trauma, the anatomy is quite distorted. The biceps tendon can generally be found, except when ruptured, and is an excellent landmark. It can be traced towards the proximal humerus, where dissection of the biceps tendon is carried up through the rotator interval, defining the soft spot between the supraspinatus and subscapularis. The subscapularis can then be taken sharply down off the lesser tuberosity (Figure 11).

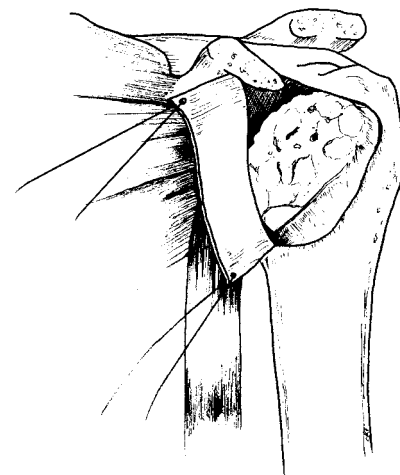
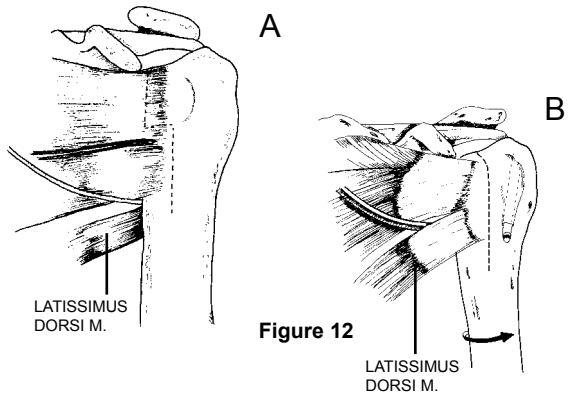


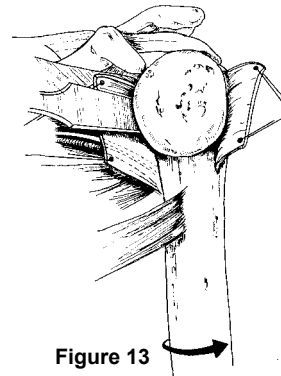
Figure 11



Opening the rotator interval all the way to the glenoid rim is critical for exposure. Subperiosteal dissection just medial to the biceps with the arm in maximum external rotation will protect the axillary nerve behind the elevated soft tissue envelope (Figure 12).



The proximal neck is exposed; cautery, ligatures, or vascular clamps are used to ligate the circumflex vessels as required. Careful subperiosteal dissection is required in this area to avoid injury to the axillary nerve. As the humerus is externally rotated by an assistant, the capsule is further incised and the humeral head dislocated (Figure 13).



## Methods of Subscapularis Z-Plasty

When a fixed internal rotation contracture exists, subscapularis Z-plasty is an alternative to gain length and improve postoperative external rotation.

### Method I (Rockwood)

The subscapularis tendon is identified and carefully dissected free of all bursal material. The musculotendinous junction is palpated. The initial incision is a vertical incision just at the musculotendinous junction (Figure 14).

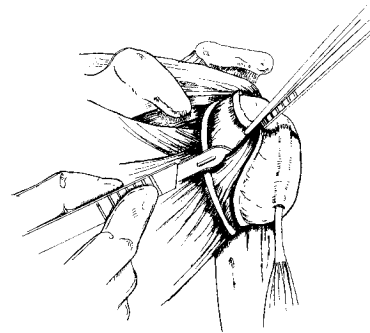


Figure 14

The incision must not go through the entire subscapularis, but instead a coronal Z-plasty is performed (Figure 15). Approximately one-half of the tendon is incised and then dissected free, leaving one-third to one-half of the subscapularis tendon behind as a separate layer attached to the tuberosity.

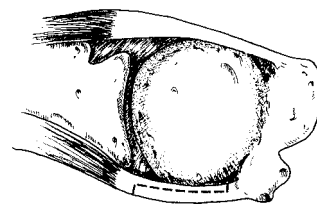


Figure 15

The deep tendon/capsule complex, which has been left behind, is then incised at the anatomic neck, as close to the tuberosity as possible (Figure 16).

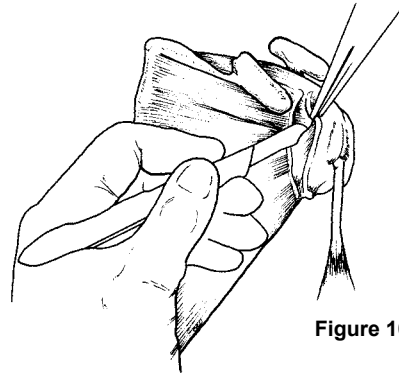


Figure 16

The humerus is externally rotated at the end of the procedure and the tendon edges repaired end to end (Figure 17). As a rule of thumb, 1cm of length yields 20° of external rotation.

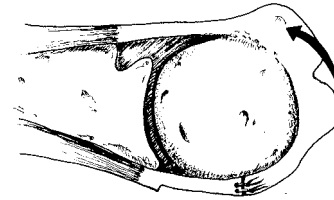


Figure 17

## Method II (Neer)

This method differs from the Rockwood technique in that the dissection occurs from lateral to medial. The initial incision is made at the level of the lesser tuberosity. As previously described, two layers are created as the dissection within the tendon is carried out from lateral to medial (Figures 18 and 19). The deep layer in this approach is released at the glenoid rim. It is my experience that this method gives a greater amount of lengthening.

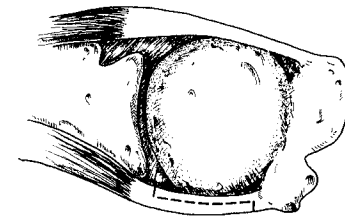


Figure 18

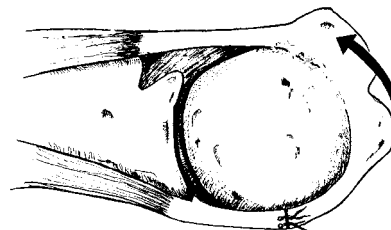


Figure 19

# Humeral Preparation

## Humeral Osteotomy

**Humeral Osteotomy is perhaps the most critical step in total shoulder replacement.** Prior to performing the osteotomy of the humeral head, assessment of osteophytes is made. Marked osteophyte formation, particularly inferiorly, can mislead the surgeon into excessive removal of the neck of the humerus. This can jeopardize the cuff and capsular insertions. Identification of circumferential osteophytes should be made to accurately determine the amount of humeral head normally covered by articular cartilage. Osteophytes are removed by positioning Chandler retractors between the humeral head and the inferior capsule and a **baby Hohmann retractor** between the humeral head and superior rotator cuff and utilizing either an osteotome or rongeur to remove the osteophyte (Figure 20).

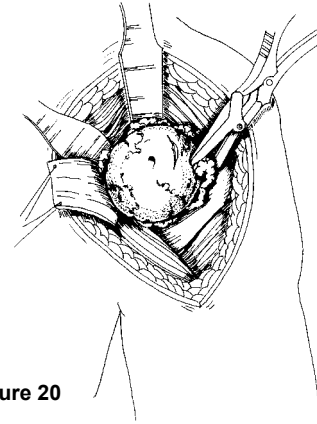


Figure 20

The normal anatomy of the humeral head can now be defined. **Should you wish to remove the osteophytes after humeral head resection, care should be taken not to cut below the osteophytes.** If you are going to err, it is best to err on the side of not cutting enough humeral head as this can be adjusted later during broaching.

Retroversion of the humeral head ranges from 28 to 55°. In addition, it is ordinarily at an angle of approximately 45 to 50° to the shaft of the humerus (Figure 21). Such ranges reflect individualization of the humeral component version necessary to recreate a patient's natural anatomy.

**Certain pathology requires additional alteration.** For example, in patients with arthritis of recurrent anterior dislocation, more retroversion (>35 degrees) may be required for stability. In patients with posterior subluxation from osteoarthritis, less retroversion (<35 degrees) may be appropriate.

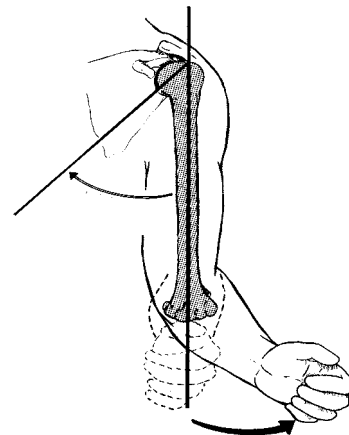


Figure 21

The Select Shoulder IG System offers two initial humeral head osteotomy methods: conventional free-hand or with an extramedullary osteotomy guide.

### Initial Osteotomy I: Conventional

This is the technique I personally use. Position the arm in 35 to 45 degrees of external rotation (Figure 22).

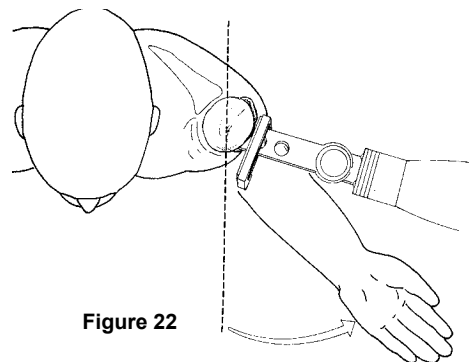


Figure 22

**With the arm in external rotation, the humeral osteotomy template guide is placed on the outer humeral shaft and the osteotomy is marked with methylene blue or cautery (Figure 23).**

The superior lateral saw guide edge should be positioned at the junction of the articular surface with the attachment of the rotator cuff on the greater tuberosity. In many instances, the inferior saw guide edge will be above the inferior osteophyte of the flattened and deformed head of the humerus. The template guide is removed.

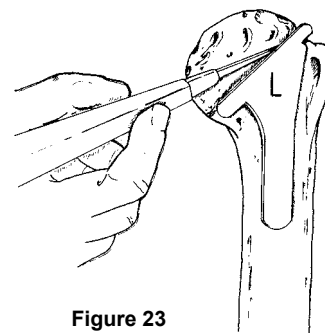


Figure 23

Cutting with the saw perpendicular to the floor should give a 35 degree cut if the elbow carrying angle is 0 degrees. One must assess the patient's carrying angle and adjust accordingly. I personally set each patient's retroversion during broaching for the proximal humerus.

Before the oscillating saw is used to remove the head, protect the biceps tendon and the insertions of the supraspinatus, infraspinatus and teres minor into the proximal humerus, utilizing a baby Hohmann and a large Darrach retractor in the joint. The osteotomy is made just at the junction of the cartilage surface with the bone of the humeral head.

## Extramedullary Osteotomy Guide

Place the **handle** into the **osteotomy guide** with the guide properly oriented for a right or left shoulder. Insert the **universal retroversion indicator rod** into either 45-degree, 30-degree or 15-degree marking (depending on the patient's individual anatomy as indicated by CT scan) and flex the elbow 90 degrees. **Externally rotate the arm. Place the guide along the anterior aspect of the arm parallel to the humeral shaft** (Figure 24). The universal retroversion indicator rod should be parallel to the forearm in order to replicate the patient's natural retroversion.

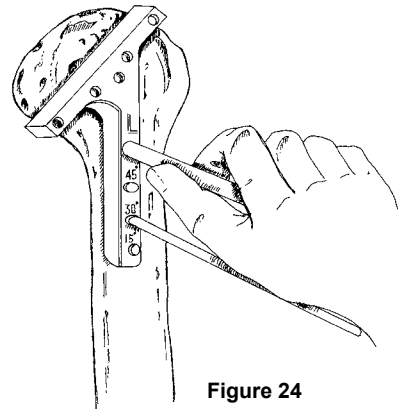


Figure 24

The superior lateral saw guide edge should be positioned at the junction of the articular surface with the attachment of the rotator cuff on the greater tuberosity. The pin holes are drilled and pins are placed into the proximal humerus (Figure 25).

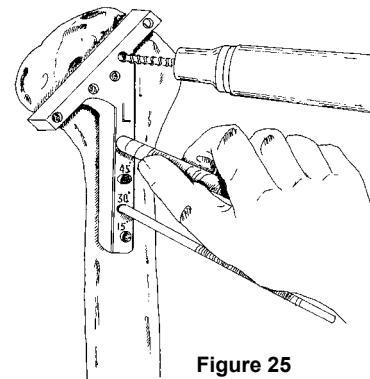


Figure 25

A .040 inch or .060 inch saw capture is then placed onto the proximal portion of the saw guide (Figure 26).

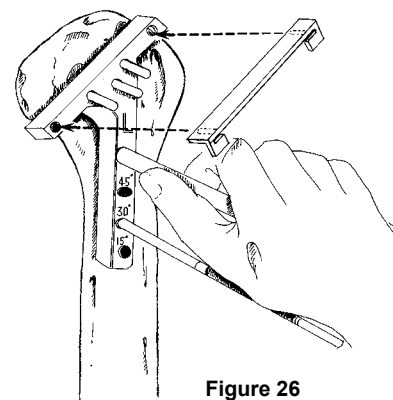


Figure 26

Before the oscillating saw is used to remove the head, protect the biceps tendon and the insertions of the supraspinatus, infraspinatus and teres minor into the proximal humerus, utilizing a baby Hohmann and a large Darrach retractor in the joint. The osteotomy is made just at the junction of the cartilage surface with the bone of the humeral head (Figure 27).

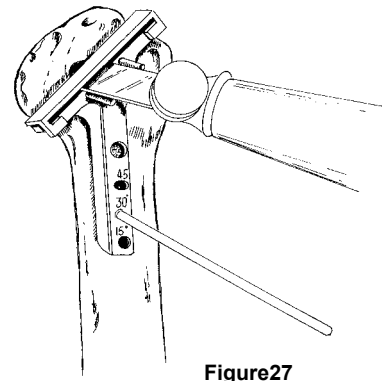


Figure27

The desired retroversion should be accurately obtained (Figure 28).

The resected humeral head is preserved for bone grafting of the glenoid if required as well as for initial head size determination. The pins are removed using the pin puller. The guide is then removed. The pin holes can later serve as conduits for subscapularis reattachment to the proximal humerus.

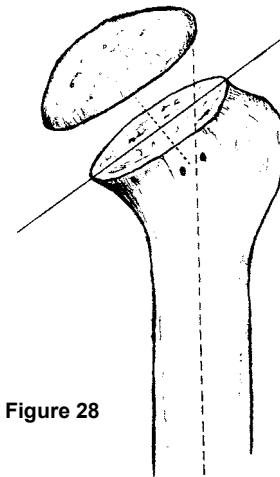


Figure 28

## Humeral Shaft Preparation

The humeral shaft is exposed for medullary canal reaming by using a bone hook extending, adducting and externally rotating the shoulder off the side of the table to bring the cut cancellous surface of the proximal humerus up and out of the incision (Figure 29). A **small Hohmann retractor** frequently is very helpful in retracting the biceps tendon and rotator cuff and levering the humerus out away from the deltopectoral envelope. **Please note that the primary reason for having difficulty in exposing the proximal humerus is the failure of division of the inferior capsule.**

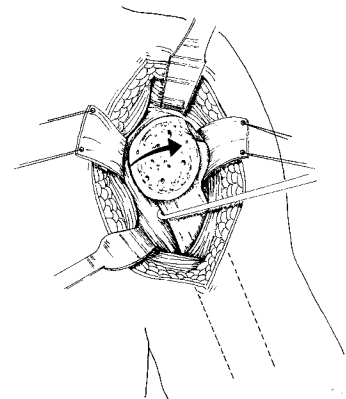


Figure 29

**Fixed T-handled medullary reamers** are used sequentially, starting with the 7mm reamer. A bone awl can be used to initially locate the canal. With the 7mm reamer, create the pilot hole into the cancellous surface of the bone as lateral as possible so that the reamer will pass directly down into the intramedullary canal (Figure 30). **On the 7mm reamer, there is a mark at approximately 80mm of length, indicating the proper reaming depth for the short 7x80 humeral stem.**

Beginning with passage of the 7mm reamer down the humerus until the depth groove/markings at the top of the flute pattern reaches the level of the cut surface of the bone, sequentially use the 8.5mm reamer, then the 10mm, 11.5mm reamer on up until the reamer begins to bite cortical bone in the intramedullary canal of the humerus. The fixed T-handled reamers will cut when turned in either a clockwise or counter-clockwise direction.

**Note: There are separate long reamers for preparation for the long/revision humeral stems.**

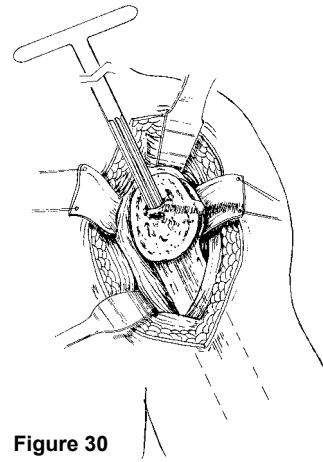


Figure 30

## Proximal Humeral Shaft Preparation and Final Osteotomy

The proximal portion of the humerus is prepared with a series of broaches. Beginning with the **7mm broach**, attach the broach to the broach holder by placing the **broach holder** pin into the hole in the broach and the lever arm into the lateral lip of the broach just proximal to the lateral fin (Figure 31). Squeeze broach holder shaft and handle together tightly. To disconnect press trigger down on the release near the top of the broach holder.

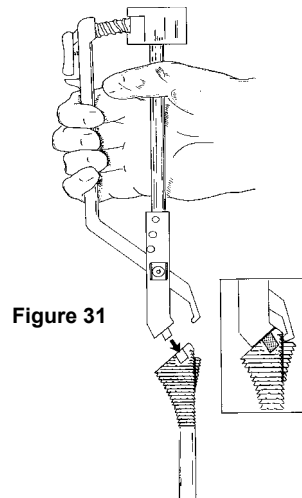


Figure 31

The posterior wall of the bicipital groove subtends the patient's own retroversion angle. Aligning the posterior fin of the broach 5mm to 13mm posterior to the bicipital groove, centering the fin along the greater tuberosity and impacting it will give a broach position approximating the patient's own unique retroversion angle (Figure 32). This distance can be determined preoperatively from a CT scan.

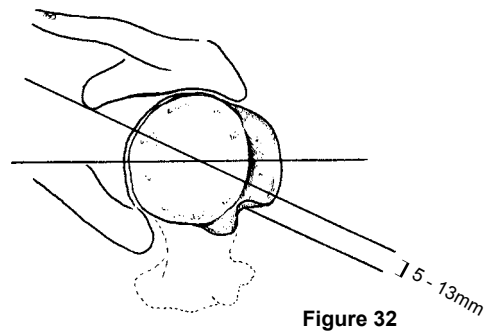


Figure 32

The smooth portion of the broach is slipped into the previously reamed humeral canal. The fin of the broach should be placed in the anterior aspect of the greater tuberosity just posterior to the bicipital groove.

The **universal retroversion indicator rod** can be inserted into the previously selected retroversion (45 degree, 30 degree, or 15 degree) markings, to more precisely match the patient's retroversion (Figure 33). As during the humeral osteotomy, the universal retroversion indicator rod should be parallel to the forearm indicating the initial degrees of retroversion. **Care must be taken during the actual broaching process to maintain the selected humeral stem retroversion.**

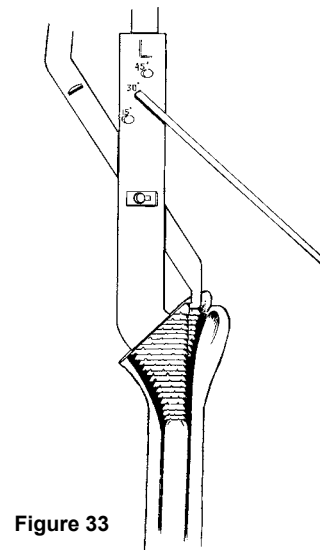


Figure 33

Because the broach is a rasp, gentle impaction **down** and then **up**, using the universal slaphammer impactor/extractor tool, will achieve maximum cutting action (Figure 34). Continue such a **rasp-like impaction until the broach is fully seated and flush with the cut humeral surface**. A trial reduction is then performed. By sliding the universal slaphammer along the broach holder shaft, the broach can be removed.

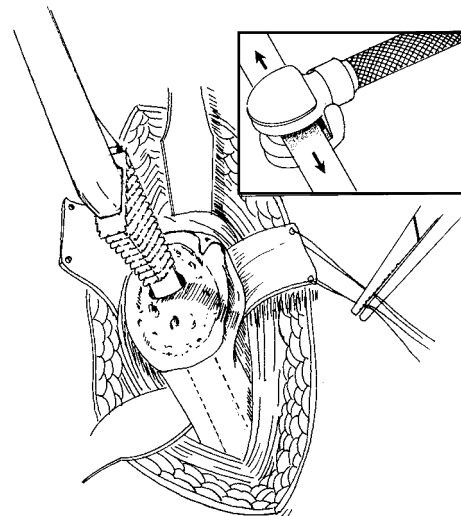


Figure 34



Disconnect the 7mm broach by pushing in the release trigger. Sequentially load the 8.5mm, 10mm, 11.5mm broaches on up and broach accordingly. Once broaching is completed and the broach is stable, leave the final size broach in place by disconnecting the broach holder (Figure 35).

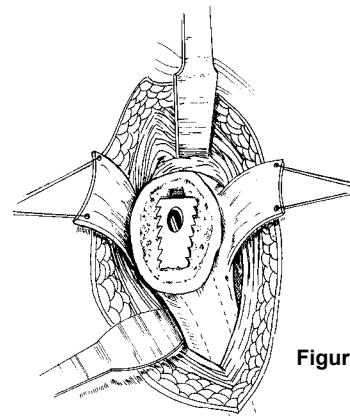


Figure 35

If the surgeon is happy with the trial reduction, then the flat proximal surface of the broach can be used as an intramedullary saw guide (Figure 36).

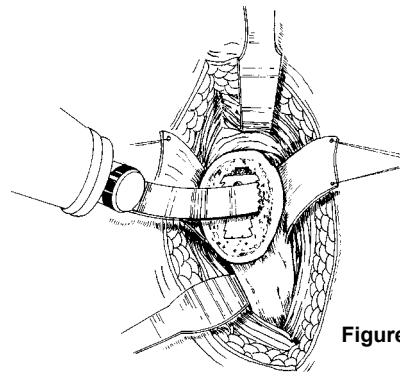


Figure 36

Alternatively, a planer can be used (Figure 37).

The actual cemented implant size that ideally should be used is 2 sizes smaller than the final broach size. For example, if a 10mm broach was used as the final size, selection of a 7mm implant would allow for a 1.5mm circumferential cement mantle.

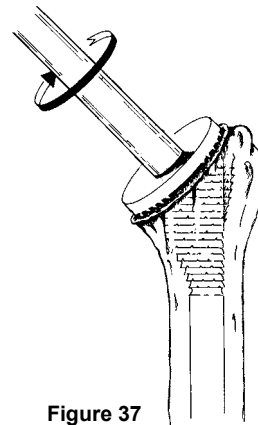


Figure 37

## Preliminary Humeral Head Broach Trialing

The initial broach trial head size is determined by measuring the patient's resected humeral head with a caliper or by comparing the resected humeral head to the color-coded implant head trials (Figure 38).

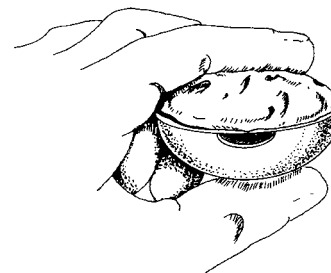


Figure38

The **appropriate color-coded (diameter and height) broach head trial** is selected and is then inserted onto the broach (Figure 39).

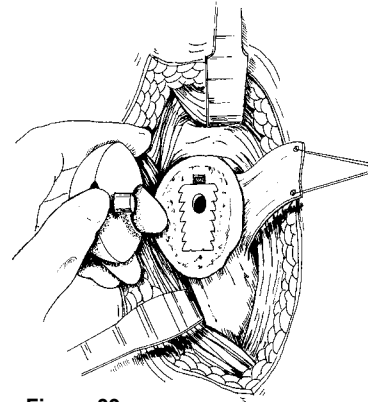


Figure 39

Although final head height selection is made off the implanted stem using the color-coded implant head trials, an estimate can be made at this point based on stability and the ability to cover the implant with the soft tissues (Figure 40).

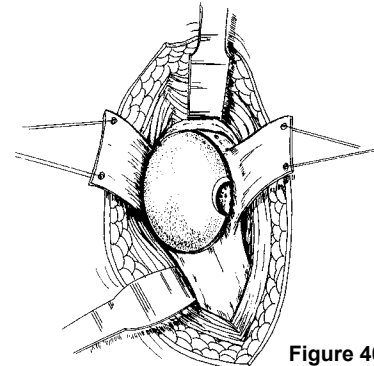


Figure 40

**Please refer to this chart for color-coding references to specific humeral head sizes.**

Humeral Head Sizes	Color of Broach & Implant Head Trials
40mm: All Head Heights	Rust
44mm: All Head Heights	Yellow
48mm: All Head Heights	Green
52mm: All Head Heights	Blue
56mm: All Head Heights	Gray

Chart 1

If the joint is too tight, the final broach impactor can be used to quickly impact the broach deeper without reattaching the broacher holder (Figure 41). Once the broach is more deeply seated, the cut surface will need to be replanned or recut.

Remove the humeral head broach trial. If performing a total shoulder arthroplasty, leave the proximal humeral broach in place and continue with glenoid preparation. By leaving the broach in place, the proximal humerus will be protected from compression fracturing or deformation by the retractor. If performing a hemiarthroplasty, continue with humeral component selection (Section 5, page 29).

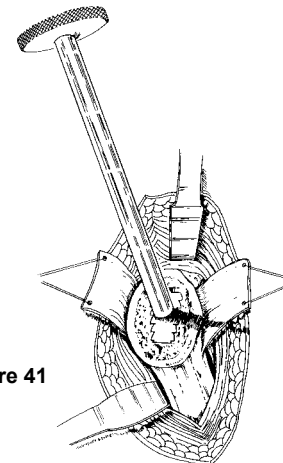


Figure 41

# Glenoid Replacement

## Glenoid Preparation and Selection

Surgical exposure and morphology of the glenoid is variable. In addition to whether placement of a glenoid component is possible or not, these factors will also determine the methods of preparation utilized. It is not always possible to utilize a glenoid reamer, either straight or angled. In these situations, the traditional dental burr method will suffice. Remember, the Select Shoulder IG System offers both the pegged and keeled style glenoids to address varying patient morphology and surgeon preference.

**Adequate exposure of the glenoid is critical for proper glenoid preparation.** This should include, if necessary, incising a portion of the conjoined tendon to allow medial retraction of the short head of the biceps and coracobrachialis. It is important that a Bankhart retractor be utilized so that there is not a direct pull on the plexus, but merely a levering back on the conjoined tendon.

Careful palpation along the rim of the glenoid and into the subscapularis recess will give the operating surgeon a feel for how much bone is left on the glenoid, as well as an idea of orientation. Removal of all of the head superior to the capsule insertion anteriorly and posteriorly will facilitate glenoid exposure as well.

The **glenoid retractor** is inserted posterior to the glenoid rim, positioning the humerus posteriorly. Utilizing a knife, a circumferential capsulotomy opening the subscapularis recess is performed (Figure 42). The labrum can be maintained if normal (i.e., hemiarthroplasty). If abnormal, the labrum is removed.

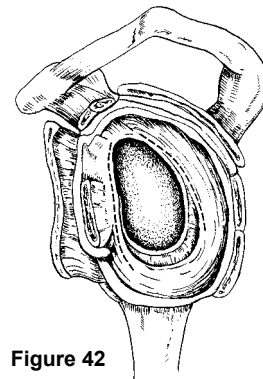


Figure 42

A Darrach retractor placed superiorly beneath the superior capsule, biceps, and supraspinatus will also help with superior exposure on the glenoid (Figure 43).

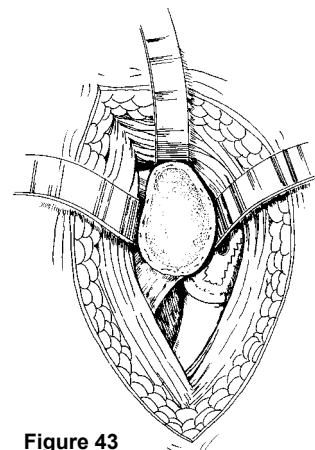


Figure 43

## Glenoid Selection: Which Style Do I Use?

Styles, as well as bearing surfaces, are designed to address varying patient glenoid morphology and physician philosophy. A curved backed, two pegged, all poly component, as well as two curved keeled components are offered. The conforming glenoid component offers line-to-line conformity and congruency, but remains unconstrained. The non-conforming glenoid offers a 4mm diametrical mismatch between the humeral head and the glenoid component, allowing obligate passive translation to occur.

The selection of the proper size glenoid is important. A set of five (40mm, 44mm, 48mm, 52mm and 56mm) glenoid sizer discs (Figure 44) is available.

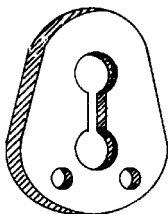


Figure 44

The discs are color-coded to match the corresponding color-coded humeral head broach and implant trials as well as the glenoid trials (keeled and curved-back pegged only) for proper range of translation (Chart 2).

GLENOID FIXATION TYPE			
	Advantages	Disadvantages	Recommended Use
<b>Pegged Component</b>	Cement Pressurization Possible	Harder to perform	Younger, active patients
<b>Keeled Component</b>	Ease of application	Cement mantle sees more stress from rocking	Older patients, less experienced surgeons

GLENOID BEARING SURFACE	
Semi-constrained (Non-Conforming)	Younger patients where improved range of motion is required
Congruent (Conforming)	Older patients to create a more stable construct, in patients with weaker cuffs and deltoid

Sizer Disc Size	Sizer Disc Color
X-small	Rust
Small	Yellow
Medium	Green
Large	Blue
X-Large	Gray

Chart 2

## Curved, Pegged Glenoid Preparation

After capsular release and debridement of the glenoid osteophytes, **the universal glenoid drill guide template** is placed on the arthritic glenoid face. To ensure proper placement, the plate should be centralized along the axis of a line from a point immediately below the base of the coracoid to just above the infraglenoid tubercle and includes the cancellous bone at the base of the coracoid process. Palpation of the base of the coracoid is necessary to establish orientation in case eccentric wear of the glenoid labrum is present.

The handle of the drill guide template is malleable and can be formed into the appropriate angle that conforms to individual surgeon preference. The location of the central hole on the face of the template is then marked with a Bovie (Figure 45). The guide is removed.

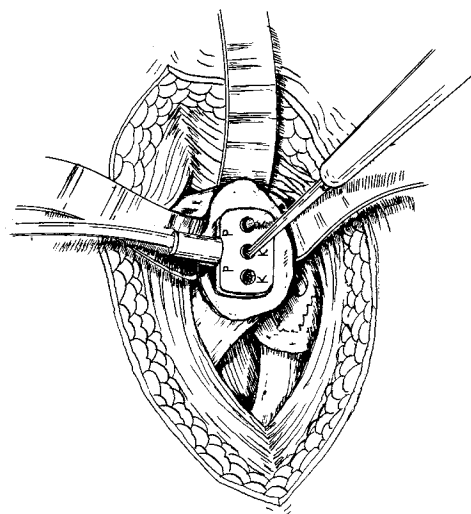


Figure 45

The Select Shoulder IG System provides two types of **glenoid power hand drivers; 45 degree angled and straight** (Figure 46a & b). Both are fitted with a standard Jacob's chuck fitting for attachment to most standard OR drills.

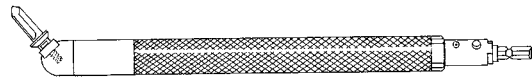

Figure 46a



Figure 46b

Attach the universal **2.0mm stop drill bit** to the driver using the **universal driver shaft and reamer wrenches**.

Then with a finger along the glenoid neck as a guide for the drill, drill the marked hole until the stop on the bit is reached (Figure 47). Remove the 2.0mm stop drill bit from the glenoid powered hand driver using the **universal driver shaft wrench**.

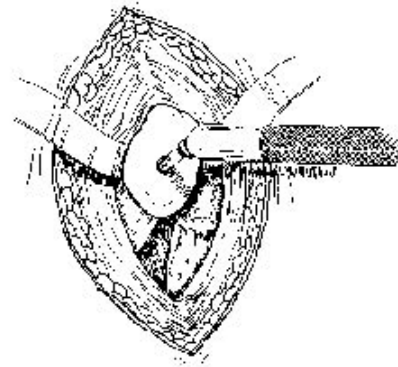


Figure 47

Using the glenoid sizer disc and forceps, select the appropriate disc size that covers the face of the glenoid fossa with no overhang (Figure 48). Note size and remove disc from the surgical wound.

Select the appropriate-size **curved-backed glenoid reamer disc** based on initial size determined from the glenoid sizer disc. (See chart 2, page 19). Thread the reamer disc onto the glenoid powered hand driver.

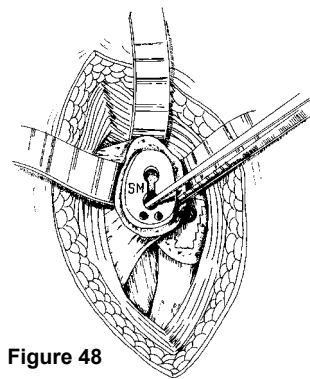


Figure 48

Place the pilot of the reamer disc into the previously drilled 2.0mm peg hole and ream the glenoid until it has a smooth curved configuration that matches the contour of the medial surface of the trial (Figure 49).

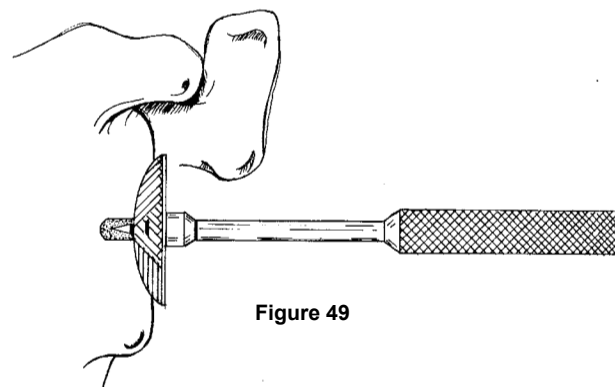


Figure 49

Please ensure that the following steps are taken while reaming the glenoid:

- Engage the power to the glenoid reamer while the tip of the reamer is in the pilot hole, but before it comes in contact with the bone. If the reamer disc is held tightly against the glenoid before the power is started, the reamer disc may bind up, grab the bone and cause damage to the power drill and/or the bone.
- **With the reamer disc engaged, insert the reamer disc pilot into the pilot hole in the glenoid and apply gentle pressure to the reamer. Gradually increase the pressure on the reamer disc. The reamer disc should only be used until the surface of the glenoid fossa is smooth. Be careful not to overream the glenoid fossa.**
- The reamer is removed using the universal shaft and reamer wrenches (Figure 50).

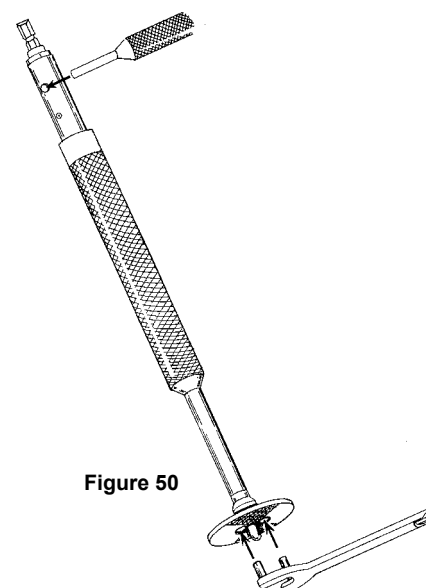


Figure 50

In the case of inadequate glenoid exposure, utilize the x-small reamer disc. Please note that an unreamed edge will be present when utilizing the x-small reamer disc. To complete proper glenoid surface contouring, utilize a burr to contour the edge until the selected glenoid trial seats firmly on the surface.

Proceed to drilling of the holes for the implant pegs by again placing the universal glenoid drill guide template on the prepared glenoid surface. Ensure proper alignment as previously, and mark the two outer holes of the template with a bovie. With a finger along the glenoid neck as a guide, utilize the 7.5mm stop drill bit to drill the two marked holes until the stop on the bit is reached. The 7.5mm drill bit is the proper length for full preparation of the implant pegs including a cement mantle. A pressurized cement mantle for the pegged glenoid can be created by using an angled curette to create a channel connecting the two holes for better anchoring of the implant (Figure 51).

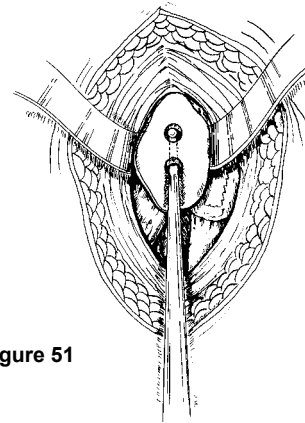


Figure 51

Trialing for the implant is then performed using the **x-small, small, medium, large and x-large pegged glenoid trials** (Figure 52). Ensure that the glenoid trial is seated securely on subchondral bone and that there is no gap on either the most anterior or posterior back of the glenoid trial.

If there is a gap anteriorly or posteriorly, and the pegs of the trial are seated securely, this is an indication of residual asymmetric wear on the glenoid. **The exposed face of the glenoid should be contoured so that the prosthesis seats securely, both on the anterior and posterior surface utilizing the appropriate-size reaming discs or a burr.**

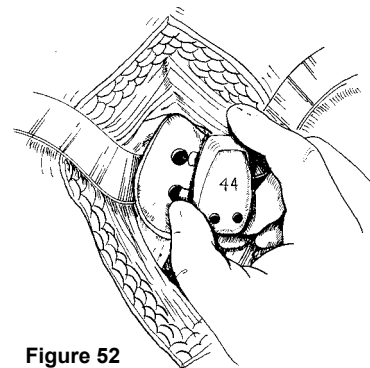


Figure 52

If asymmetric glenoid wear is too excessive to allow proper contouring for a glenoid component to rest on adequate anterior or posterior subchondral bone, consider bone grafting of the glenoid, using the resected humeral head as the bone graft source. This should provide adequate bone stock on which the glenoid implant component can rest. **If the glenoid trial does not fit completely into the holes and there is risk of penetrating through the scapula, the polyethylene pegs of the implant can be shortened on the table using scissors. Do not trim more than 50% of the length of the pegs.**

The holes are irrigated and dried. Gelfoam is applied as needed; sterile hydrogen peroxide or an epinephrine-soaked sponge can be utilized to control bleeding. Cement is then injected into the holes using a catheter tip syringe or Zimmer right angle glue gun with the cement in a liquid state (Figure 53). A finger placed over one of the holes allows for pressurization of cement. The glenoid is then inserted into the holes and excess cement is cleared.

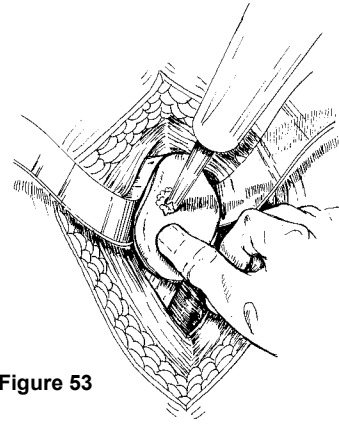


Figure 53

Obtain uniform pressure by attaching a **color-coded humeral head trial** to the **glenoid pressure applicator rod** and placing the head onto the articulating surface of the glenoid until the cement is cured (Figures 54 and 55). Verify that the glenoid implant is securely fixed. If it is loose, remove and recement it.

Once the glenoid has been cemented and the glenoid retractor removed, be careful when delivering the proximal humerus into the wound that the proximal humerus does not lever against the newly cemented glenoid. Place a bone hook in the neck of the humerus, pulling laterally while the arm is gently rotated externally.

Ensure adequate clearance of the greater tuberosity by finger palpation. Check the joint for loose or protruding fragments of methylmethacrylate. Remove them carefully with an osteotome or rongeur.

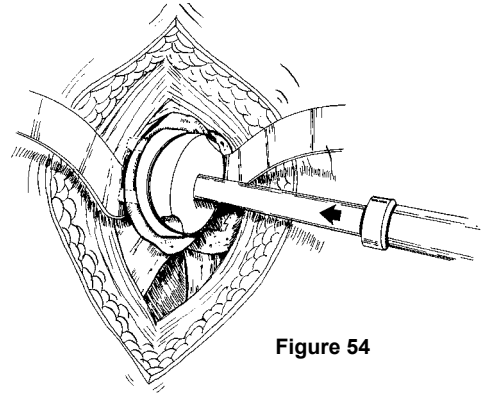


Figure 54

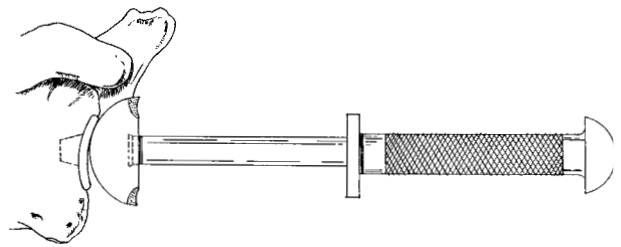


Figure 55



## Keeled Glenoid Preparation

Surgical exposure and morphology of the glenoid is variable. In addition to whether placement of a glenoid component is possible or not, these factors will also determine the methods of preparation utilized. It is not always possible to utilize a glenoid reamer, either straight or angled. In these situations, the traditional dental burr method will suffice. Remember, the Select Shoulder IG System offers both the pegged and keeled style glenoids to address varying patient morphology and surgeon preference.

Upon capsular release and debridement of glenoid osteophytes, the **universal glenoid drill guide template** is placed on the arthritic glenoid face. The location of the three holes indicated with a "K" on the face of the template should be oriented so that it lies directly in the cancellous bone of the glenoid neck. This orientation is often difficult particularly if excessive wear anteriorly or posteriorly has occurred. With the anterior capsule detached, palpate the anterior glenoid neck to aid in proper orientation of the template guide. Mark only the central "K" hole using a Bovie (Figure 56). The guide is then removed.

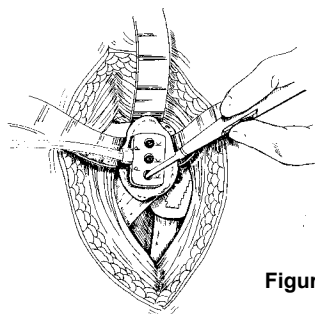


Figure 56

Depending on surgeon preference for straight or 45-degree angled glenoid planing and drilling, select a **universal glenoid power hand driver** (Figure 57). Attach the **universal 4.5mm stop drill bit** to the driver using the **driver shaft and planer wrenches** (Figure 58).

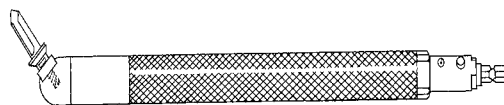

Figure 57



Figure 58

Then, with a finger along the glenoid neck as a guide for the drill, drill the central hole until the stop on the bit is reached (Figure 59). Remove the 4.5mm stop drill bit from the glenoid powered hand driver using the universal driver shaft and planer wrenches. **If using a burr, only penetrate subchondral bone to avoid perforating the glenoid vault.**

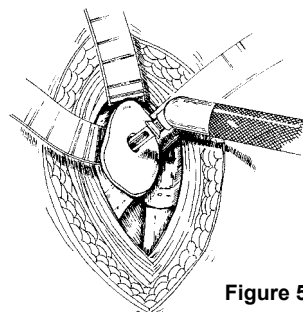


Figure 59

Place the appropriate glenoid sizer disc on the face of the glenoid using forceps. Ensure that the face of the glenoid fossa is fully covered with no overhang. Note the size and remove the disc from the surgical wound.

Select the appropriate-size **curved-back glenoid planer disc** based on initial size determined from the glenoid sizer disc (See Chart 2, page 19). **Note: Be sure that the planing disc is curved and not flat for accurate preparation of the glenoid surface for the curved backed glenoid implant.** Thread the planing disc onto the glenoid powered driver by hand. Place the pilot of the planing disc into the centrally drilled hole (Figure 60) and ream the glenoid until it has a smooth curved configuration that matches the contour of the medial surface of the curved-backed glenoid trial.

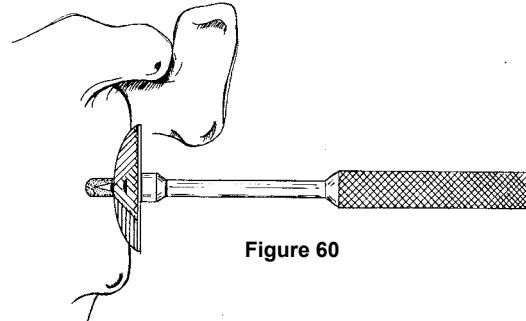


Figure 60

Please ensure that the following steps are taken while reaming the glenoid:

- Engage the power to the glenoid planer while the tip of the planer disc is in the pilot hole, but before this disc comes in contact with the bone. If the planer disc is held tightly against the glenoid before the power is started, the planer disc may bind up, grab the bone and cause damage to the power drill and/or the bone.
- With the planer disc engaged, insert the planer disc pilot into the pilot hole in the glenoid and apply gently pressure to the reamer. Gradually increase the pressure on the planer disc. The planer disc should only be used until the surface of the glenoid fossa is smooth. Be careful not to overream the glenoid fossa.
- The planer disc can be removed using the universal drive-shaft and planer wrenches.

Reapply the universal drill guide template, mark the other two holes with a Bovie and then drill them with the 4.5mm stop drill bit applied to the power driver (Figure 61).

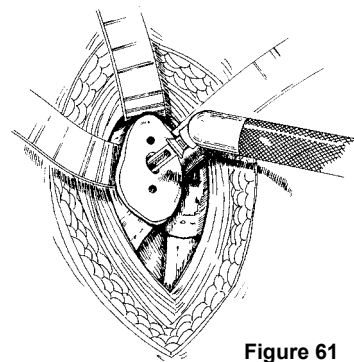


Figure 61

Next, prepare the longitudinal slot for the keel of the glenoid. **The slot extends along the axis of a line from a point immediately below the base of the coracoid to just above the infraglenoid tubercle, and includes the cancellous bone at the base of the coracoid process.** Palpation of the base of the coracoid is necessary to establish proper orientation in case eccentric wear of the glenoid labrum is present.

Using a 4mm small burr, connect all three drill holes to form the keel slot (Figure 62).

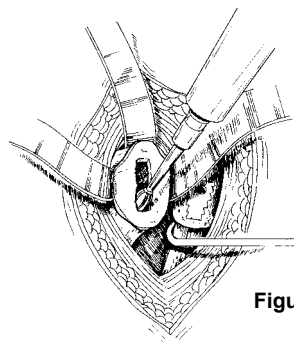


Figure 62

Once the subchondral bone is slotted with the burr, completion of the slot and undermining of the glenoid vault is completed with a small angled curette (Figure 63).

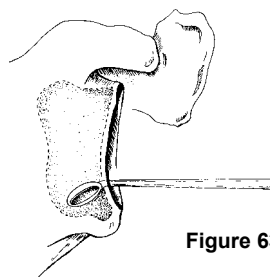


Figure 63

Excavation of the base of the coracoid, superomedially and the scapular border, inferiorly, will create interstices in which bone cement can be impacted (Figure 64).

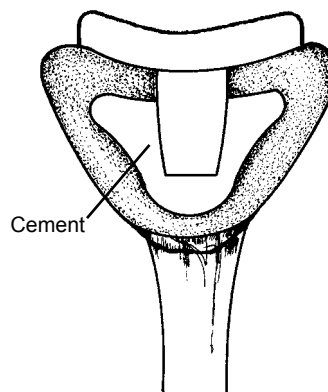


Figure 64

Desired length, width and depth of the slot can be checked by using the **keel sizer** and/or **keeled glenoid trials**. The appropriate sizer is selected (medium sizer for XS, S and M keeled glenoid implants; and large sizer for L and XL implants) and will provide **line-to-line** reference to the respective implant keel. The handle is malleable and can be formed into the appropriate angle that conforms to individual surgeon preference.

The appropriate implant trials also reference line-to-line to the implant. Varying glenoid morphology may preclude an ideal cement mantle. In these situations, the medium or large keel sizer will quickly confirm whether or not the slot will accommodate the respective implant (Figure 65).

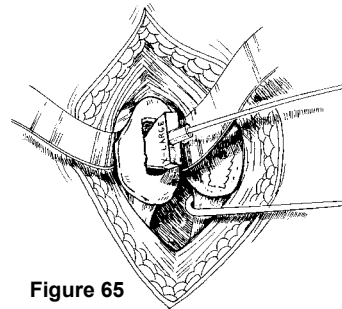


Figure 65

Use of the sizer during the burring and excavation process will provide an efficient means of calibrating minimum slot size prior to use of implant trials. **Do not widen the keel slot too extensively, or the component will toggle and secure seating will be difficult.** Drill several holes in the subchondral bone for better anchoring of the bone cement.

To perform a trial reduction, place the capsule in a relaxed position, lateral traction via a bonehook can be applied and the appropriate glenoid trial inserted based on the original sizing indicated by the glenoid sizer-discs (Figure 66).

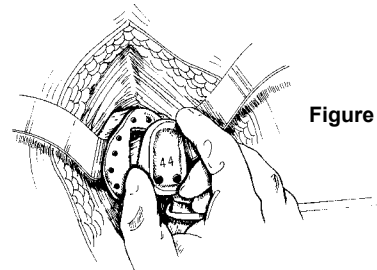


Figure 66

**Please note that the keeled glenoid trials with a hole through the keel are the congruent style glenoids.**

If there is any rocking, identify the area of improper preparation and correct it appropriately. The glenoid trial may be used to determine if the glenoid is seated securely on subchondral bone and if there is any gap on either the most anterior or posterior back of the glenoid trial. If there is a gap anteriorly or posteriorly, and the keel of the glenoid trial is seated securely, this indicates that there is residual asymmetric wear on the glenoid. The exposed face of the glenoid should be contoured so that the prosthesis seats securely, both on the anterior and posterior surface.

The slot is thoroughly irrigated and dried. Gel foam, Surgicil and Thrombin are applied as needed for hemostasis. When the cement is ready, remove gauze or sponge and with finger pressure or a glue gun impact cement into the slot (Figure 67).

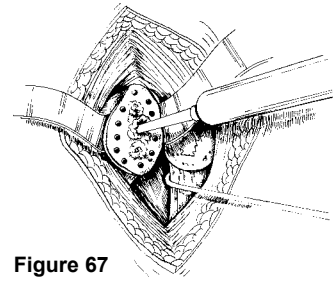


Figure 67

Apply a layer of cement to the medial surface of the implant. Seat the glenoid implant, remove all excess cement and secure in place (Figure 68).

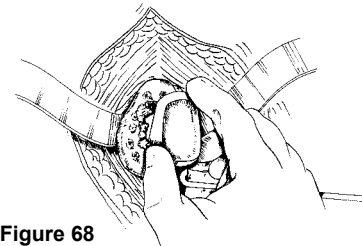


Figure 68

Obtain uniform pressure by attaching the **matching sized color-coded humeral head trial to the glenoid pressure applicator rod** and place the head onto the articulating surface of the glenoid utilizing pressure until the cement is cured (Figure 69). Verify that the glenoid implant is securely fixed.

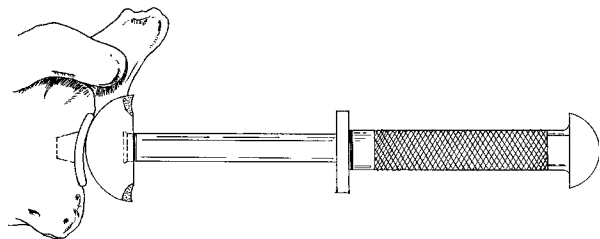


Figure 69

Once the glenoid has been cemented and the glenoid retractor removed, be careful when delivering the proximal humerus into the wound that the proximal humerus does not lever against the newly cemented glenoid. Place a bone hook in the neck of the humerus, pulling laterally while the arm is gently rotated externally.

Ensure adequate clearance of the greater tuberosity by finger palpation. Check the joint for loose or protruding fragments of methylmethacrylate. Remove them carefully with an osteotome or rongeur.

## Final Implantation

Prior to stem insertion, ensure that the soft tissue is completely mobilized, especially if the rotator cuff has been torn and retracted. The biceps tendon may get caught beneath the humeral head as the component is being inserted so gently retract it.

## Humeral Shaft Cement Technique

Once the stem is selected and the general head height and radius of curvature are known, the sterile, prepackaged prosthesis is obtained. Prior to removing the broach from the humeral shaft, a cautery should be used to mark the fin position in the tuberosity area. This will facilitate lining up the prosthesis for final seating. Proceed to remove the broach using the broach holder and universal slaphammer tool.

Cementing the humeral component necessitates, if possible, reaming and broaching to a two-size larger implant (i.e., when cementing a 7mm stem, one should ream and broach to a 10mm stem size. This will provide a 1.5mm circumferential cement mantle).

A 32-ply surgical sponge is placed in the glenoid to prevent seepage of cement around the glenoid component or articular surface of the glenoid. The humeral shaft is irrigated thoroughly and brushed with an I/M brush. Bone or a commercially available plug is utilized to plug the humeral shaft.

A glue gun, if it will fit, or a Toomey syringe is used to apply the cement. The humeral canal is filled with methylmethacrylate in a relatively liquid phase. Use of a rubber dam proximally will facilitate packing and cement pressurization.

The sterile humeral stem implant is locked into the impactor guide (Figure 70).

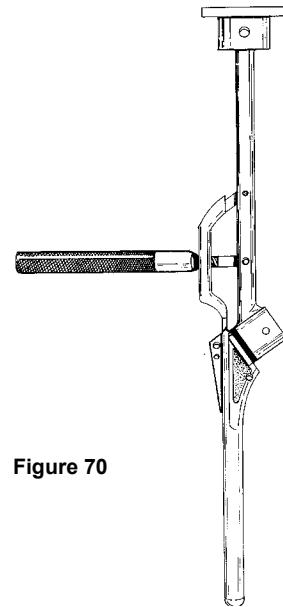


Figure 70

Drill holes must also be made in the shaft of the humerus from lateral to medial, for further fixation with Dacron Sutures (Figure 71).

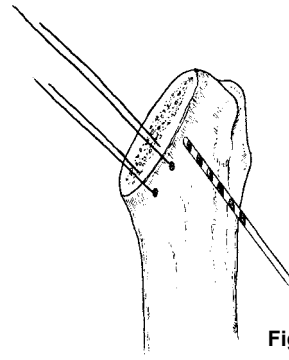


Figure 71

The sterile stem implant is then placed gently into the humeral shaft until the proximal segment engages the humeral shaft (Figure 72). **The impactor guide is then removed.** Final alignment is based on the cut surface of the proximal humerus as well as the point where the fin from the broach has met the tuberosity.

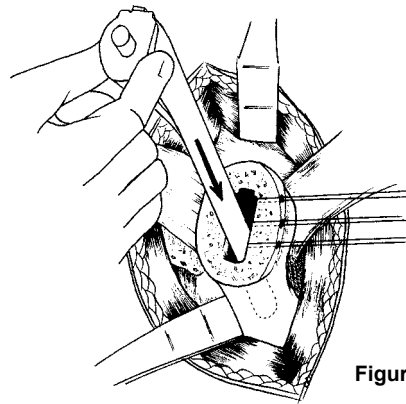


Figure 72

The humeral component is driven all the way in with an angled **humeral stem impactor** and **mallet** (Figure 73). The use of a modular system such as this facilitates cement removal, as the head does not interfere with visualization and removal of the cement.

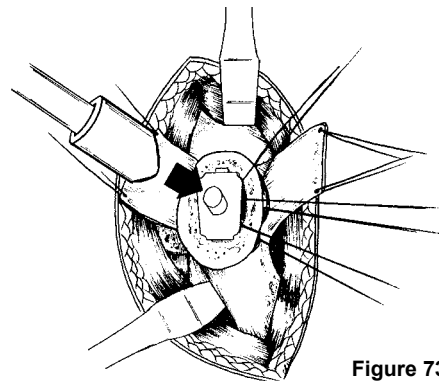


Figure 73

After the cement has hardened and excess cement has been removed, a final trial reduction is performed with the **corresponding color-coded implant trial heads**.

Once the trial reduction is satisfactory, the concave humeral head impactor is now used to impact the selected humeral head implant onto the male taper of the humeral stem by hitting it at least three times (Figure 74).

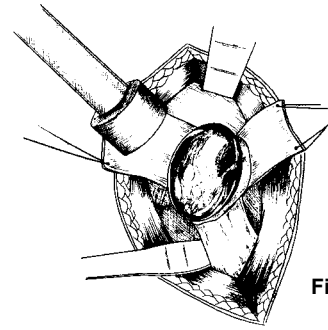


Figure 74

**It is extremely important to dry the taper and remove any soft tissue or cement which may interfere with final seating of the cobalt chrome head.** It should be noted that upon final impaction, the humeral head will not be seated flush with the humeral stem collar, but will instead have a slight clearance. This clearance is to aid in extraction of the head from the stem during revision surgery if necessary.

While the final decision on which humeral head/glenoid combination to use must be left to the surgeon, certain combinations with congruent keeled glenoid components are not recommended.

Chart 3 denotes these combinations that are not recommended since they will not allow articular contact at the center of rotation.

Select Shoulder System  
Recommended Size Combinations  
(Humeral Heads with Congruent Keeled Glenoids)

	40mm	44mm	48mm	52mm
XSM	OK	Not recommended	Not recommended	Not recommended
SM	OK	OK	Not recommended	Not recommended
MED	OK	OK	OK	Not recommended
LG	OK	OK	OK	OK
XLG	OK	OK	OK	OK

Chart 3



## Joint Reduction and Subscapularis Tendon Attachment

With gentle traction, internally rotate the humerus and apply finger pressure on the humeral prosthesis. Reduce the head into the glenoid fossa. Following joint irrigation, pass the previously placed Dacron tape sutures in the subscapularis tendon into the loop of sutures in the proximal humerus. Pull the loops of sutures with the Dacron tapes out through the bone and use the tapes to secure the tendon back to the bone (Figure 75).

If the tendon was previously divided or was lengthened with a coronal Z-plasty technique, then repair and secure it with heavy nonabsorbable 1mm Dacron tape sutures. Use of the heavy 1mm tape sutures allows immediate passive movement beginning the day of surgery without the risk of detaching the subscapularis tendon.

Cuff repair is also performed at this time if required. Before wound closure, palpate the axillary nerve a final time to assure that it is in its normal position and intact.

Postoperatively, a sterile dressing is applied and the patient is maintained in an arm immobilizer. If the rotator cuff has been repaired, an abduction pillow may be required.

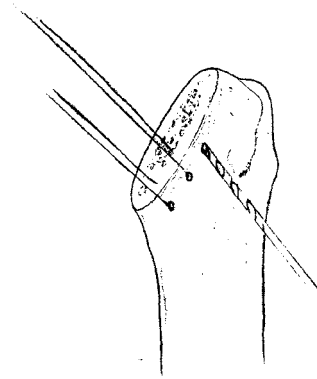


Figure 75

## Revision: Removal of the Implant

At the time of revision surgery, the Select Shoulder can be removed as follows:

- The two-piece wedge humeral head distractor is placed under the head. The flat bar is then inserted into the slotted portion where it levers the head off (Figures 76 and 77).
- The stem can be removed by reattaching the implant holder and utilizing the universal slaphammer impactor/extractor tool. It may be necessary to use small osteotomes or specialized equipment (Anspach or Midas Rex) to loosen cement, excess bone and soft tissue from around the prosthesis.

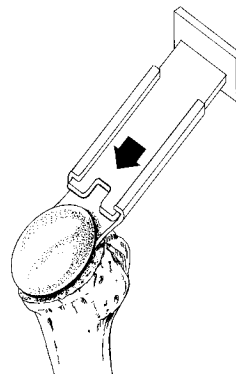


Figure 76

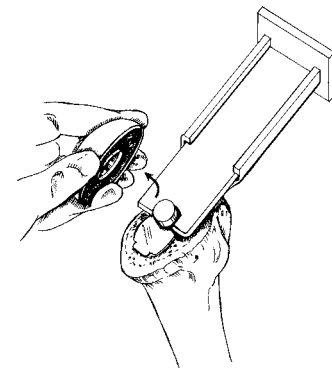


Figure 77

## Head Style Selection

There is an average 5mm posterior off-set of the humeral head from the humeral shaft, as well as a varying medial off-set. Like any other average, there are varying degrees of off-set, the mean of which represents this average. If the implant is centered in the humeral canal, a mismatch may occur (Figure 78a). This is less apparent with press-fit implants with good proximal fill, but minor degrees of off-set can occur. If there is no marked off-set between the stem and the cut surface of the humeral head, a neutral Cobalt Chrome head can be applied, as in Figure 78b. On the other hand, if there is a significant off-set, either anteriorly or posteriorly, because of the patient's own anatomy, then an off-set head can be utilized to match the prosthetic humeral head to the patient's cut surface. If an off-set head is chosen, the off-set trial should be applied and rotated until the prosthetic trial covers completely the patient's own resected humeral head. A bony landmark is chosen, such as the bicipital groove of a fin of the prosthesis, and the reference number taken off of the trial component. The scrub nurse can then mark the permanent Cobalt Chrome implant with a marking pen above that number and that mark, placed with the previously selected bony landmark. Tapers should be dried and the humeral head impacted with at least two, if not three, sharp blows from the impactor.

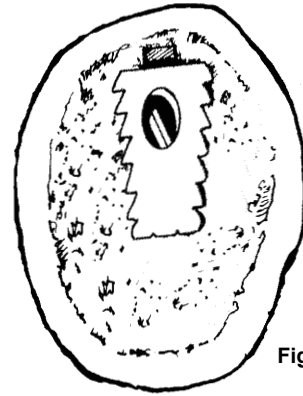


Figure 78a

NEUTRAL


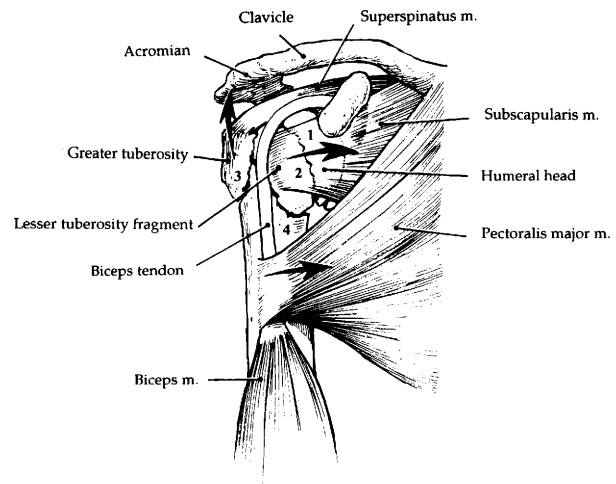


Figure 78b

## Four-Part Fracture Management

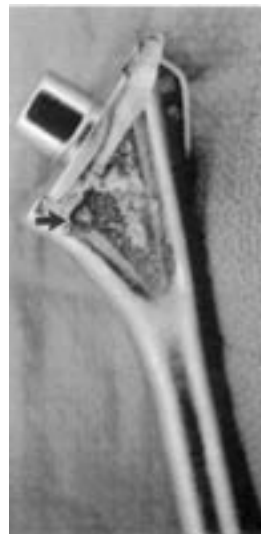
Operative management of four-part fractures (Figure 79) is facilitated by use of the Select Shoulder System for several reasons.

- Medial and lateral suture sites provide circular fixation through the prosthesis, providing a more stable construct for reuniting the exposed tuberosities.
- Modularity allows reconstruction of the tuberosities and soft tissues while the head is still off, providing for anatomic reconstruction.
- One proximal fin provides ease and simplicity during cerclage of the tuberosities around the proximal body in fracture reconstruction.
- Trapezoidal-shaped proximal body with CSTi porous-coated patches provides large surface area for ideal fixation of the tuberosities, increasing the surface area for healing.

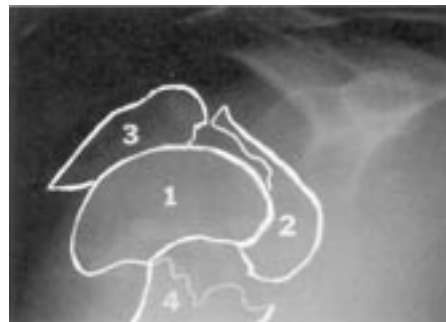

**Figure 79**

Muscle forces determine the direction of displacement of the bony fragments of the four-part fracture. The subscapularis pulls the lesser tuberosity medially. The greater tuberosity is pulled superiorly, medially, and posteriorly under the acromion. The pectoralis major pulls the humeral shaft medially and the humeral head, devoid of its soft tissue, rolls out laterally.



Retrieved specimen illustrates the medial suture hole as well as the porous-coated portion of the prosthesis in the region where the tuberosities were repaired.



Typical four-part fracture. Fragments enhanced for reproduction.

## Patient Positioning

The patient is induced under general endotracheal or scalene block anesthesia depending on the patient's surgeons, and anesthesiologist's preference and placed in the "beach chair" position (Figure 80).

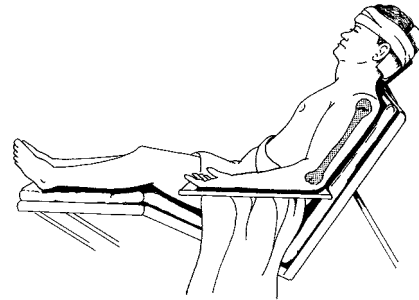


Figure 80

It is important to have the patient's body brought as far laterally as possible on the operating table so that the shoulder can be extended and the humeral shaft reamed in a vertical fashion (Figure 81). Place several folded towels behind the patient's scapula to facilitate glenohumeral extension. Prepare and drape the wound with a ten minute Betadine preparation. Administer prophylactic antibiotics.

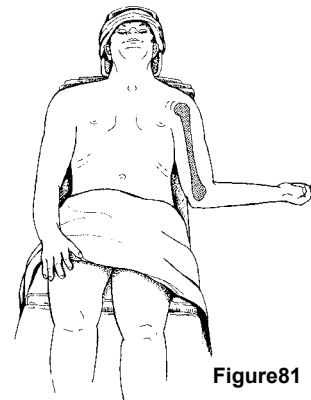


Figure 81

## Surgical Technique

The standard long deltopectoral approach is utilized (Figure 82).

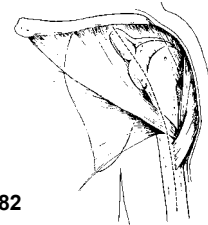


Figure 82

Incise the upper portion of the pectoralis major tendon (Figure 83).

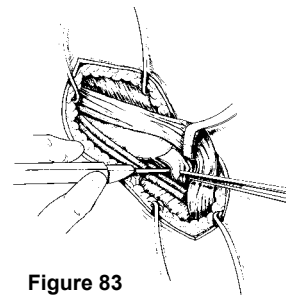


Figure 83

The clavipectoral fascia bulges with the fracture hematoma that is released when this layer is incised (Figure 84).

The biceps tendon is a useful landmark when reconstructing four-part fractures, especially if the patient presents late for surgery. The biceps tendon is traced into the fracture site and the tuberosity fragments are located. This is facilitated by opening the rotator interval all the way to the glenoid rim. Because of the pull of the supraspinatus, the greater tuberosity will be found underneath the acromion and posterior to the head fragment because of the pull of the infraspinatus. This deformity must be corrected if full external rotation is to be achieved.

The lesser tuberosity can be retracted underneath the conjoined tendon by the pull of the subscapularis. The humeral head is angulated in a valgus position and can sometimes point directly opposite to the glenoid (lateral dislocation). The humeral shaft is usually in a more medial position, pulled by the unobstructed action of the pectoralis major.

The humeral head is removed and saved for possible bone graft. The fragment is measured and the corresponding color-coded humeral head trial is selected. The humeral head trial will be utilized later in the procedure.

The rotator cuff is mobilized by placing Darrach retractors on the bursal side. Capsulolabral incision as well as periosteal dissection of the capsule is performed. These maneuvers combined with release of the coracohumeral ligament allow the surgeon to gain the length required to repair the tuberosities without tension.

The tuberosities are prepared with drill holes for suture placement, two in the vertical and two in the transverse plane, creating a cruciate-type construction (Figure 85). This cruciate-suture construction will later be taken through the medial and lateral suture holes of the prosthesis to force the tuberosities onto the flat porous-coated area.

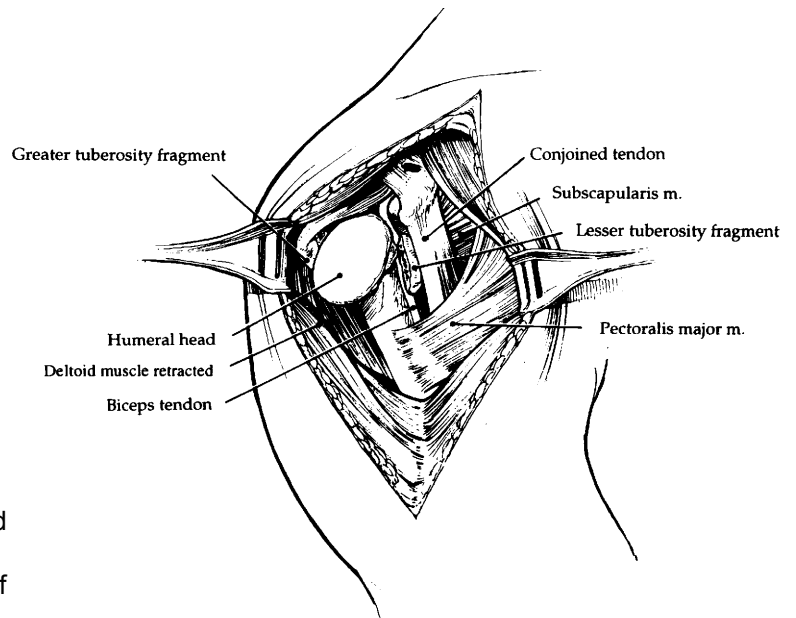


Figure 84

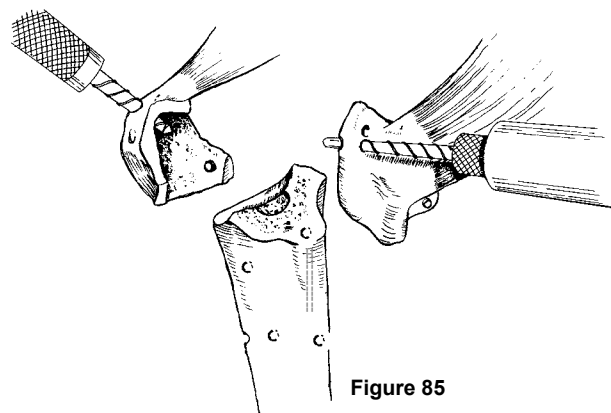


Figure 85

Drill holes must also be made in the shaft of the humerus anteriorly and posteriorly, for further fixation with Dacron Sutures (Figure 86).

The humeral shaft is held with bone-holding forceps and reamed sequentially, starting with a 7mm humeral reamer. Because the tuberosities are not present, it is important to find the old bicipital groove to insure placement of the humeral component in the proper degree of retroversion.

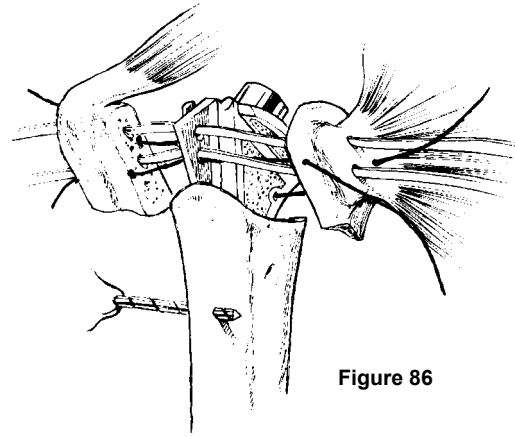


Figure 86

The biceps tendon subtends the normal retroversion angle, and if the fin of the broach is placed just posterior to the bicipital groove (Figure 87), the patient's own retroversion angle is generally recreated.

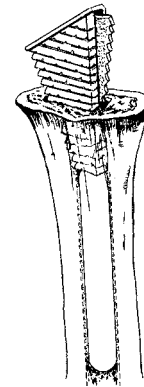


Figure 87

The tuberosities can be closed, with forceps, around the proximal bone to mold to the proximal shape. A broach is attached to the broach holder (Figure 88). The broach is set proud on the humeral shaft with the fin aligned just posterior to the bicipital groove. The broach is impacted in a rasp-like manner cutting a trapezoidal-shaped channel for the fin as well.

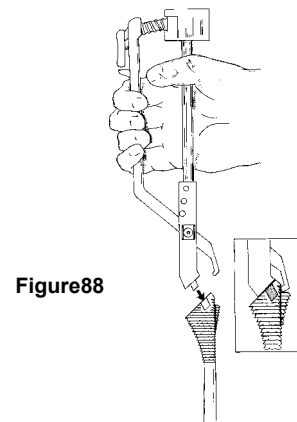


Figure 88

The broach holder is disengaged, leaving the broach in the canal, and an appropriately-sized metal humeral head trial is snapped onto the broach for trial reduction (Figure 89).

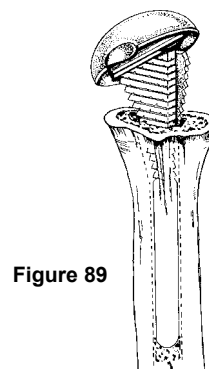


Figure 89

Any gaps should be filled with bone graft from the humeral head. At this time, the overall height of the component and version can be judged before selection of the final head. Once the version and overall height are determined, use a Bovie to mark the fin position on the bone and mark the broach at the level seated to use as a guide for the implant.

Selecting the proper height of the implant can be attained by several guidelines.

- Preoperative templating of the fractured and normal humerus.
- Size identification of removed head and neck fragments.
- Push-Pull test during broach and final trial reduction to ensure that inferior subluxation does not occur.
- Verification of tension on the biceps in its anatomic position as well as overall deltoid tension.
- Verification through ease of tuberosity reduction.

The trial head and broach are removed after reduction. Prior to cementing the humeral stem implant, strands of the Dacron suture previously placed in the shaft of the humerus are brought through the holes in the lateral fin and through the medial hole of the humeral prosthesis. The humeral canal is then injected with cement in a semi-liquid state with a glue gun under pressure with the canal plugged using a commercially available polyethylene plug or a piece of bone.

The appropriate-sized humeral component is attached to the implant holder and is impacted into place. The fin of the prosthesis is lined up with the channel cut by the fin of the broach and the retroversion mark made previously. Care is taken to remove the cement from the most proximal aspect of the shaft of the humerus with a curette to avoid the exothermic affect of the cement on the bone in the regions where the tuberosities must heal. Detach the implant holder from the implant.

A final trial reduction with the color-coded implant trial heads is performed, with the tuberosities gently pulled down to the prosthesis to check for rotator cuff tension, range of motion and stability.

Once the final head size is determined, any soft tissue or cement which may interfere with the taper lock is removed from the taper. Dry the taper. Impact the humeral head implant using the humeral head impactor.

The suture that has been placed through the shaft is then brought through the tuberosities as well or alternatively can be used as a combined tension band and rotator interval closure stitch. The medial suture from the greater tuberosity is passed through the medial suture hole (Figure 90).

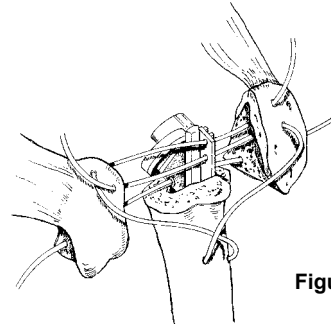


Figure 90

The lateral suture and the inferior and superior sutures are placed through the fin holes (Figure 91). The cruciate suture construction is then sutured down, pressing the tuberosities closely to the porous-coated portion of the prosthesis and any intervening bone graft. This provides both horizontal and vertical fracture stability.

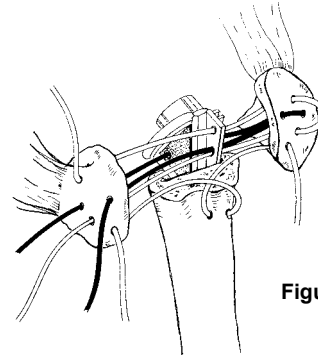


Figure 91

The Dacron suture from the humeral shaft that has been placed through the tuberosities is then used as a “baseball stitch” to close the rotator interval (Figure 92). A suction drain is used deep to the deltopectoral interval. The deltopectoral interval is tacked back together and then a standard wound closure is performed.

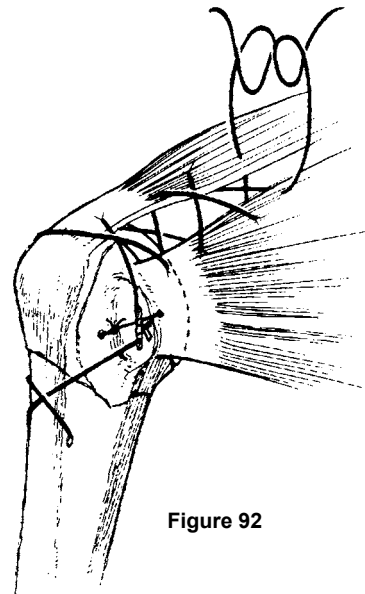


Figure 92



## Postoperative Rehabilitation

A successful outcome following total shoulder replacement is maximized through patient selection. A patient who is unable or unwilling to undergo vigorous postoperative rehabilitation is probably not a suitable candidate for total shoulder replacement.

The specific postoperative rehabilitation depends on the nature of the pathologic findings encountered, the goals of the surgeon and patient, and the successful resolution of many intraoperative variables that are present with shoulder replacement. Early on, the immediate aim is to maintain the motion achieved in the operating room following bone and soft tissue reconstruction by preventing adhesions in both the Subacromial and glenohumeral joint spaces. Care must be taken not to injure soft tissues that have been repaired or reconstructed.

The operating surgeon must take the initiative and direction in rehabilitation. Early phases of rehabilitation should establish range of motion. Strengthening exercises should be added later on to assist in muscle rehabilitation. Timing and progress of rehabilitation must be individualized. It is particularly important that patient progress be monitored closely, as many patients lack the confidence or understanding to carry on with the program by themselves.

### Patient Rehabilitation for Total Shoulder Arthroplasty

Initial postoperative care should include careful neurovascular examination, taking the patient's elbow out of a flexed position and allowing the patient to straighten the hand and elbow, thus avoiding pressure on the neurovascular structures in those areas.

Merely straightening out the elbow in the immediate postoperative period will frequently alleviate a great deal of the severe pain in the shoulder. The patient should be encouraged to take the elbow out of the immobilizer several times during the day and to begin moving the elbow and hand on the first postoperative day.

Pendulum exercises may be begun as soon as the drain is removed, generally on the second postoperative day. Early passive flexion with the patient using the opposite hand or pulley system is generally begun on the third day.

Because hospital stays tend now to be relatively short, it is generally not possible to achieve Dr. Neer's initial goals in Phase I with the hospitalized

patient. The patient is usually kept in the hospital three to five days and instructed on a home exercise program, then followed closely over the next several weeks in the office to ensure slow, gradual improvement occurs.

Specific physical therapy is left up to the discretion of the physician. It can be valuable for the operating surgeon to teach the patient the exercises personally and follow the patient's progress in the office. Physical therapists who participate routinely in the care of shoulder arthroplasty patients may be utilized also.

Occasionally, with severe associated cuff disease and repair, an abduction brace is required and generally worn for four to six weeks.

Rehabilitation following total shoulder replacement should be followed for a minimum of one year. The following is a typical rehabilitation program performed five times daily for 15 minutes to 20 minutes each session. Such a program is intended for a patient with osteoarthritis, in which the deltoid and rotator cuff are normal and the only muscle detached and repaired is the subscapularis.

**1 - Day of Surgery:** passive flexion and extension of the elbow and passive motion begun by physical therapist or continuous passive motion machine, concentrating on forward elevation and external rotation.

**2 - Postoperative Day 1:** passive forward elevation and external rotation continued.

**3 - Postoperative Day 2:** patient assisted range of motion with Codman pendulum exercises, forward elevation using pulley and supine external rotation with cane.

**4 - Postoperative Day 3:** assisted extension begun.

**5 - Days 10 to 14:** isometric external rotation and deltoid exercise begun.

**6 - Postoperative Week 4:** resistive exercises for anterior and middle deltoid. Supraspinatus, infraspinatus and teres minor begun.

**7 - Postoperative Week 6:** active internal rotation begun; initially isometric, followed by added resistance.

**8 - Postoperative 3 Months:** late stretching for forward elevation, external rotation, internal rotation and further resistive exercises.

In a patient with severe soft-tissue deficit, such as a cuff tear arthropathy or some rheumatoid arthritis, the program might be modified as follows:

- 1 - Day of Surgery:** elbow passive range of motion.
- 2 - Postoperative Day 1:** continue elbow, wrist and hand range of motion.
- 3 - Postoperative Day 5:** gentle therapist-initiated passive forward elevation, external rotation begun. A family member may be instructed in passive range-of-motion techniques before hospital discharge, so this protected rehabilitation can be continued at home. Occasionally, the soft tissue may need to be rehabilitated from a brace postoperatively.
- 4 - Postoperative Week 4:** transition to patient-initiated assistive forward elevation with a pulley, supine external rotation with a cane and internal rotation.
- 5 - Postoperative Week 6:** isometric deltoid, external and internal rotation strengthening.
- 6 - Postoperative Week 12:** resistive external exercises added.

## **Patient Rehabilitation for Four-Part Fractures**

Postoperative care of the patient with a four-part fracture must be individualized based on the quality of bone and security of the surgical construct obtained in the operating room. In general, I immobilize these patients longer than for a standard total shoulder arthroplasty, keeping them in a sling for approximately three weeks. During this time there is enough soft tissue healing to allow safe, gentle passive range-of-motion, pendulum and pulley exercises. Active use of the arm is not permitted prior to six weeks to ensure tuberosity healing. Specific stretching and strengthening is avoided for approximately three months. Patients tend to improve in their range-of-motion and strength for at least 18 months and up to two years following this surgical procedure.

The following is a typical rehabilitation program for a patient with a four-part fracture:

### **1 - 3 Weeks:**

Patient is immobilized with a sling.

### **4 - 6 Weeks:**

Safe, gentle passive range-of-motion with Codman pendulum exercises, forward elevation using pulley.

### **7 Weeks to 3 Months:**

Assisted extension.

### **4 Months to 12 Months:**

Isometric deltoid, external and internal rotation strengthening. Late stretching for forward elevation, external rotation, internal rotation and further resistive exercises.

**Zimmer Inc.**

9900 Spectrum Drive  
Austin, Texas 78717

512.432.9900  
877.768.7349  
fax: 512.432.9014



**zimmer**  
*Confidence in your hands™*

1000-03-104 Rev. covers 1/2004  
© 2004 Zimmer Inc.  
All rights reserved.

**Knees**

- Apollo® Knee System  
Classic condylar knee replacement system
- Durasul® Tribological System  
Highly crosslinked polyethylene that resists wear and aging
- Natural-Knee® System  
Anatomic design for superior clinical results
- UniSpacer™ Knee System  
No bone cuts. No compromises.

**Severe Revision/Limb Salvage**

- MOST Options™ System  
Modular knee and hip options for severe bone loss, trauma and revision

**Hips**

- Alloclassic® (Zweymüller™) Hip  
Classic proven design with superior clinical results
- Allofit™ Acetabular Cup System  
Unique Ridglock™ surface designed for easy implantation and stability
- Apollo® Hip System  
Designed for optimal results with low-demand patients
- APR® Anatomical Hip System  
The anatomic solution for patient matching
- CLS™ (Spotorno™) Hip System  
The standard of proximal press-fit design
- Converge® CSTI™ Porous Acetabular Cup System  
Where technology and experience meet
- Durasul® Tribological System  
Highly crosslinked polyethylene that resists wear and aging
- FracSure™ Hip System  
A classic design for hip fractures
- Metasul® Metal-on-Metal Acetabular System  
Over 15 years of clinical results & 200,000 implantations worldwide
- MS-30™ Hip  
A highly polished cemented stem
- Natural-Hip™ System  
A comprehensive system with a natural approach
- Precedent™ Revision Hip System  
A better solution for revision hips
- SL Revision™ Hip System  
A stable revision design with extensive sizes

**Upper Extremities**

- Anatomical™ Shoulder System  
Multiple adjustments of inclination & retroversion with the potential for precisely restored anatomy
- GSB® Elbow System  
A nonconstrained design with 21 years of clinical results
- Select® Shoulder System  
TSA and fracture management with offset head options