

<b>TABLE OF CONTENTS</b>		pages
<b>SURGICAL TECHNIQUE</b>		1
1	RADIOLOGICAL ASSESSMENT	1
2	PATIENT POSITIONING	1
3	DELTO-PECTORAL APPROACH	2
4	HUMERAL HEAD OSTEOTOMY	6
5	CHOICE OF HUMERAL INCLINATION AND RETROVERSION	7
6	TRIAL HUMERAL IMPLANT POSITIONING AND CHOICE OF HUMERAL HEAD OFFSET	11
7	HUMERAL IMPLANT POSITIONING	15
8	CEMENTING THE HUMERAL IMPLANT	17
9	REDUCTION OF THE PROSTHESIS-CLOSURE	17
<b>POST-OPERATIVE REHABILITATION</b>		18

# SURGICAL TECHNIQUE

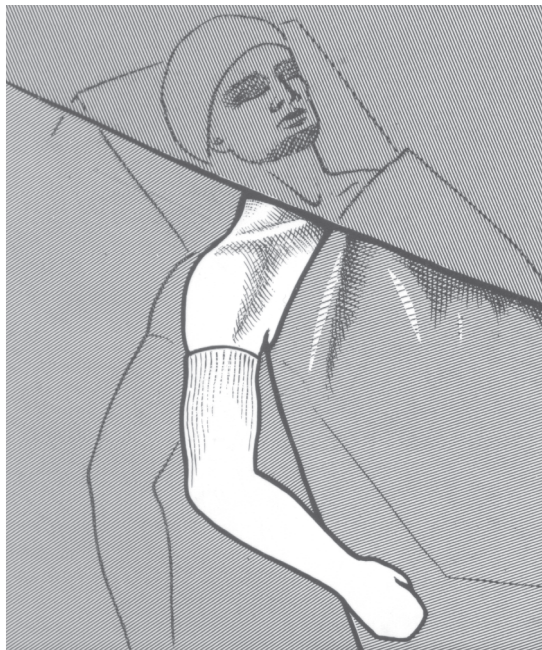## 1 - A DETAILED RADIOLOGICAL ASSESSMENT WILL ASSIST AND IMPROVE SURGERY

We suggest :

- three plain shoulder A-P x-rays : neutral, internal rotation, external rotation.
- arthrography with contrast to confirm integrity of the rotator cuff.
- a computerized tomography to assess gleno-humeral osteophytes, and the shape of the glenoid.

## 2 - PATIENT POSITIONING

General anaesthesia, beach chair position. (fig. 1)



(fig. 1)

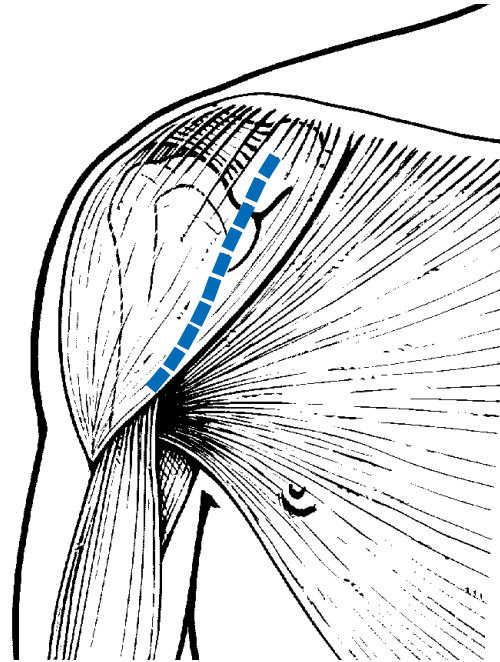
*The whole arm is draped free  
and prepared under sterile conditions.*

---

### 3 - DELTO-PECTORAL APPROACH

**An incision** is made from the tip of the coracoid along the delto-pectoral groove, slightly laterally to avoid post-operative scars in the axillary folds (fig. 2).

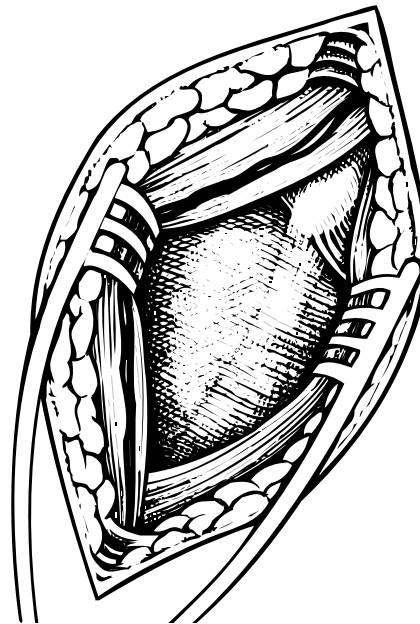
(fig. 2)



**The incision is deepened**, pectoralis major identified and the deltoid and cephalic vein are retracted laterally to open the delto-pectoral groove (fig. 3).

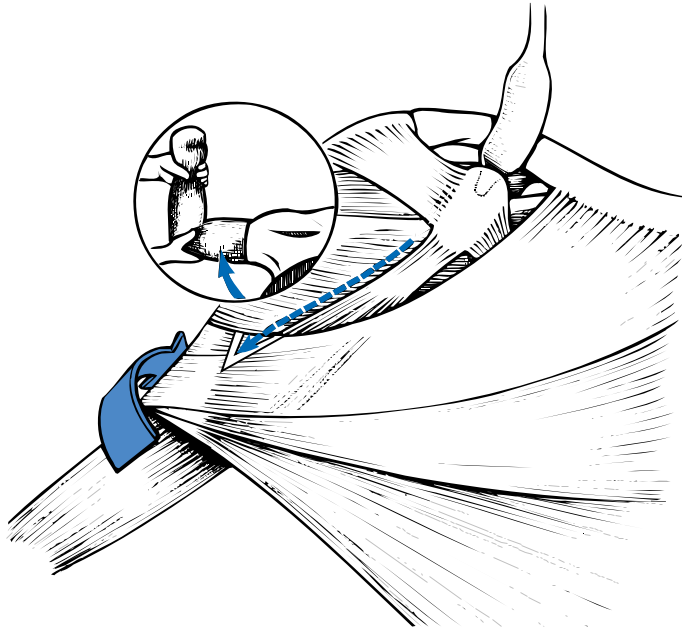
(fig. 3)

*The deltopectoral groove is opened inferiorly as far as the insertion of pectoralis major, preserving the deltoid insertion.*



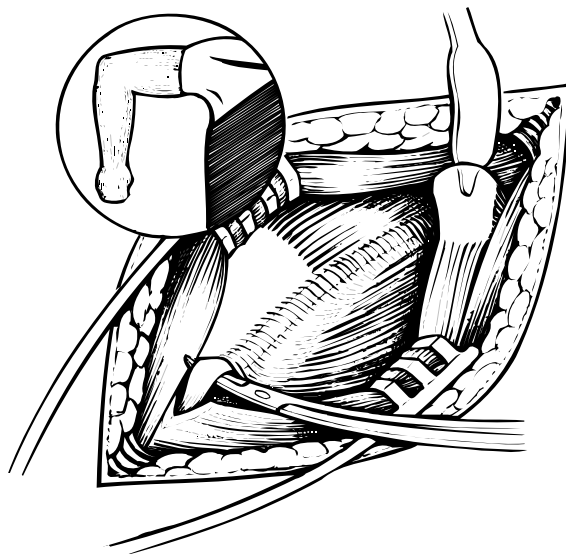
---

**The upper border of the subscapularis is identified**, after partial or total division the coracoacromial ligament at the edge of the coracoid and incision of the clavi-pectoral fascia at the lateral border of the conjoined tendon of the coraco brachialis and short head of the biceps brachii muscles (fig. 4).



(fig. 4)  
*Arm in abduction, rotated externally with an angled retractor placed above the coracoid process.*

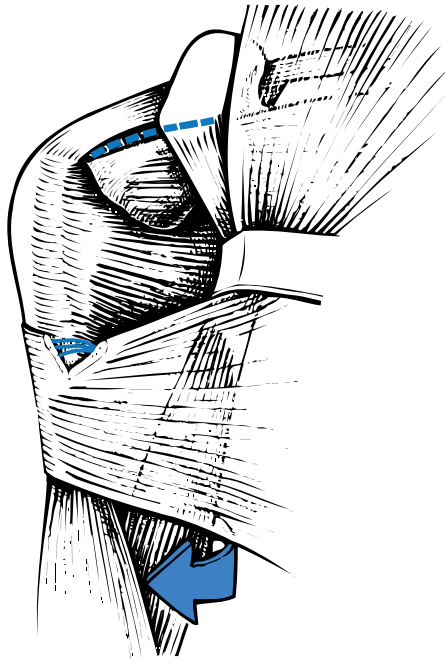
- *The external limit of the subscapularis insertion lies medial to the bicipital groove which should be identified (fig. 5)*



(fig. 5)  
*Arm abducted and rotated internally.  
The long head of biceps is exposed in the lower part of the incision above the tendon of pectoralis major which occasionally needs to be sectioned for 1 or 2 cms.*

- 
- *The upper limit of tendon of subscapularis*, which is often covered by an extension of the subcoracoid serous bursa, lies immediately below the tip of the coracoid process (fig. 6).
  - *Its inferior border* is defined by the anterior circumflex vessels.

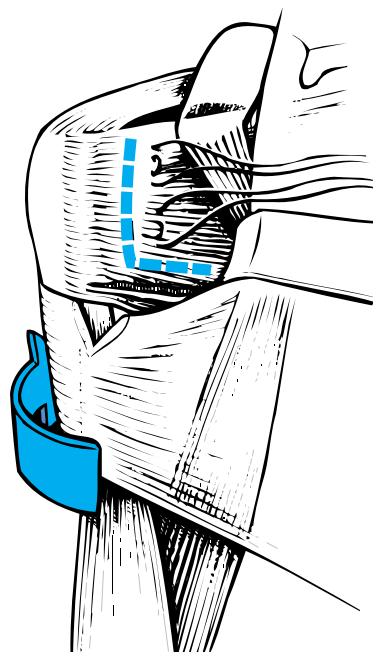
(fig. 6)  
*Arm externally rotated ,  
elbow towards the body.  
The coraco-humeral ligament  
marks the upper border  
of subscapularis ;  
the lower border is defined  
by the anterior circumflex vessels.*



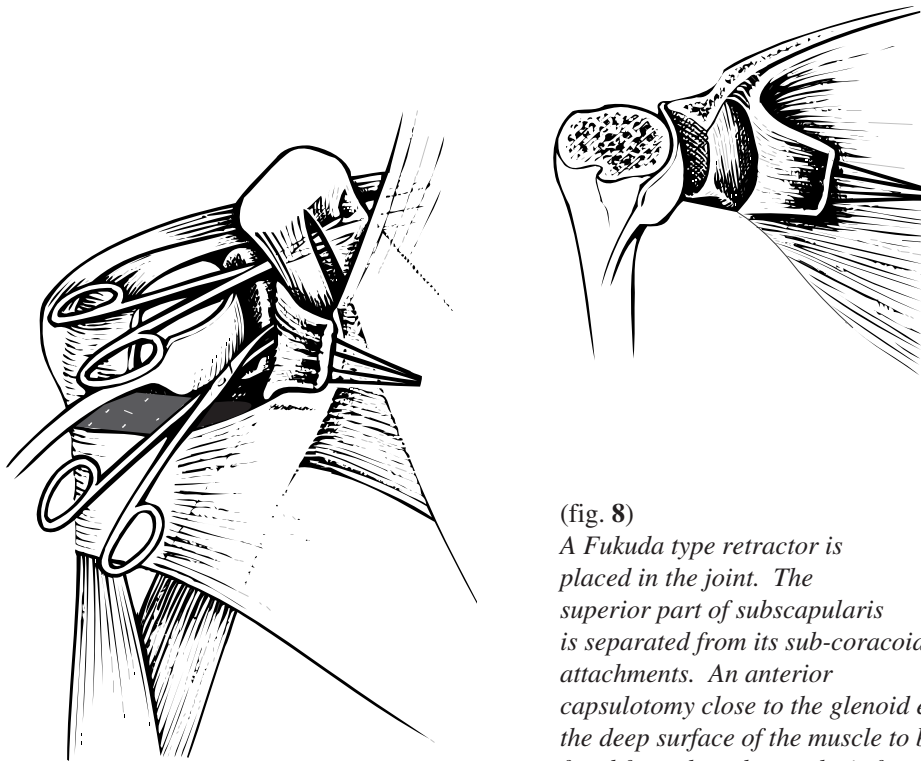
### SECTION OF SUBSCAPULARIS

Two holding stitches are passed through the subscapularis muscle after superior arthrotomy. The subscapularis tendon is then incised with the joint capsule one and a half centimeter from the bicipital groove up to the junction between the upper three quarters and the lower quarter of the muscle (fig. 7).

(fig. 7)  
*Superior arthrotomy :  
the coraco-humeral  
ligament is preserved.*



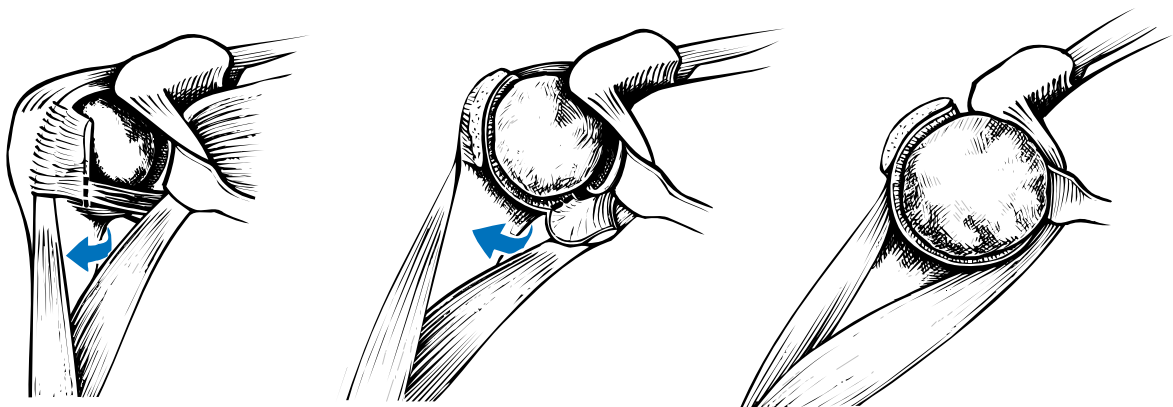
The upper three quarters of the muscle are mobilized, to produce a long flap of subscapularis which allows tension-free reinsertion following the procedure, regardless of the position of the arm (fig. 8).



(fig. 8)  
A Fukuda type retractor is placed in the joint. The superior part of subscapularis is separated from its sub-coracoid attachments. An anterior capsulotomy close to the glenoid enables the deep surface of the muscle to be freed from the subscapularis fossa.

In case of severe internal rotation contracture, a lengthening *subscapularis plasty* is always necessary in addition to anterior capsulotomy.

With the arm abducted and rotated externally, the inferior quarter of subscapularis and the remaining capsule are progressively separated from the humeral neck, avoiding damage to the axillary nerve. **The humeral head is then dislocated** anteriorly by extension with the arm abducted and rotated externally (fig. 9).

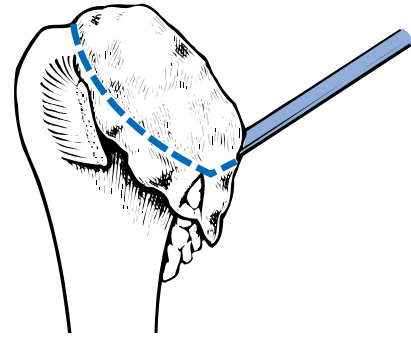
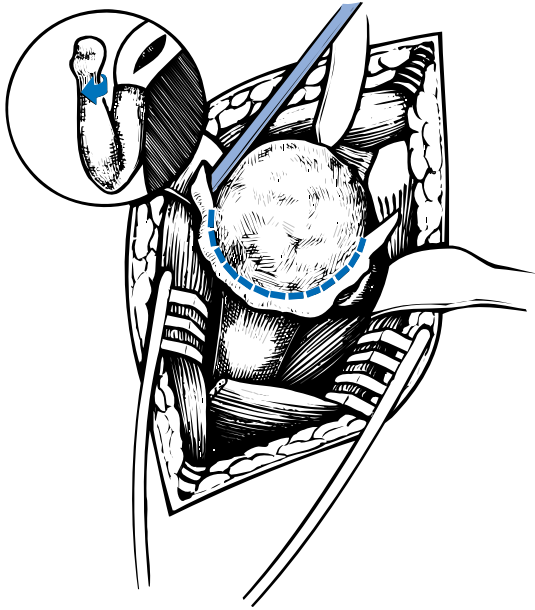


(fig. 9)  
An angled retractor is placed in the subscapularis fossa retracting conjoined tendon and subscapularis medially.

---

## 4 - HUMERAL HEAD OSTEOTOMY

The proximal part of the humerus is exposed with the arm adducted and externally rotated, and extended. **Osteophytes are trimmed away carefully** around the humeral head, guided by the radiological assessment allowing to isolate the anatomical neck (fig. 10).

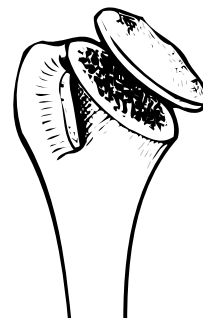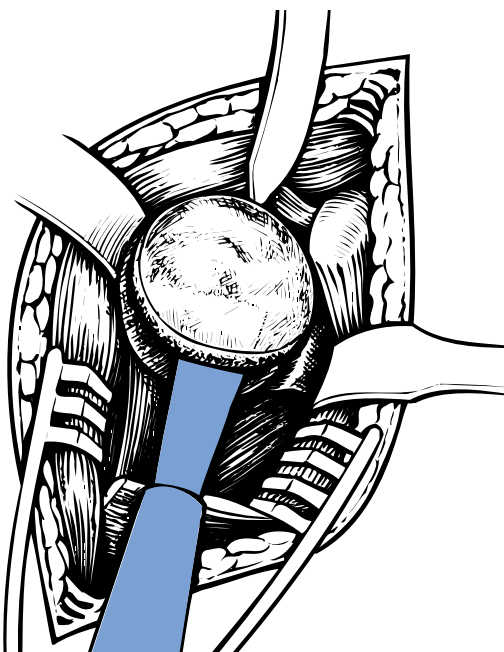


(fig. 10)

*The key point is to locate the anatomical neck by trimming away all osteophytes using an osteotome and a rongeur.*

*A cavity containing a small quantity of fat and soft tissue usually lies between cortical bone and osteophytes.*

**The humeral head is cut with an oscillating saw** exactly at the limit of the anatomical neck. Superiorly and anteriorly, the anatomical neck contains the tendon insertions of the rotator cuff (supraspinatus and subscapularis), and inferiorly it is entirely continuous with the cartilage of the head and inferior cortical surface of the humerus. Posteriorly however, there is a 6 to 8 mm area which does not contain cartilage or tendon insertions: the cut should be made through the rim of the cartilage (fig. 11).



(fig. 11)

*Once the anatomical neck has been identified, the humeral head is cut using a saw.*

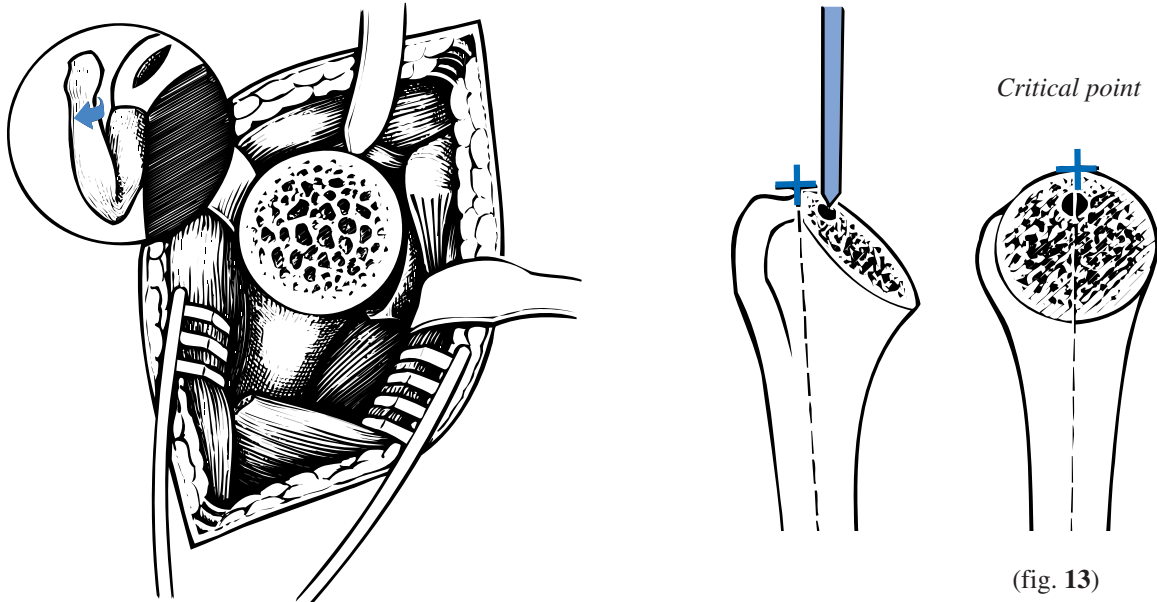
*The amount of the bone resected is usually surprisingly small.*



---

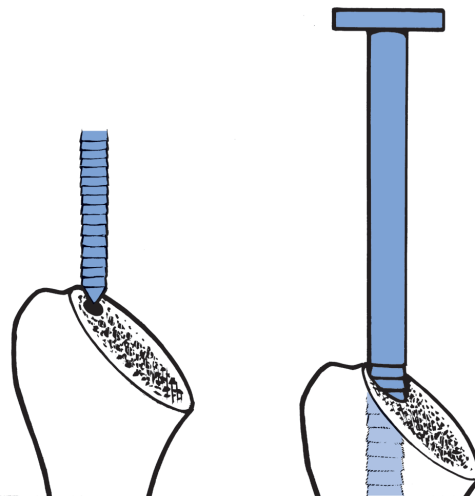
## 5 - CHOICE OF HUMERAL INCLINATION AND RETROTORSION

Accurate visualization of the plane through which the humerus is cut (fig. 12) allows the “critical point” or “hinge point” to be located. Typically, the entrance point into the humeral canal is 3 mm inwards from this point (in order not to damage the greater tuberosity). (The “critical point” is defined as the intersection of the proximal metaphyseal humeral axis and the highest point of the cut described above) (fig. 13).



(fig. 12)  
*Arm in extreme external rotation, extended, elbow towards the body (careful progressive movements in order not to cause a spiral humeral fracture)*

The humerus is reamed progressively using cylindrical reamers of increasing diameter from 6.5, 9, 12 to 15 mm, which should be advanced up to the last ridge (fig. 14).



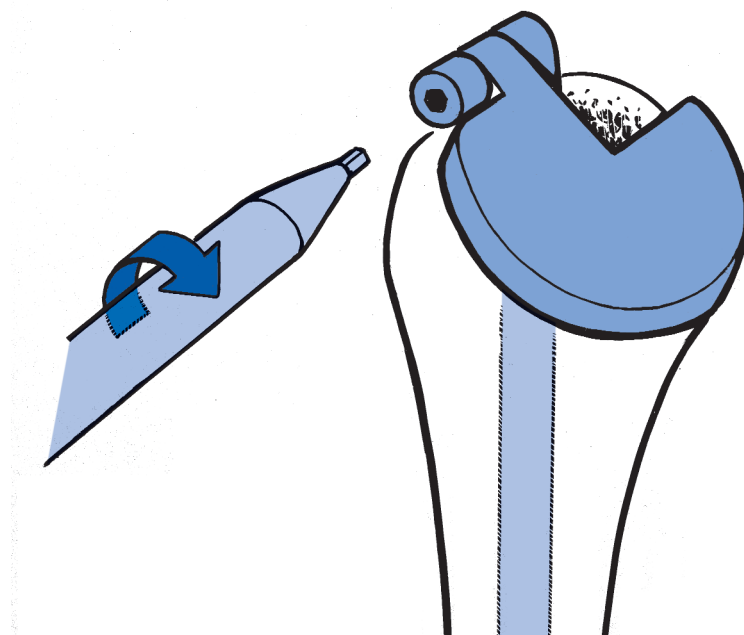
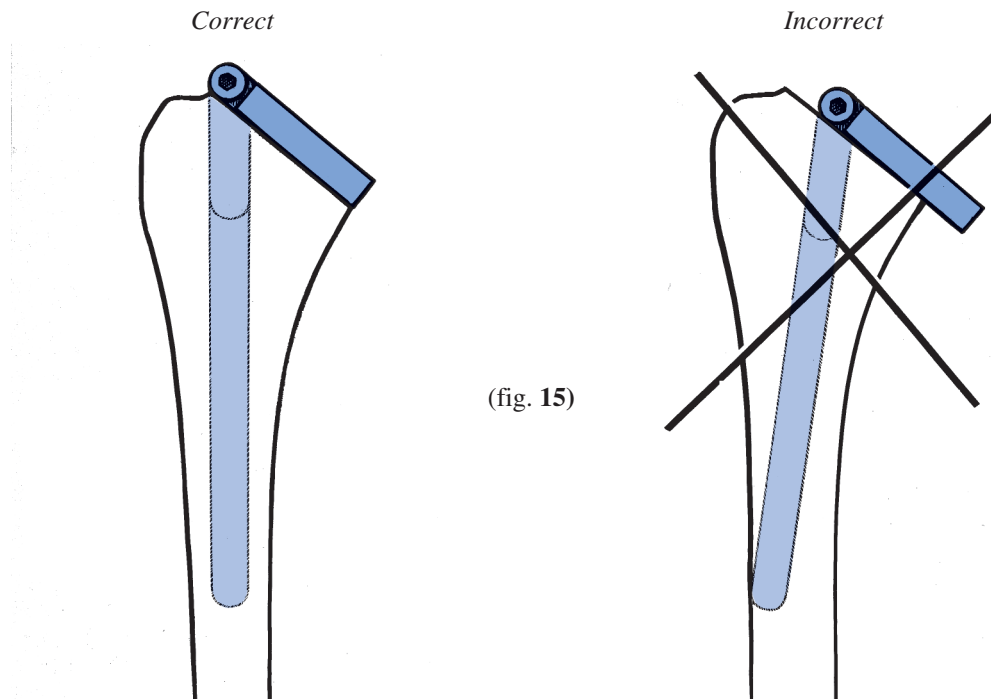
**The final reamer used will determine the diameter of the inclination guide and the humeral stem.**



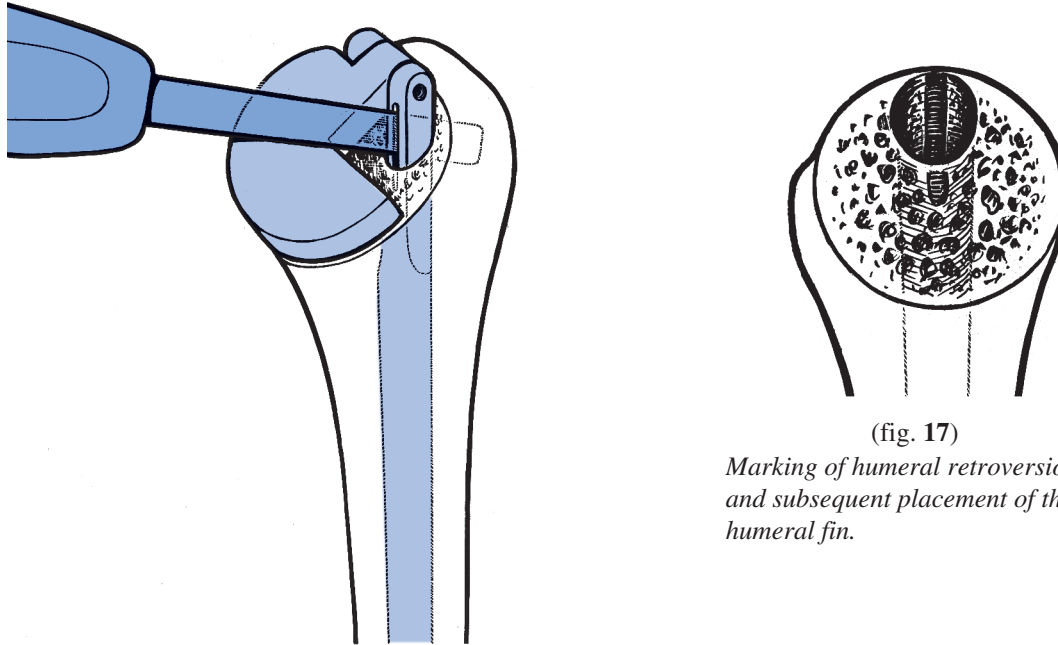
---

**The inclination of the humerus is measured using the inclination guide,** the diameter of which is determined by the final cylindrical reamer.

After introducing the shank into the humeral medullary cavity, the mobile plate is positioned correctly (letter R upwards for a right humerus, letter L upwards for a left humerus) and exactly aligned with the humeral cut (fig. 15). The tightening screw should be positioned at the 'critical point' and tightened with the 4.5 mm hexagonal screwdriver (fig. 16).



**Humeral retrotorsion** is marked with the trial neck in situ by making a slot on the cancellous tuberosity with an osteotome, in the groove designed for this purpose. This slot represents the site for subsequent positioning of the humeral fin (fig. 17).

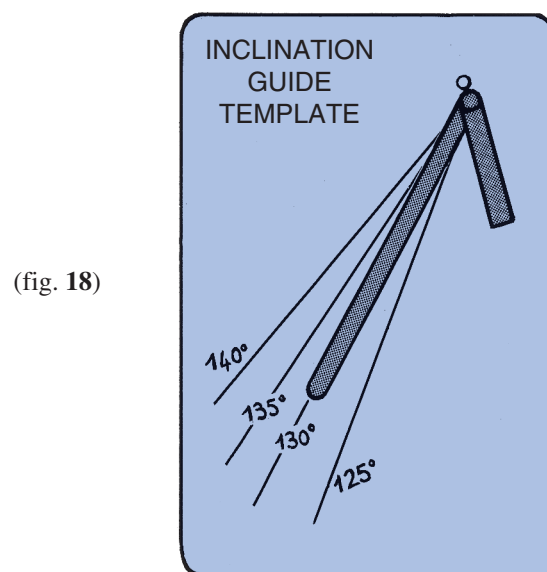


(fig. 17)

*Marking of humeral retroversion and subsequent placement of the humeral fin.*

**The plane of section of the anatomical neck therefore determines inclination and retroversion of the humerus.**

**The angle of humeral inclination** is read directly after removing the trial neck, using an inclination guide template. There are four possible angles of inclination from 125° to 140°, each provided by one of four trial neck components (fig. 18)

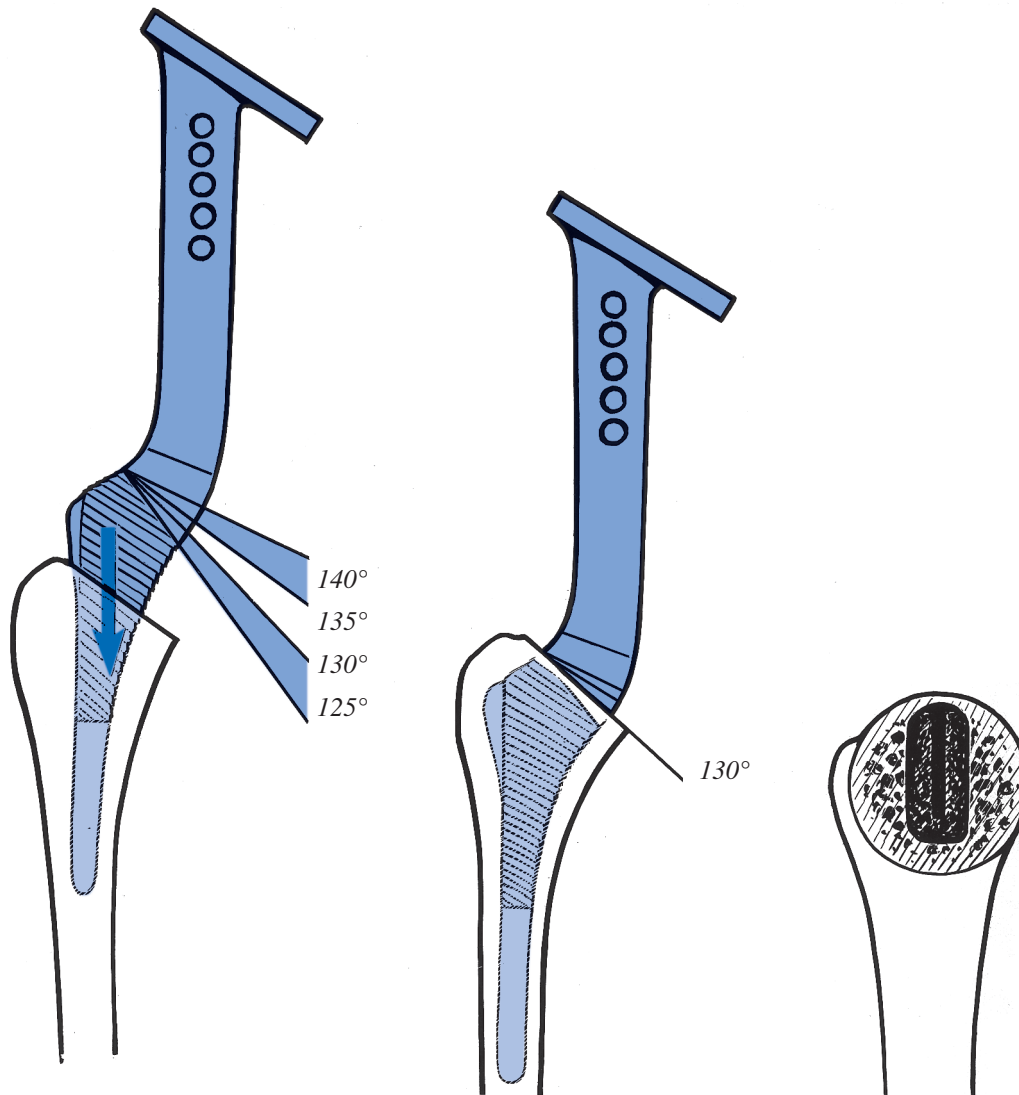


(fig. 18)

*If an angle lies between two values, the lower should be chosen for the prosthesis. If for example the angle is between 135° and 140°, the 135° prosthesis should be chosen.*

---

**Definitive broaching for the humeral stem** is performed using the corresponding broach. Retrotorsion is observed by aligning the fin of the broach with the slot created by the osteotome described above. The broach should be advanced up to its last ridge for a 125° slope, or to one of three marks for slopes of 130°, 135° or 140° (fig. 19).

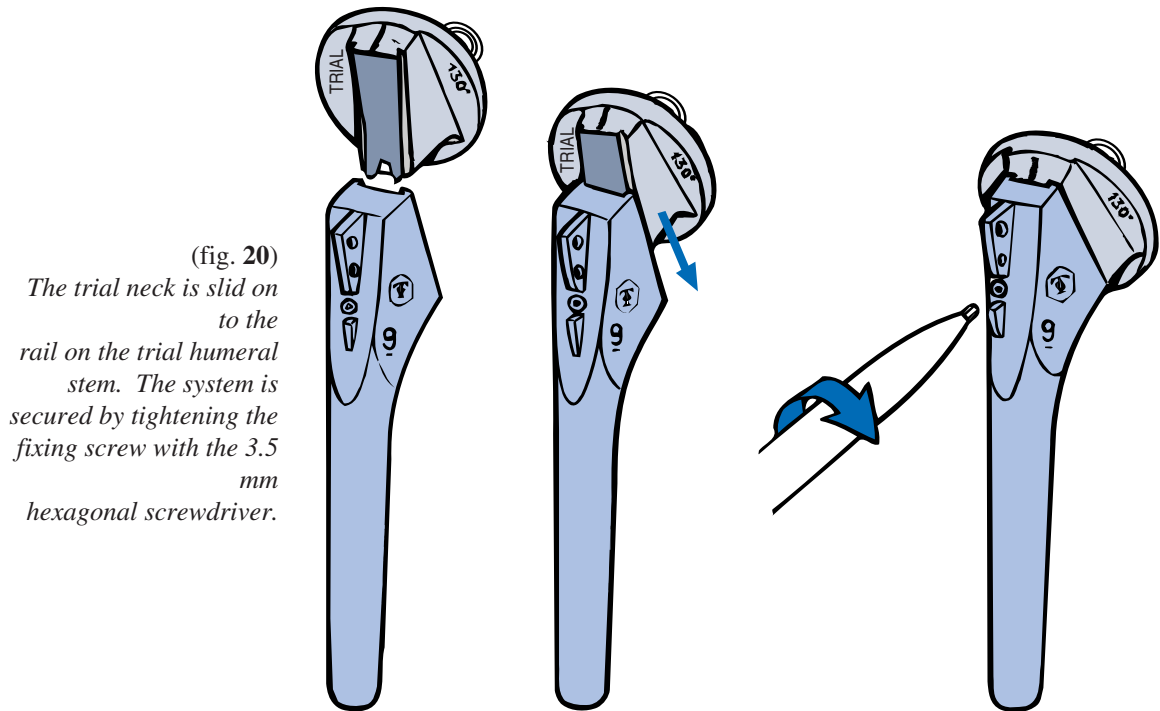


(fig. 19)  
*The broach is inserted forming the outline of the corresponding prosthetic humeral stem with respect to the previously marked retrotorsion..*

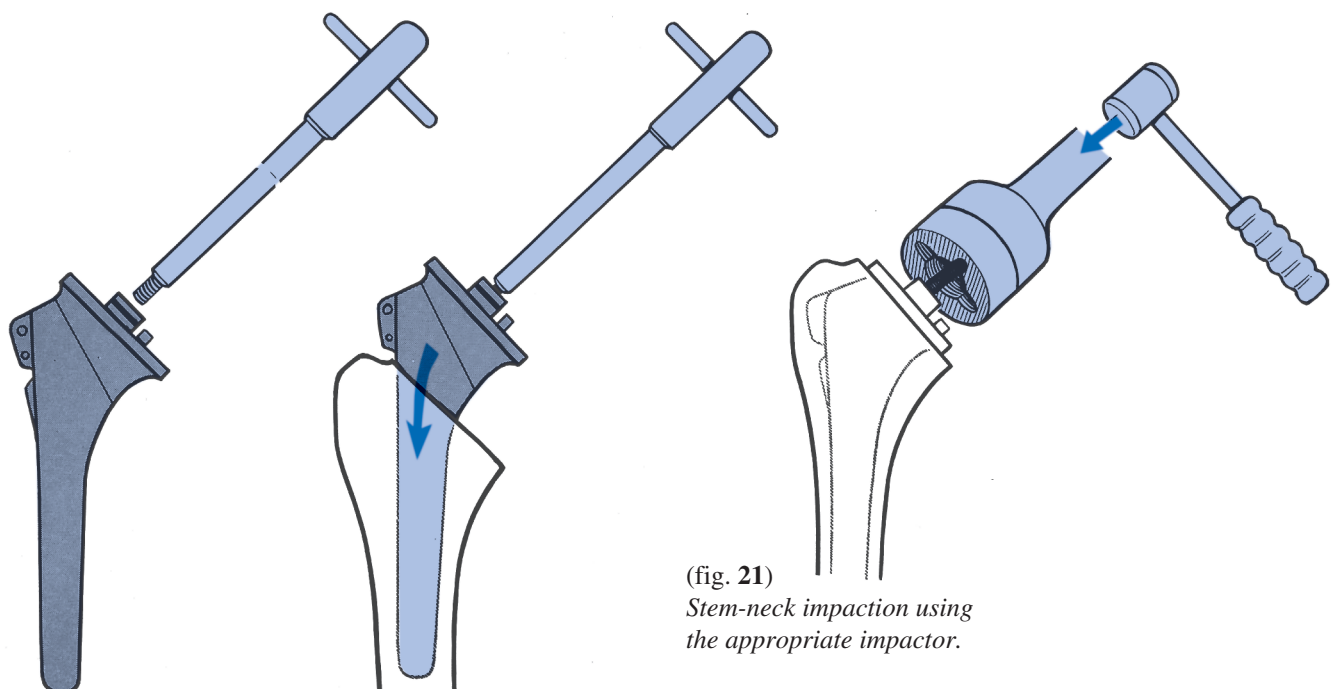
---

## 6 - TRIAL HUMERAL IMPLANT POSITIONING AND CHOICE OF HUMERAL HEAD OFFSET

The humeral trial stem and trial neck are assembled (fig. 20).



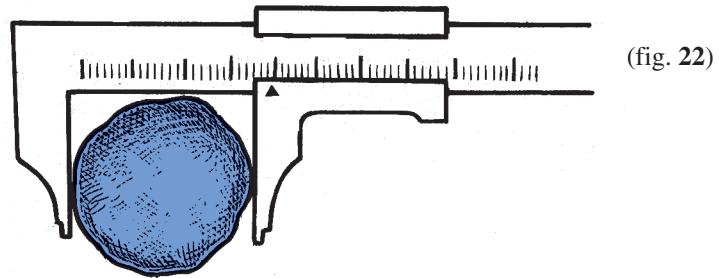
**The trial stem-neck assembled unit is introduced into the humeral shaft** using the T-handle, observing the correct position for the fin. The unit is impacted using the trial stem-neck impactor. The neck should not be forced into cancellous bone tissue (fig. 21)



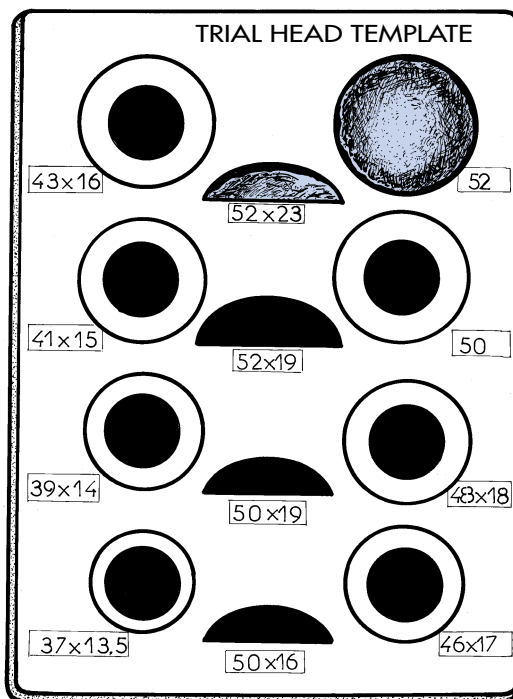
---

**DETERMINATION OF THE TRIAL HEAD SIZE :**

- either by caliper measurement of the diameter of the resected head (fig. 22).



- or on the trial head template. (fig. 23)

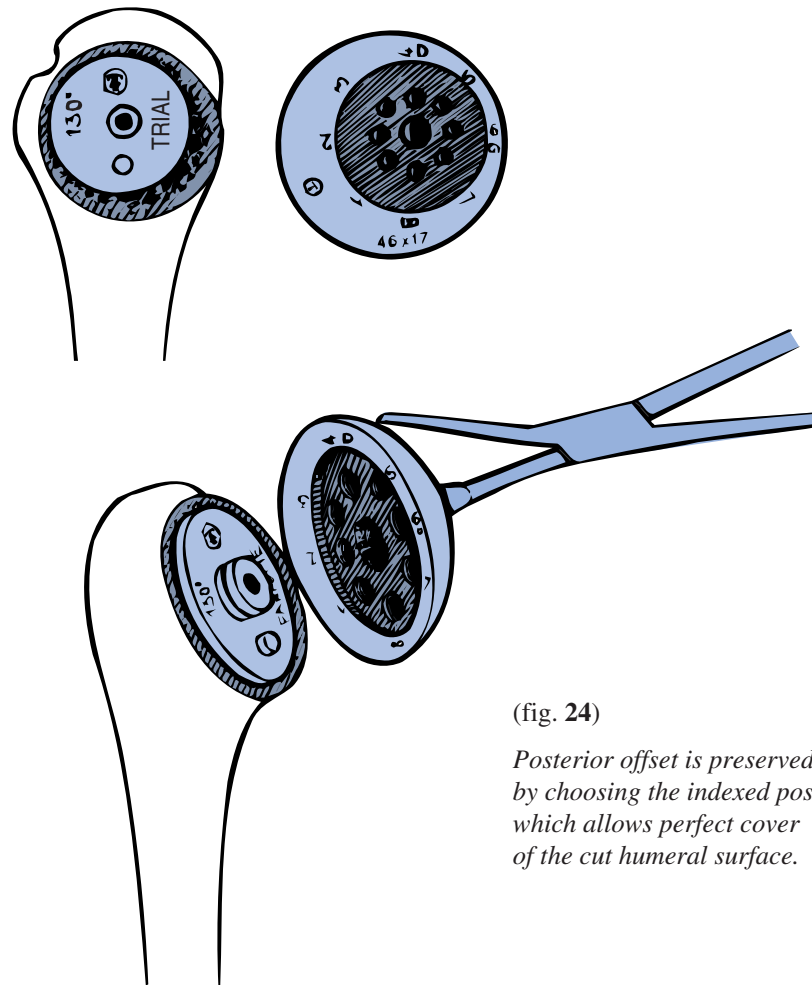


(fig. 23)  
*2 thicknesses are available  
for a 50 and 52 mm diameter  
head.*

---

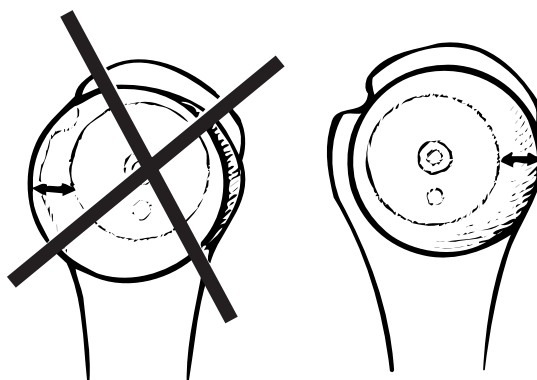
The only remaining requirement is to reproduce the articular surface offset using the original eccentric dial system.

The trial head is held with the trial head clamp and placed over the male cylindrical part of the neck. The head may be rotated eccentrically around this cylinder and the ideal position selected to cover the cut humeral neck (fig. 24).



(fig. 24)

*Posterior offset is preserved by choosing the indexed position which allows perfect cover of the cut humeral surface.*

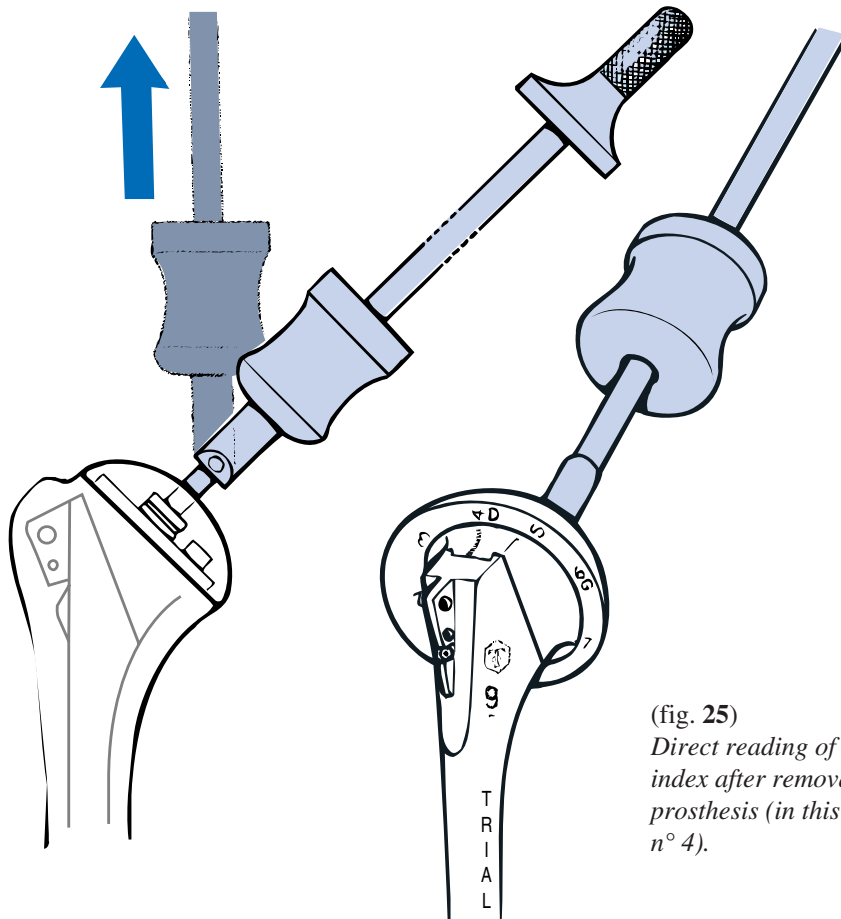


No

Yes

---

The entire trial prosthesis is then removed using the extractor-hammer. The posterior face of each trial head is marked from 1 to 8, corresponding to 8 possible index positions. **The appropriate figure is then read from the superior pole of the neck, to give the chosen anatomical index** (fig. 25).



(fig. 25)  
*Direct reading of anatomical index after removal of trial prosthesis (in this case index n° 4).*

By this stage in the procedure, the following have been defined :

- diameter of the humeral stem
- inclination angle and retrotorsion
- head size and anatomical off set

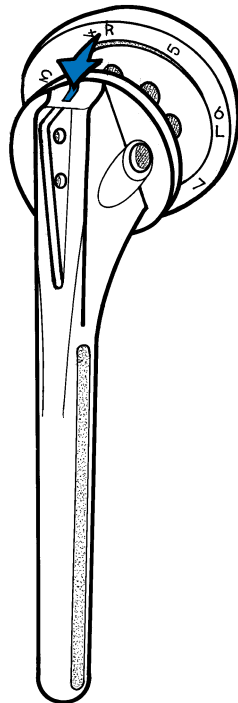


---

## 7 - HUMERAL IMPLANT POSITIONING

After removing the trial humeral prosthesis, *the definitive prosthetic parts are chosen using the predetermined parameters.*

**The head is positioned over the stem,** aligning the offset number with its position, marked on the upper border of the neck (fig. 26).

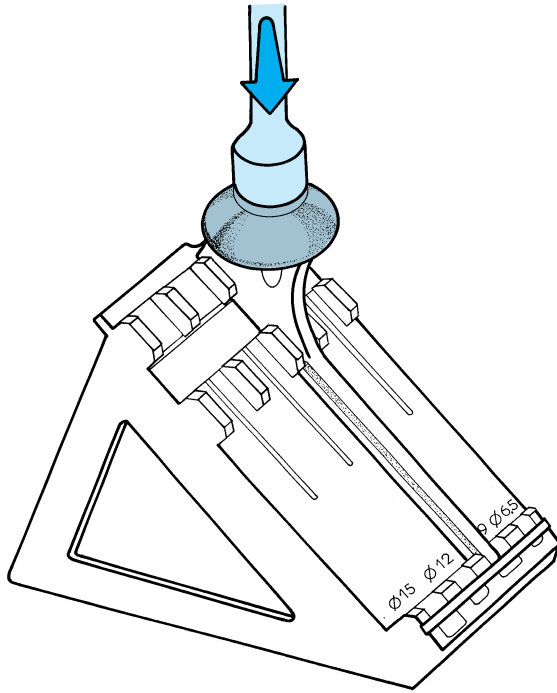


(fig. 26)

*Anatomical offset.  
This unit should be assembled  
with clean gloves in dry  
surroundings.*

---

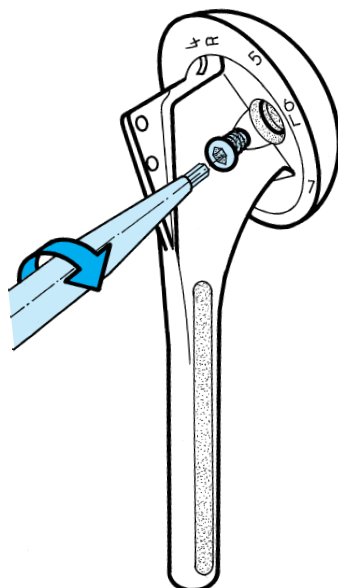
**The head is impacted onto the stem on the impaction support. (fig. 27).**



(fig. 27)  
*The impactor must be aligned with the morse taper.*

NOTE : The supplemental locking screw is provided only as an additional security. The use of this screw is at the discretion of the surgeon.

NOTE : For Total Shoulder Arthroplasty, glenoid component must be implanted prior to implanting definitive humeral prosthesis. Refer to glenoid surgical technique.



(fig. 28)  
*The head is fixed definitely to the stem by tightening the safety screw with 3.5 mm hexagonal screwdriver.*

---

## 8 - CEMENTING OF THE DEFINITIVE HUMERAL IMPLANT

Cement is injected into the canal after diaphyseal obturation and drying. The definitive humeral implant is positioned and then impacted, taking care to align the prosthetic fin with its slot in the tuberosity.

## 9 - REDUCTION OF THE PROSTHESIS - CLOSURE

After the joint has been washed and the prosthesis reduced, the stability and mobility of the shoulder are tested. The joint is closed by reinsertion of subscapularis to the coraco-humeral ligament, and to the subscapular remnant, allowing slight slipping of the subscapularis upwards. The wound is closed in planes over an aspiration drain.

*Post-operatively* the arm is immobilized in a simple sling.

# POST-OPERATIVE REHABILITATION

This is essential and is responsible for at least 50% of the final result. Rehabilitation begins on the evening of surgery by removing the sling and actively moving fingers, wrist and elbow.

The following day the patient begins active exercises of the fingers, wrist and elbow, helped by a physical therapist, 5 to 6 times daily, each for a few minutes duration.

The patient is allowed to get out of bed with his/her arm in a sling. Once the drain is removed after 48 hours, the patient is encouraged to carry out brief pendular exercises throughout the day.

The fundamental principle which guides rehabilitation, either in the operative center or as an outpatient, is maximal recovery of passive joint movement prior to any active motion. Passive elevation begins by simple pendular movements followed rapidly by self-mobilization with the patient in the dorsal decubitus position with elbow extended (and helped by inspiration through the mouth, which adds a few degrees movement with each inspiration. It is preferable to perform a single smooth motion rather than repeated jerking movements. External rotation is performed using a stick, with the elbow against the body. Internal rotation is performed with the arm behind the back, helped by the other hand wherever possible.

Rehabilitation sessions should not be more than 5 minutes long and should be performed ideally hourly throughout the day. The time required for purely passive rehabilitation varies depending on pre-operative passive mobility.

- If good pre-operative mobility was present (unfortunately relatively rare), the amplitude of movement generally recovers after 45 days and active movement may be possible. In this case a few minutes of active movement should be performed mornings and evenings “running the joint in” in a swimming pool using arm movements for 10 to 15 minutes daily for 3 months.
- If a patient was highly restricted pre-operatively (forward elevation less than 90°), it should be understood that the total shoulder prosthesis is not a mobilizing procedure. It is unlikely the patient will recover passive elevation beyond 130°. The patient should be asked to perform multiple daily passive stretching exercises and breast-stroke movement of his/her arms in a swimming pool throughout the first post-operative year, in order to obtain and maintain maximum mobility.

# INSTRUMENTS

**Trial head clamp** Ref. MWA103

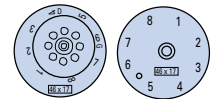


**Inclination guide clamp** Ref. MWA104



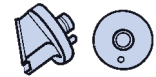## Trial head

<b>37 x 13.5</b>	Ref. MWA237	<b>48 x 18</b>	Ref. MWA248
<b>39 x 14</b>	Ref. MWA239	<b>50 x 16</b>	Ref. MWA250
<b>41 x 15</b>	Ref. MWA241	<b>50 x 19</b>	Ref. MWA251
<b>43 x 16</b>	Ref. MWA243	<b>52 x 19</b>	Ref. MWA252
<b>46 x 17</b>	Ref. MWA246	<b>52 x 23</b>	Ref. MWA253



## Trial neck

<b>125°</b>	Ref. MWA125	<b>135°</b>	Ref. MWA135
<b>130°</b>	Ref. MWA130	<b>140°</b>	Ref. MWA140



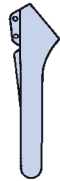
## Trial stem

**Trial stem Ø 6.5** Ref. MWA627

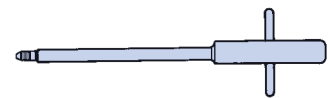
**Trial stem Ø 9** Ref. MWA629

**Trial stem Ø 12** Ref. MWA632

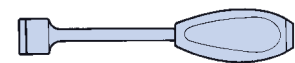
**Trial stem Ø 15** Ref. MWA635



**T. handle stem holder** Ref. MWA106



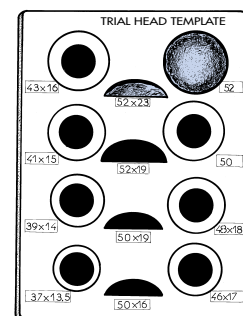
**Humeral prosthesis impactor** Ref. MWA108



**Trial stem-neck impactor** Ref. MWA109



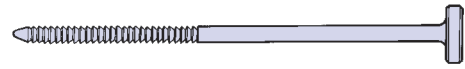**Trial head template** Ref. MWA162



# INSTRUMENTS

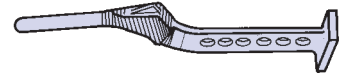## Cylindrical reamers

Ø 6.5	Ref. MWA607	Ø 12	Ref. MWA612
Ø 9	Ref. MWA609	Ø 15	Ref. MWA615



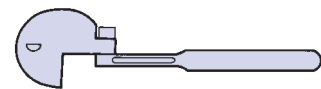
## Humeral broaches

Ø 6.5	Ref. MWA027	Ø 12	Ref. MWA032
Ø 9	Ref. MWA029	Ø 15	Ref. MWA035

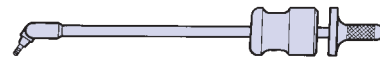

## Inclination guide

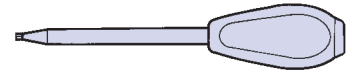
<b>Inclination guide Ø 6.5</b>	Ref. MWA617
<b>Inclination guide Ø 9</b>	Ref. MWA619
<b>Inclination guide Ø 12</b>	Ref. MWA622
<b>Inclination guide Ø 15</b>	Ref. MWA625



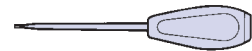
**Extractor hammer** Ref. MWA118



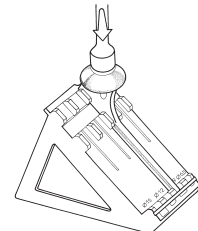
**Hexagonal screwdriver 4.5 mm (No. 1)** Ref. MWA119



**Hexagonal screwdriver 3.5 mm (No. 2)** Ref. MWA124



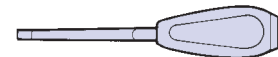
**Impaction support** Ref. MWA160



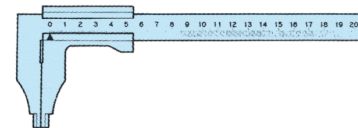
**Mallet** Ref. MWA122



**Retroversion Osteotome** Ref. MWA101



**Caliper** Ref. MWA102

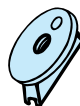

**40 cm ruler** Ref. MWA 123



## Humeral cut protector

125°	Ref. MWA 151
130°	Ref. MWA 152
135°	Ref. MWA 153
140°	Ref. MWA 154



## Extension piece

Ø 6.5	Ref. MWA 637
Ø 9	Ref. MWA 639
Ø 12	Ref. MWA 642
Ø 15	Ref. MWA 645