

Aequalis[®] Press-Fit Shoulder Prosthesis



Surgical
Technique



SURGICAL TECHNIQUE

RATIONALE OF THE AEQUALIS PRESS-FIT PROSTHESIS p. 1

THE AEQUALIS PRESS-FIT PROSTHESIS p. 2

SURGICAL TECHNIQUE p. 3 - 21

1. A detailed radiological assessment will assist in the pre-operative planning
2. Patient positioning
3. Delto-pectoral approach
4. Humeral head osteotomy
5. Reaming the humeral shaft
6. Choice of humeral inclination and retroversion
7. Metaphyseal preparation
8. Trial humeral implant positioning and choice of the humeral head offset
9. Determination of the trial head size
10. Humeral implant assembly and positioning
11. Reduction of the prosthesis and closure

INSTRUMENTS p. 22 - 24

IMPLANTS p. 26

RATIONALE OF THE AEQUALIS PRESS-FIT PROSTHESIS

Gleno humeral arthritis is characterized by persistent pain, loss of gleno humeral motion and loss of gleno humeral joint space.

Prosthetic replacement of the gleno humeral joint seeks to relieve pain and restore normal kinematics and biomechanics.

Due to the relatively fixed geometry of first and second generation shoulder prostheses, the possibilities to reproduce the normal kinematics of the gleno humeral joint are limited and often result in abnormal or reverse scapulo-humeral rhythm.

By anatomically reconstructing the proximal humerus, normal kinematics and biomechanics can be restored allowing for normal scapulo-humeral rhythm. Due to the highly variable anatomy of the proximal humerus, it is necessary to utilize a prosthesis, which takes into account the normal spherical shape of the humeral head along with the variable inclination, retroversion and combined medial and posterior offsets of the humeral head replacement in order to adapt the prosthesis to the individual patient's anatomy.

The Tornier Aequalis prosthesis is the first third generation shoulder prosthesis. It is not only modular without the gap between the collar and the head, but also adaptable to allow restoration of the patient's healthy anatomy and maintain the normal superior profile*.

The Aequalis press-fit shoulder prosthesis is specifically designed for long term stability of the humeral component. Its stepped surface geometry maximizes bone support for an optimal primary fixation and secondary fixation. The unique instrumentation allows compacting of the metaphyseal bone to give added support to the prosthesis and to prevent distal migration. Compaction grafting along the calcar increases the press-fit helping to avoid late subsidence.

The stem is available in five diameters. 7, 9, 11, 13 and 15 mm. Four neck angles of 125, 130, 135 and 140 degrees allow the humeral implant to be better adapted to the humeral resection surface.

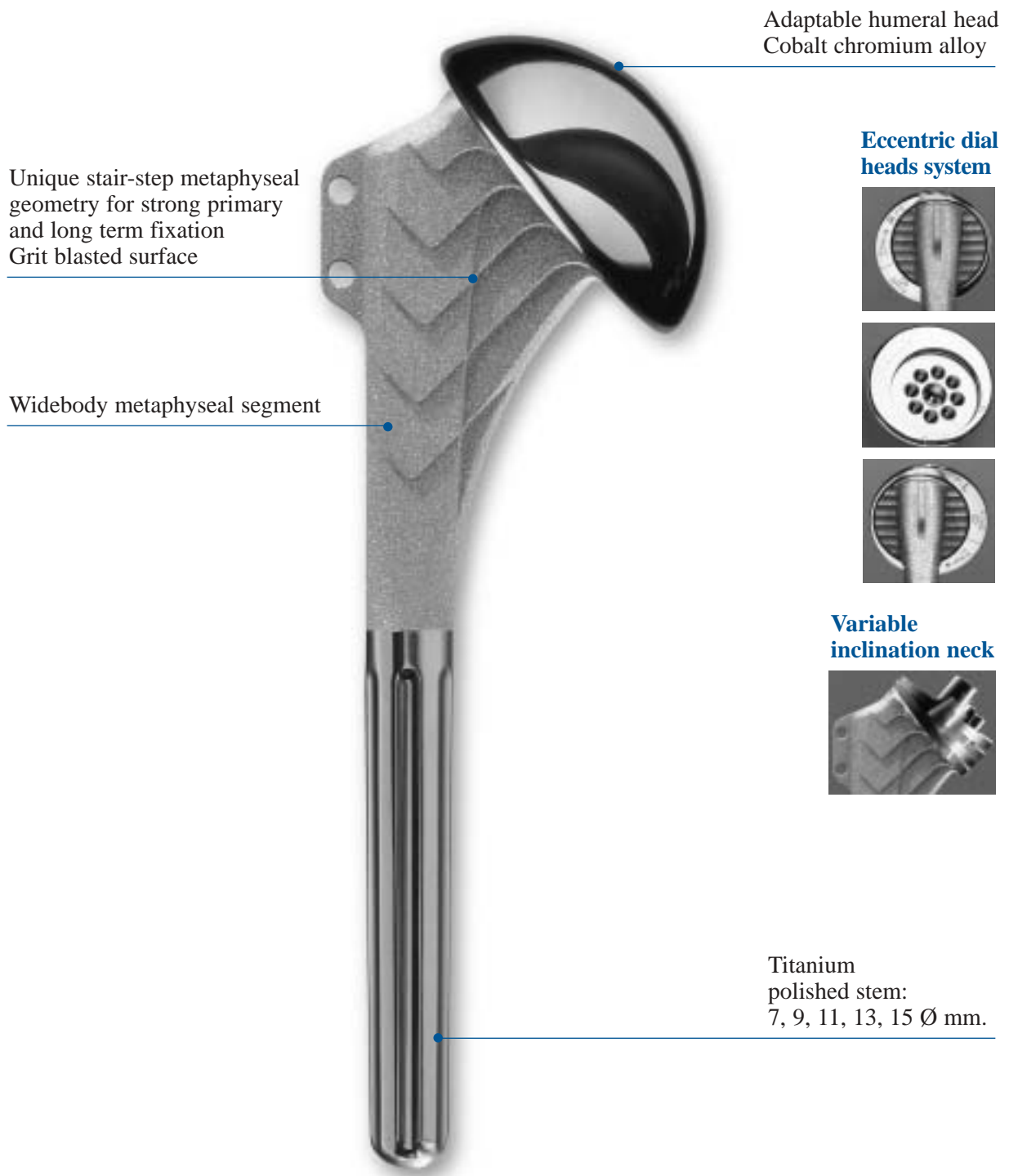
Ten articular heads are available, corresponding to the anatomical variations encountered in practice. Diameter and thickness are related, each corresponding to the anatomical variations.

For the largest three sizes, 50, 52 and 54 millimeters diameters, two thicknesses are available.

It is possible to reproduce the combined offset of the articular surface, medial and posterior offsets, by means of an original eccentric dial system.

* Adaptability and modularity of shoulder prosthesis. P. Boileau and Gilles Walch (Maîtrise orthopédique September 1993).

THE AEQUALIS PRESS-FIT PROSTHESIS



Designed to reproduce the anatomy.

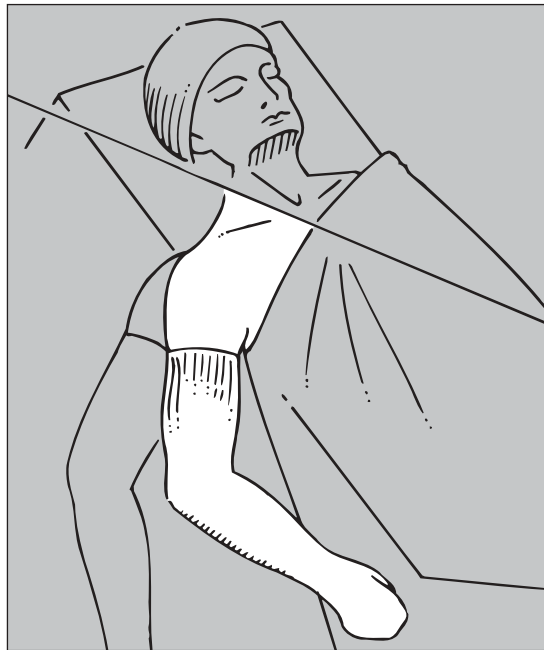SURGICAL TECHNIQUE

1. A detailed radiological assessment will assist in the preoperative planning

- Four plain shoulder A-P x-rays: neutral, internal rotation, external rotation and axillary.
- CT Scan for the most accurate assessment of glenoid version.
- Arthrography with contrast to confirm integrity of the rotator cuff if there is a clinical question about the cuff integrity.

2. Patient positioning

General anesthesia, beach chair position (fig. 1).

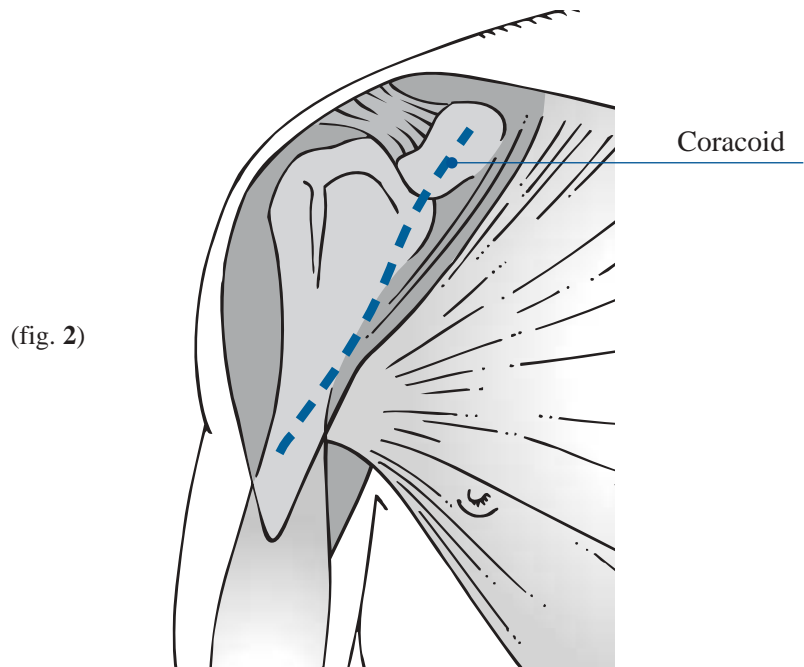


(fig. 1)

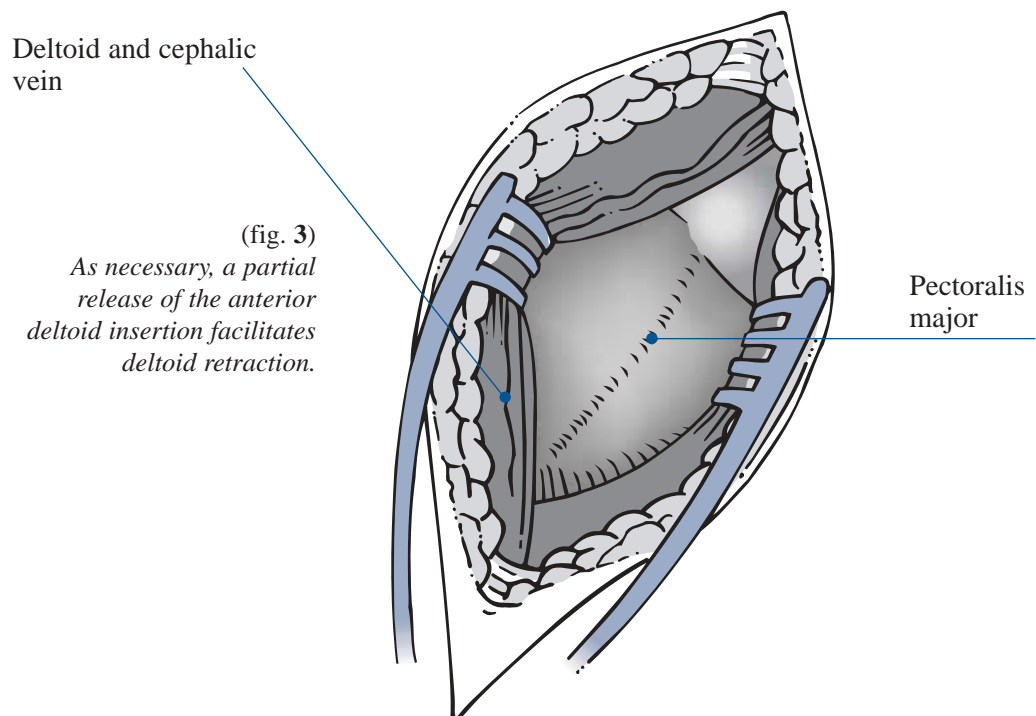
*The entire arm is draped free
and prepared under sterile conditions.*

3. Delto-pectoral approach

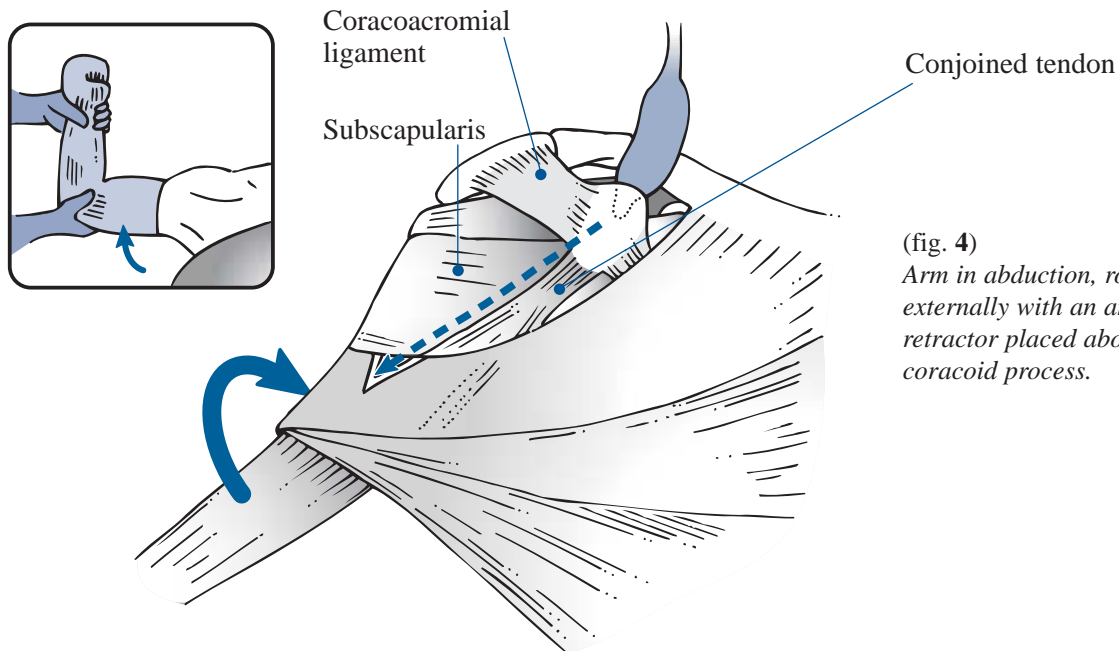
An incision is made from the coracoid along the Delto-pectoral groove, laterally to the axillary fold to avoid a post-operative contracture (fig. 2).



The Delto-pectoral interval is developed (fig 3).

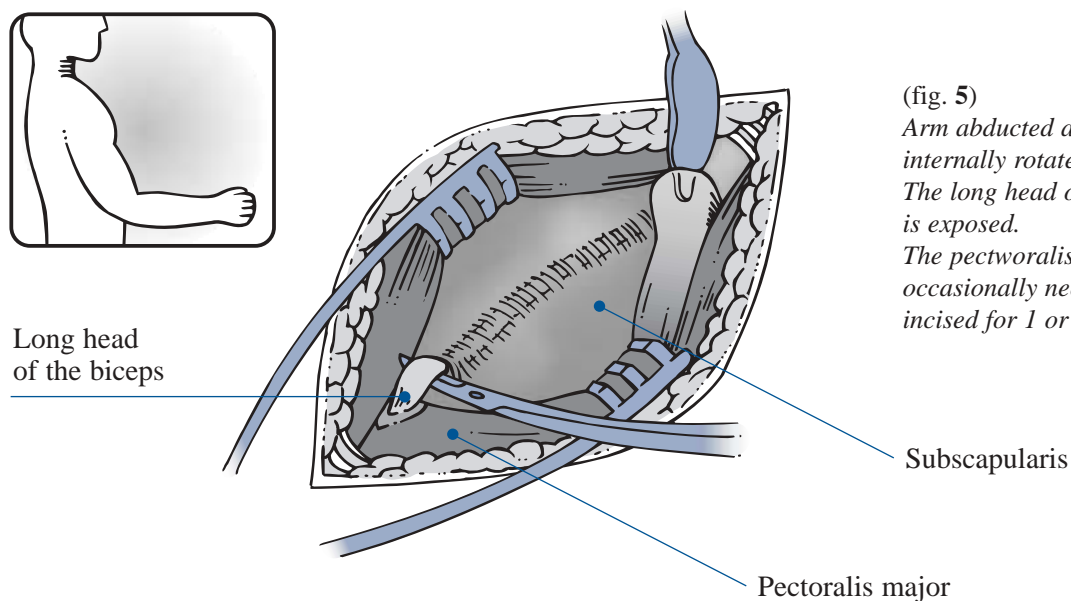


The upper border of the subscapularis is identified. The clavi pectoral fascia is released up to the coracoid between the coracoacromial ligament and the conjoined tendon of the coracobrachialis and short head of the biceps brachii muscles (fig. 4).



(fig. 4)
Arm in abduction, rotated externally with an angled retractor placed above the coracoid process.

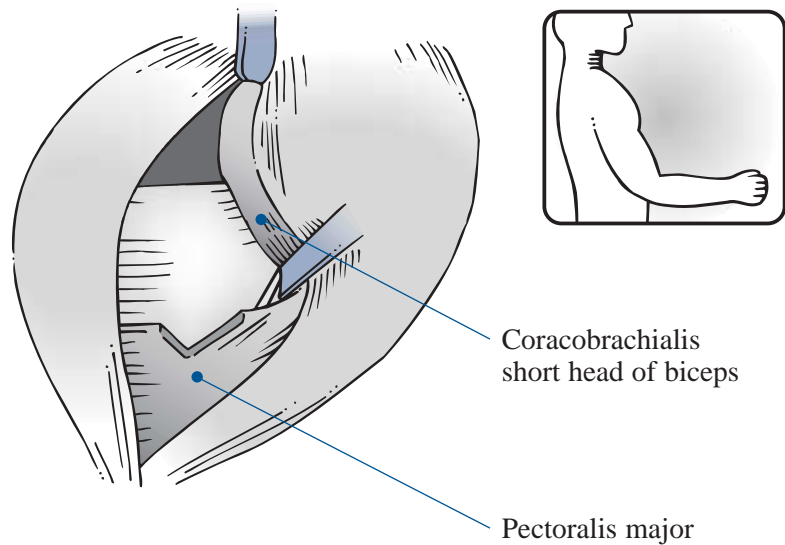
Inspect the bicipital groove to remove any osteophytes, loose bodies or excessive biceps tenosynovian. Move the biceps laterally (on the left) to check the groove.



(fig. 5)
Arm abducted and internally rotated. The long head of the biceps is exposed. The pectoralis insertion occasionally needs to be incised for 1 or 2 cm.

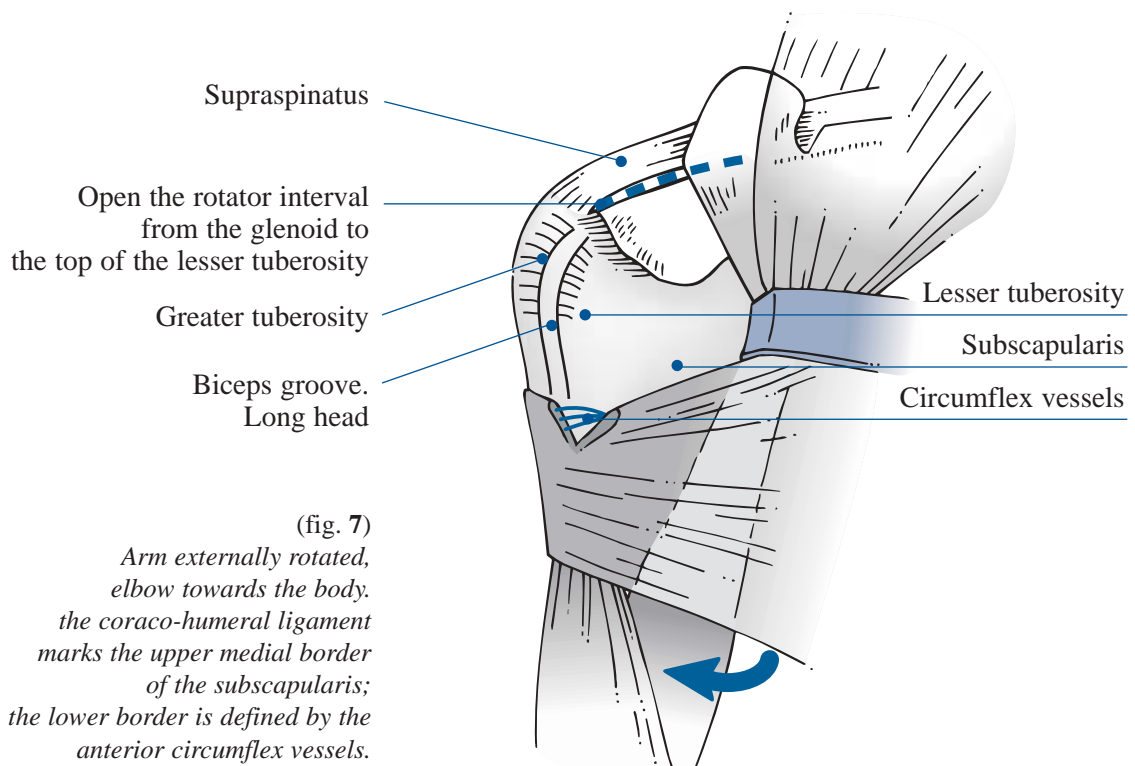
IDENTIFICATION OF THE AXILLARY NERVE

(fig. 6)
*Arm in neutral rotation,
 elbow at side, with anterior flexion
 to loosen the anterior structure
 (coraco-biceps).*



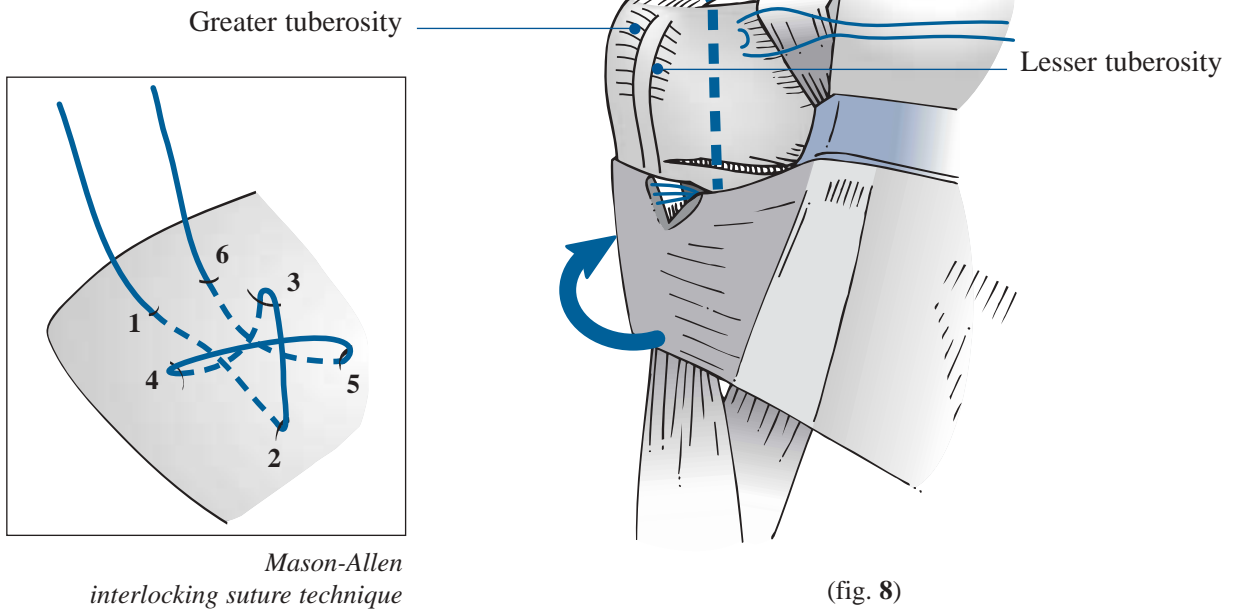
SUBSCAPULARIS TENDON RELEASE

- *The upper limit of the tendon of the subscapularis, which is often covered by an extension of the subcoracoid serous bursa, lies immediately below the tip of the coracoid process (fig. 7).*
- *Its inferior border is defined by the anterior circumflex vessels.*



A modified Mason-Allen interlocking suture is placed at the top corner of the subscapularis adjacent to the rotator interval (fig. 8).

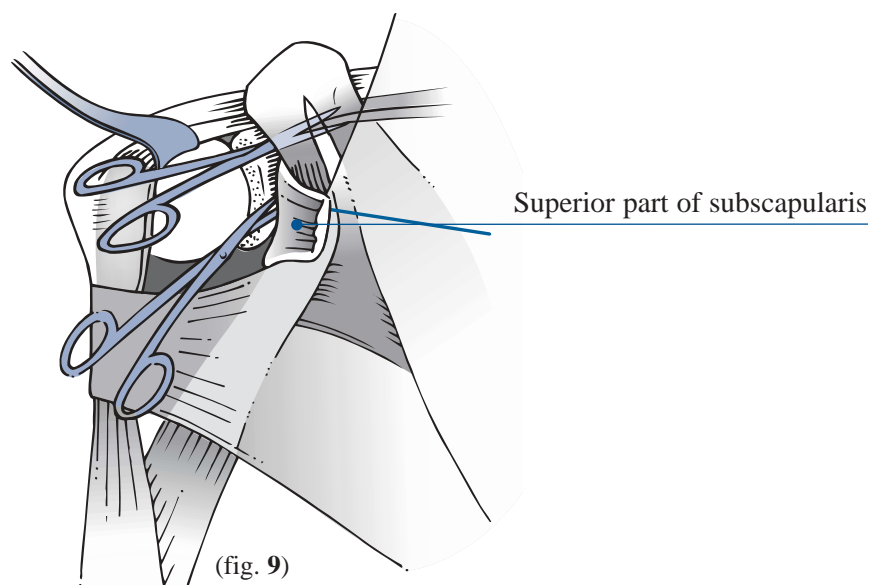
*Superior arthrotomy:
the coraco-humeral ligament
is preserved.*



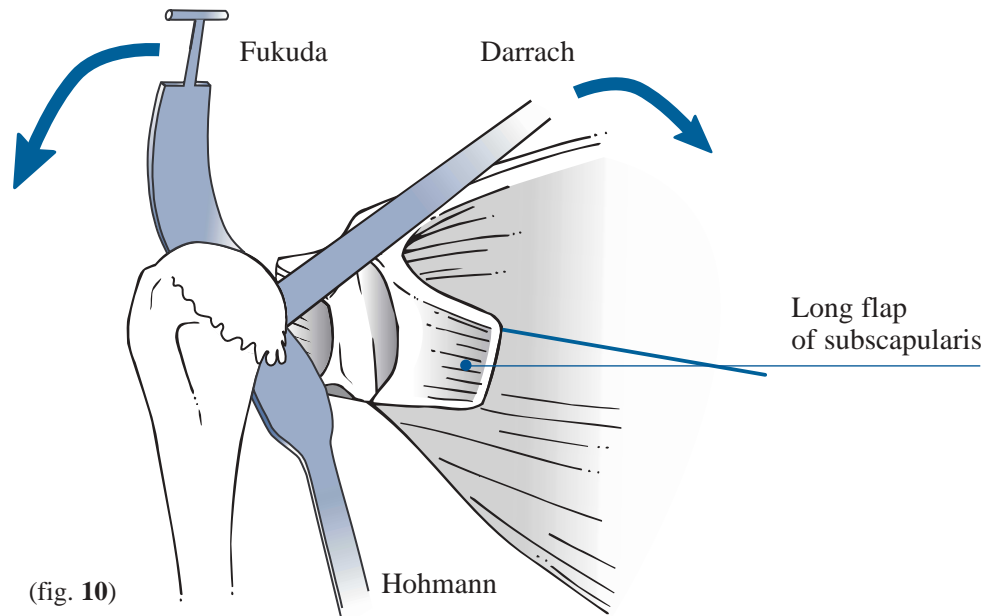
After opening the rotator interval, the anterior subscapularis is incised 1 cm medial to its insertion on the lesser tuberosity. Then, with a progressive rotation of the arm, the inferior capsule is released up to the posterior aspect of the humeral head (fig. 9).

The release of the upper pectoralis and latissimus dorsi tendons facilitates the exposure and release of the inferior gleno humeral capsule.

*The inferior release
is a key step for
adequate glenoid release.*



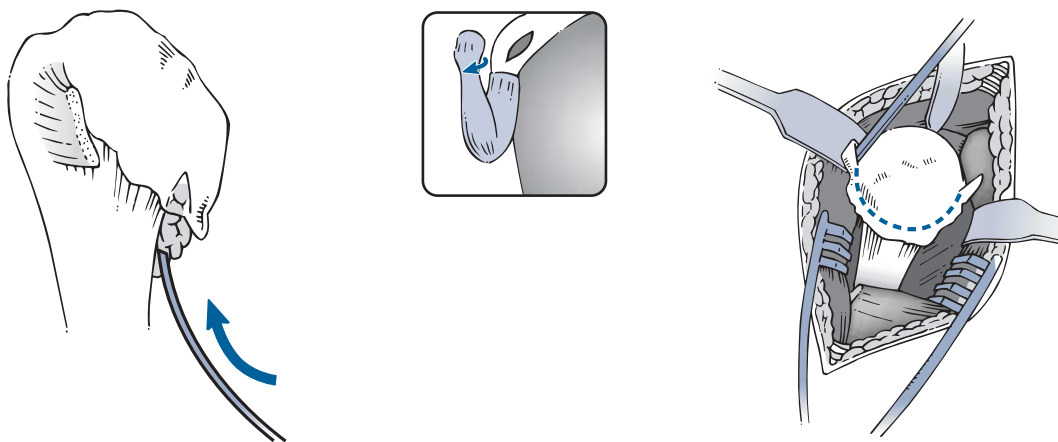
An anterior capsulotomy is performed with a release of the middle and inferior glenohumeral ligament to mobilize the muscle and produce a long flap of subscapularis which allows tension-free reinsertion following the procedure, regardless of the position of the arm (fig. 10).



With these adequate releases, the humeral head is dislocated into the deltopectoral interval by abduction of the arm progressive external rotation extension. In cases of severe restriction of external rotation (0° or less), it is recommended to release more of the pectoralis insertion.

4. Humeral head osteotomy

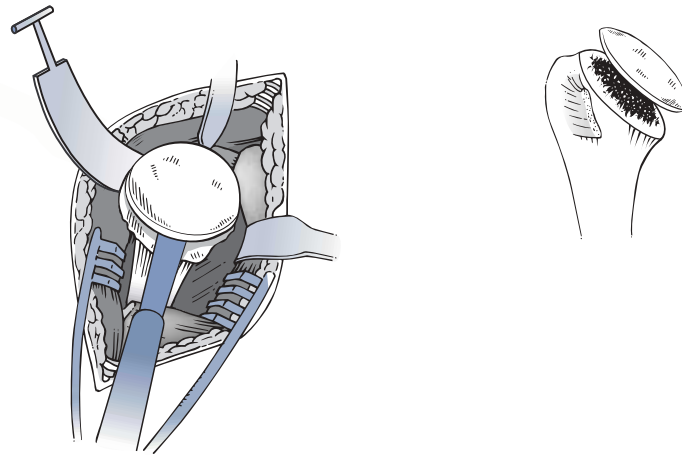
All osteophytes are carefully trimmed from the humeral head. It is recommended to use a curved osteotome to separate the interval between the osteophyte and the cortical bone. The osteotome is placed inferiorly and directed upwards. The goal is to identify the exact capsular insertion at the anatomic neck.



If additional exposure is necessary to visualize the superior articular margin, a curved awl or sharp Hohmann is placed under the long head of the biceps and through the supraspinatus attachment to evert both. The cut is then marked with a bovie.

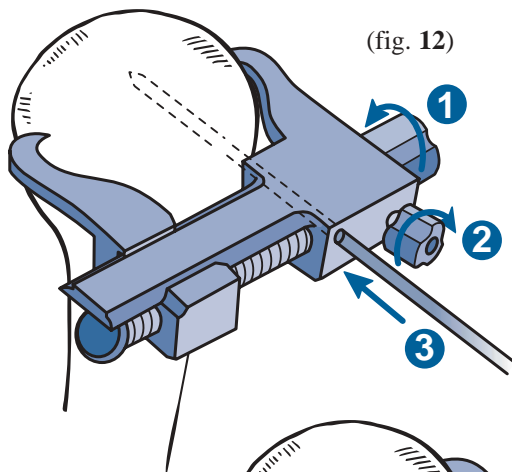
Superiorly and anteriorly, the anatomical neck contains the tendon insertions of the rotator cuff (supraspinatus and subscapularis), and inferiorly it is entirely continuous with the cartilage of the head and inferior cortical surface of the humerus. Posteriorly however, there is a 6 to 8 mm area which does not contain cartilage or tendon insertions; the cut should be made through the rim of the cartilage in a manner to preserve the posterior non-articular bare area.

- The humeral head may be cut freehand (fig. 11):



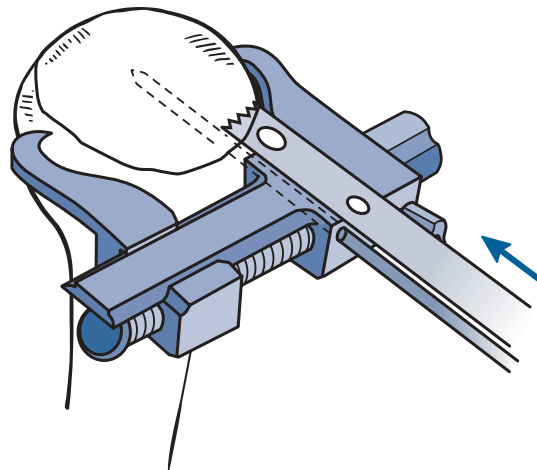
(fig. 11)

- Or with a cutting guide using an oscillating saw along the limit of the anatomical neck (fig. 12 & 13):



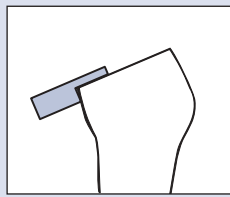
(fig. 12)

The cutting guide is positioned around the anatomical neck. The two fixation hooks are securely fixed around the neck by first tightening the adjustment knob ① followed by knob ②. Firm three point fixation is then achieved by inserting the 3 mm guide pin through the guide into the humeral head ③.

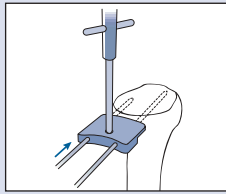


The oscillating saw is then used flat on the cutting guide.
(fig. 13)

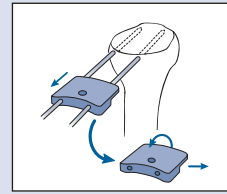
In case the cut is too superior, the re-cutting guide may be used to remove an additional 2 mm.



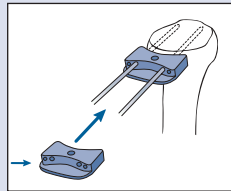
1•
Apply the guide on the humerus as shown.



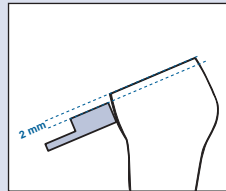
2•
Insert the pins.



3•
Remove the cutting guide and rotate 180°



4•
Reposition the guide on the pins.

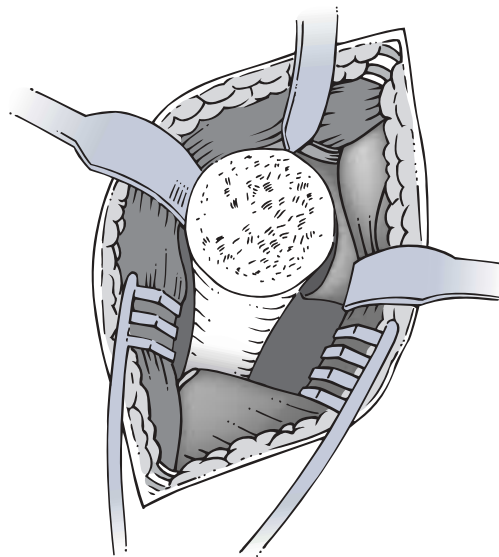


5•
Make the recut with the oscillating saw placed flat on the guide.

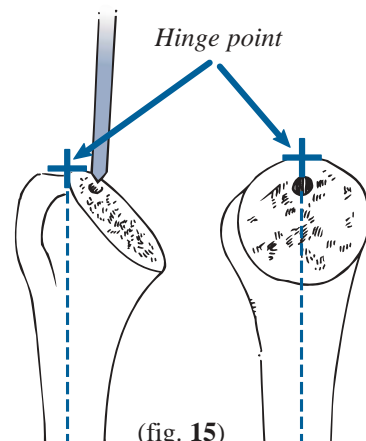
5. Reaming the humeral shaft

Accurate visualization of the plane through which the humerus is cut (fig. 14) allows the hinge point to be located. Typically, the entrance point into the humeral canal is 3 mm medial from this point (to prevent damage to the greater tuberosity). The hinge point is defined as the intersection of the proximal metaphyseal humeral axis and the highest point of the cut described previously (fig. 15).

The arm is placed in extreme external rotation, with the elbow towards the body utilizing careful progressive reaming to avoid the risk of a spiral fracture.

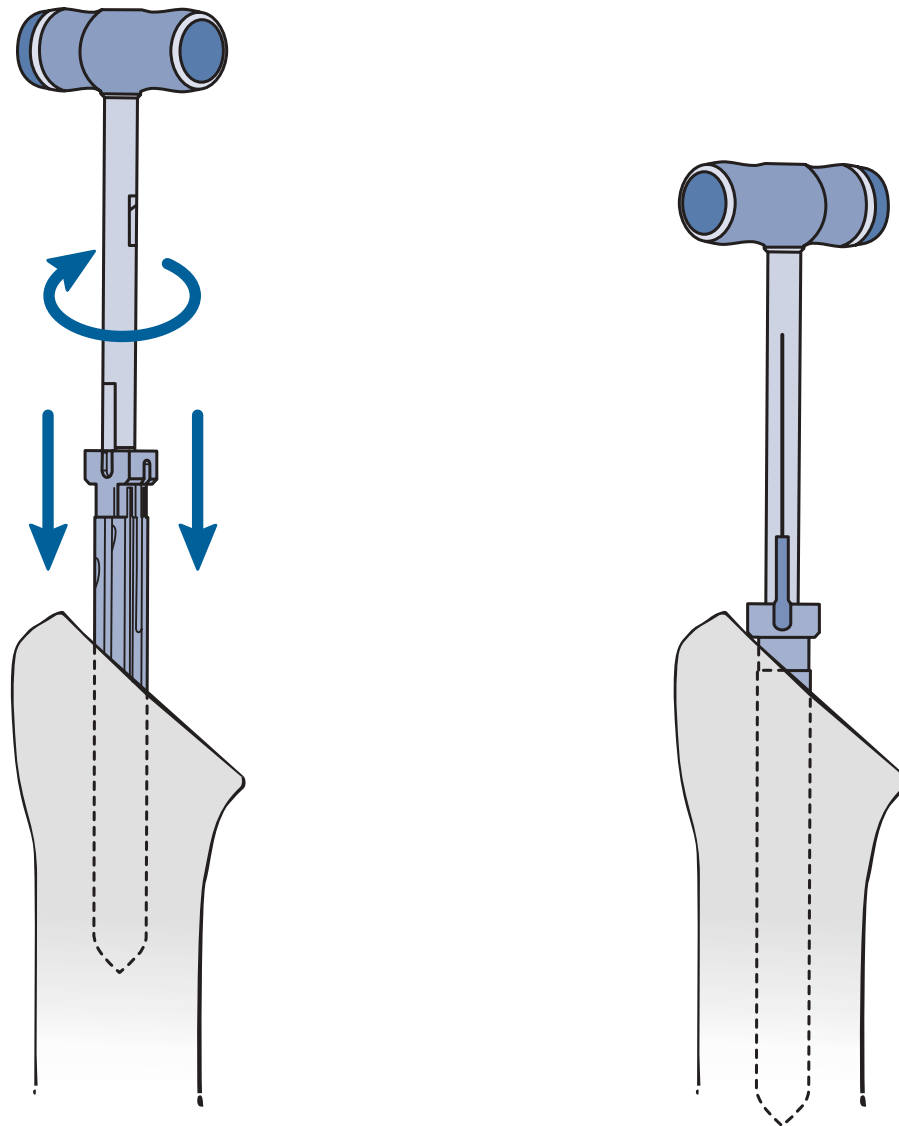


(fig. 14)



(fig. 15)

The humeral shaft is progressively reamed using reamers of increasing diameter from 7, 9, 11, 13 to 15 mm (fig. 16).



(fig. 16)

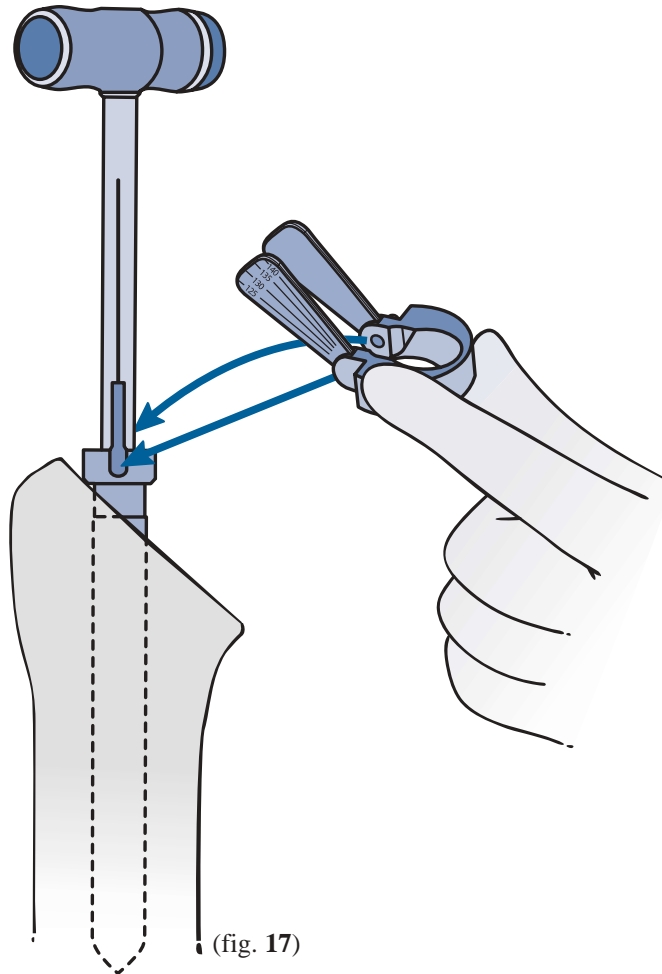
The reamer is inserted up to the collar.



Reaming is completed once **initial** contact is made with the cortical bone of the diaphysis.

6. Choice of humeral inclination and retroversion

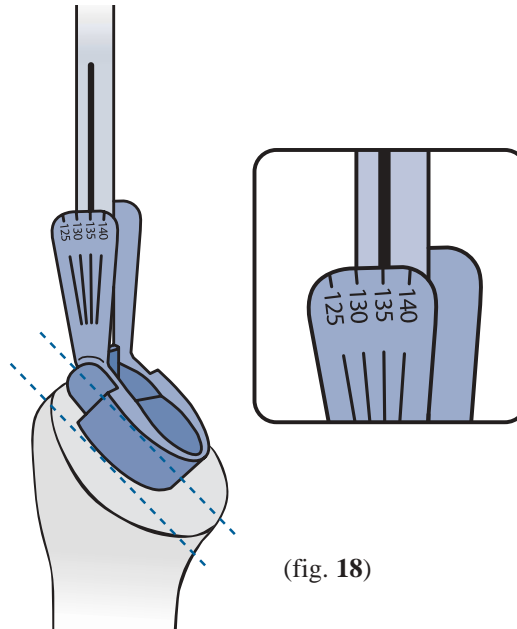
Once reaming of the humeral shaft has been completed, the reamer is left in the humerus. The inclination is then measured using the inclination guide (fig. 17). The inclination guide is then slid downwards and seated in the slots along the reamer.



The inclination is then assessed by reading the graded scale on the guide (template) (fig. 18). There are 4 possible inclinations, 125°, 130°, 135° and 140°.

When the angle lies between two values, the lower should be selected for the prosthesis.

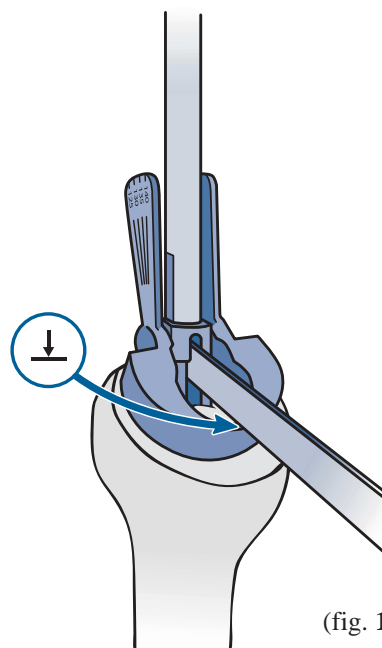
The mobile plate must sit flat on the anatomical cut. It may be necessary to slightly reorient the reamer using the handle to obtain optimal positioning of the inclination guide.



(fig. 18)

Humeral retroversion is marked with the inclination guide by making a groove into the greater tuberosity with the retroversion osteotome (fig. 19).

This groove will serve to orient the compactor fin.



(fig. 19)

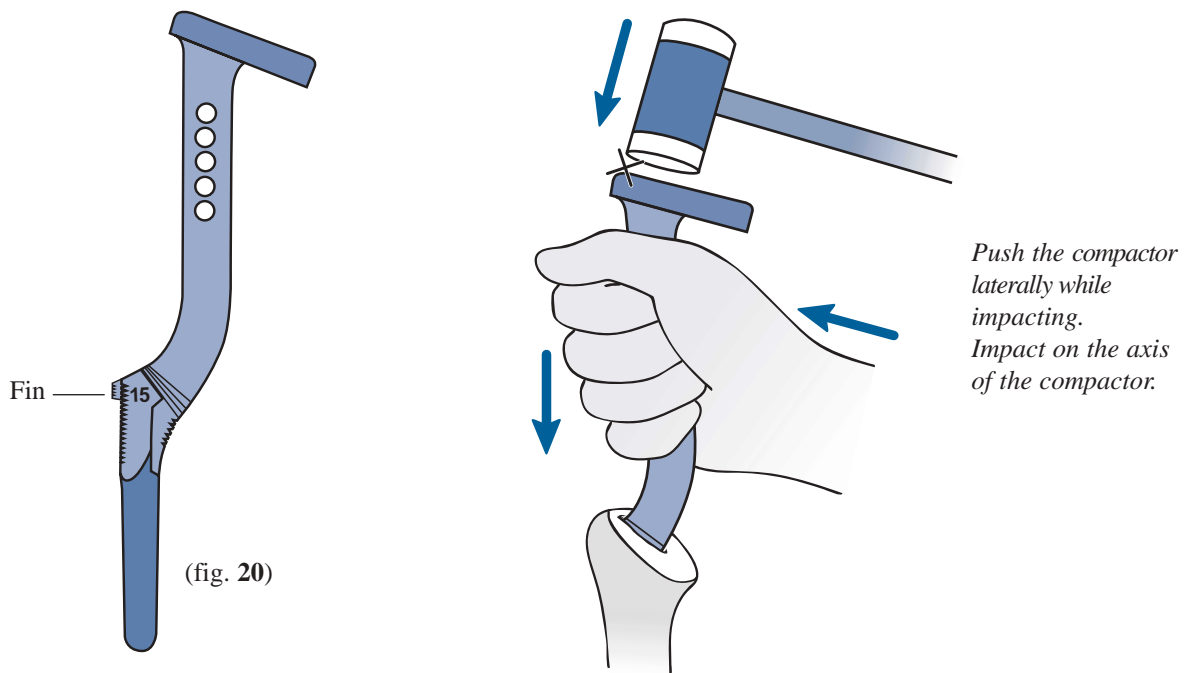
Remove the reamer and the inclination guide. Using a small rongeur, notch the cortical bone at the level of the groove to allow passage of the compactor fin (fig. 20).

7. Metaphyseal preparation

The monobloc compactors are used to prepare the metaphyseal bone (fig. 20).

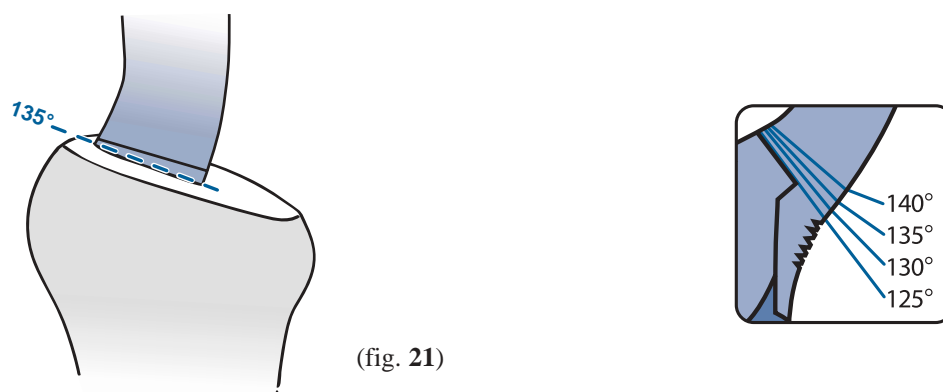
Start with the compactor of the smallest size and progress sequentially to the desired size. Retroversion is observed by aligning the fin of the compactor with the slot created by the osteotome described previously. Compaction is completed when metaphyseal stability is obtained.

It is important to avoid varus prosthetic placement. This is accomplished by positioning the compactor fin as far laterally as possible into the greater tuberosity.



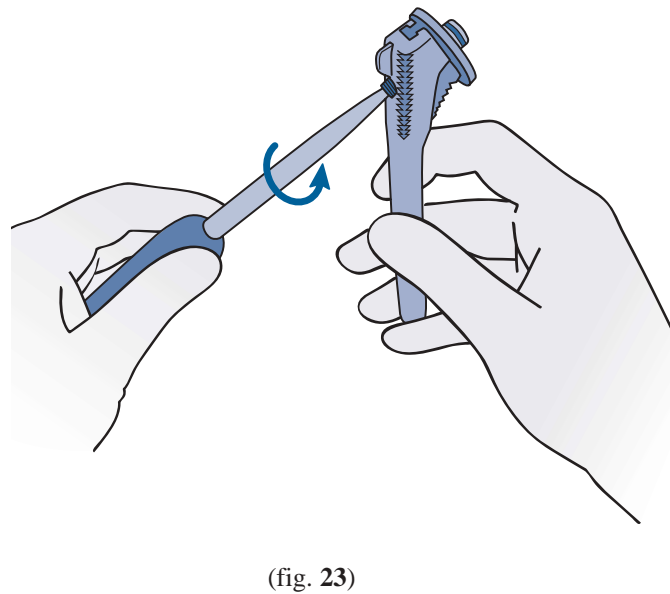
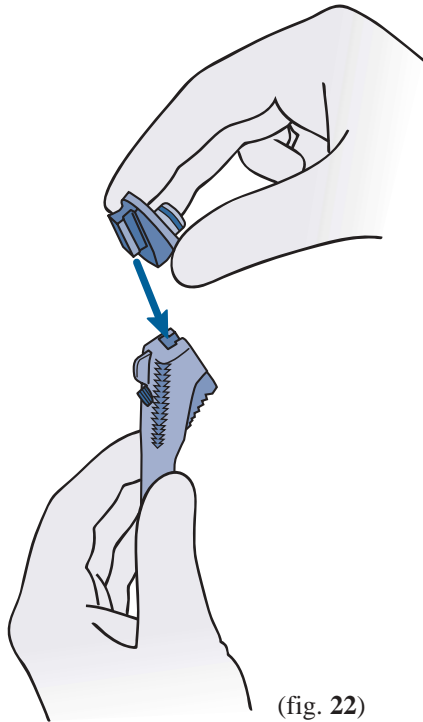
The compactor should be seated to the neck angle measured previously with the inclination guide.

For example: for a 135° angle, stop when its ridge is reached (fig. 21).

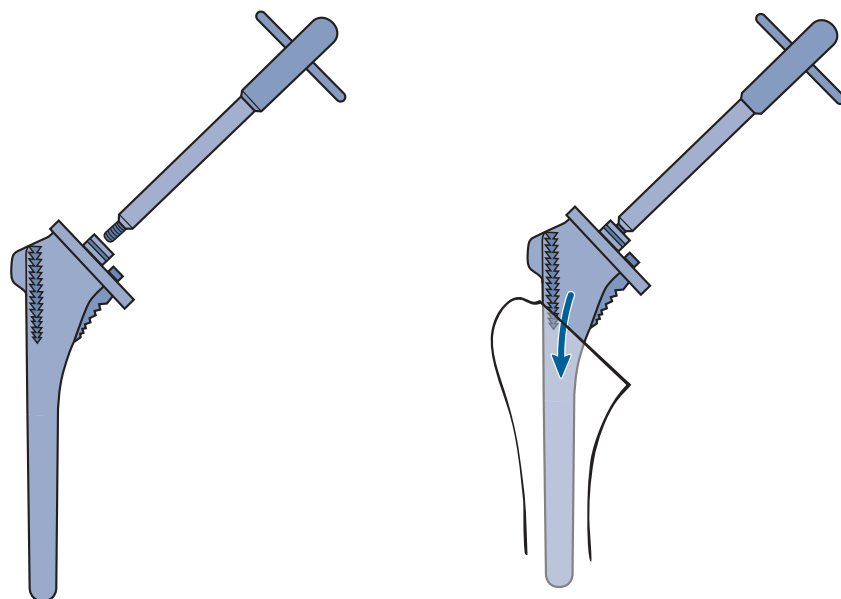


8. Trial humeral implant positioning and choice of the humeral head offset

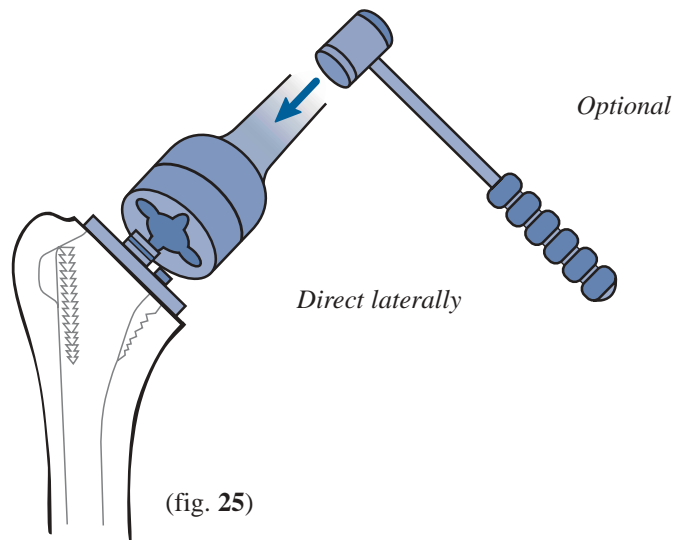
The humeral trial stem and trial neck are assembled. The trial neck chosen corresponds to the inclination determined with the inclination guide. The trial neck is slid onto the rail of the trial humeral stem (fig. 22). The system is secured by tightening the fixation screw with the 3.5 mm hexagonal screwdriver (fig. 23).



The trial stem-neck assembly is introduced into the prepared humeral shaft using the T-handle, taking care to observe the correct orientation of the fin (fig. 24). The T-handle is then removed.



It may be necessary to use the trial stem impactor to firmly seat the collar of the trial stem on the cut (fig. 25).



If the humeral trial prosthesis fits too low on the cutting surface or if there is insufficient bony support, it is recommended to either use an impaction grafting technique with bone from the humeral head or cement the prosthesis to the proper height.

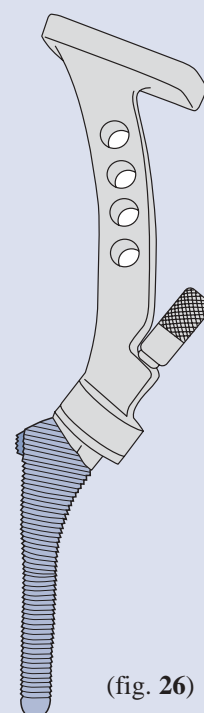
In case of the necessity to cement the Aequalis stem, it is recommended that the same trial stem diameter as the optimal compactor be used.

If the trial stem of the chosen size is unstable it is recommended to cement.

Use the broach of the smaller diameter (7 mm) and progress sequentially to the desired size (fig. 26).

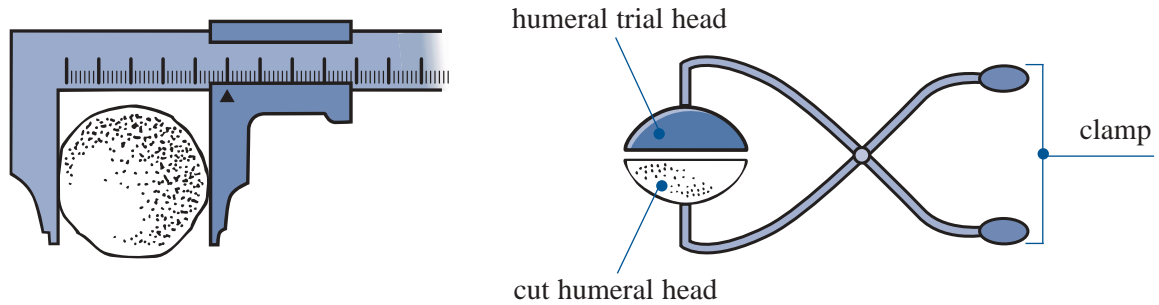
After positioning the trial head in an anatomic position, the entire trial prosthesis is then removed. Cement is injected into the canal after diaphyseal obturation and drying.

The definitive humeral implant is positioned and then impacted taking care to align the prosthetic fin with its slot in the tuberosity.



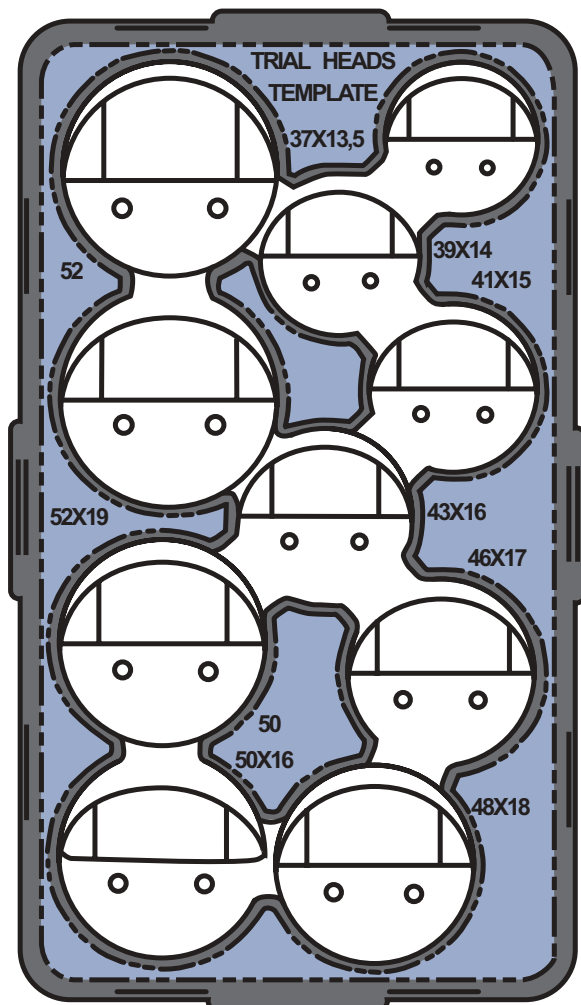
9. Determination of the trial head size

- either by caliper or clamshell measurement of the diameter of the resected head (fig. 27).



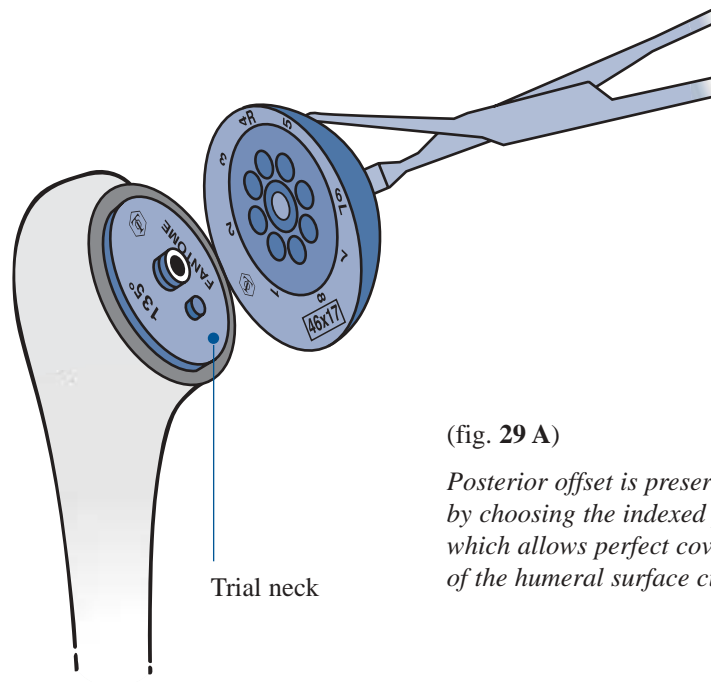
(fig. 27)

- or directly on the trial head template (fig. 28).



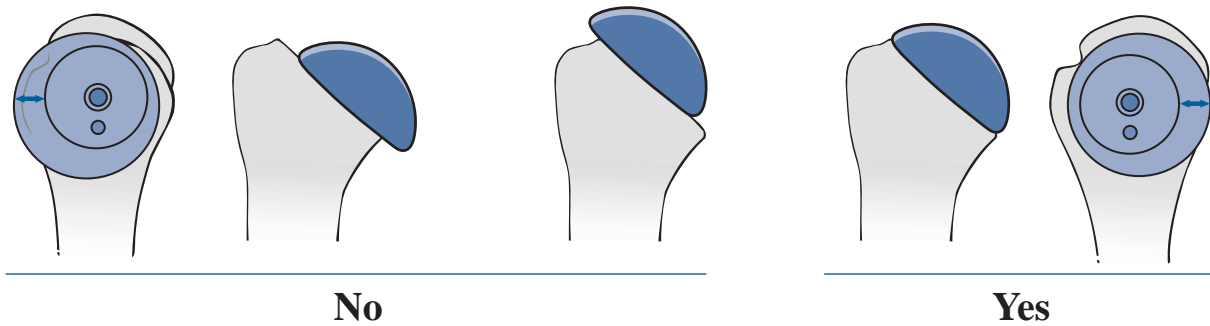
(fig. 28)
2 thicknesses are available
for a 50, 52, or 54 mm
diameter head.

The next step is to reproduce the articular surface offset using the eccentric index system. The trial head is held with the trial head clamp and placed over the neck trunion (fig. 29 A). The head is then rotated until the ideal coverage of the humeral neck cut is obtained (fig. 29 B).



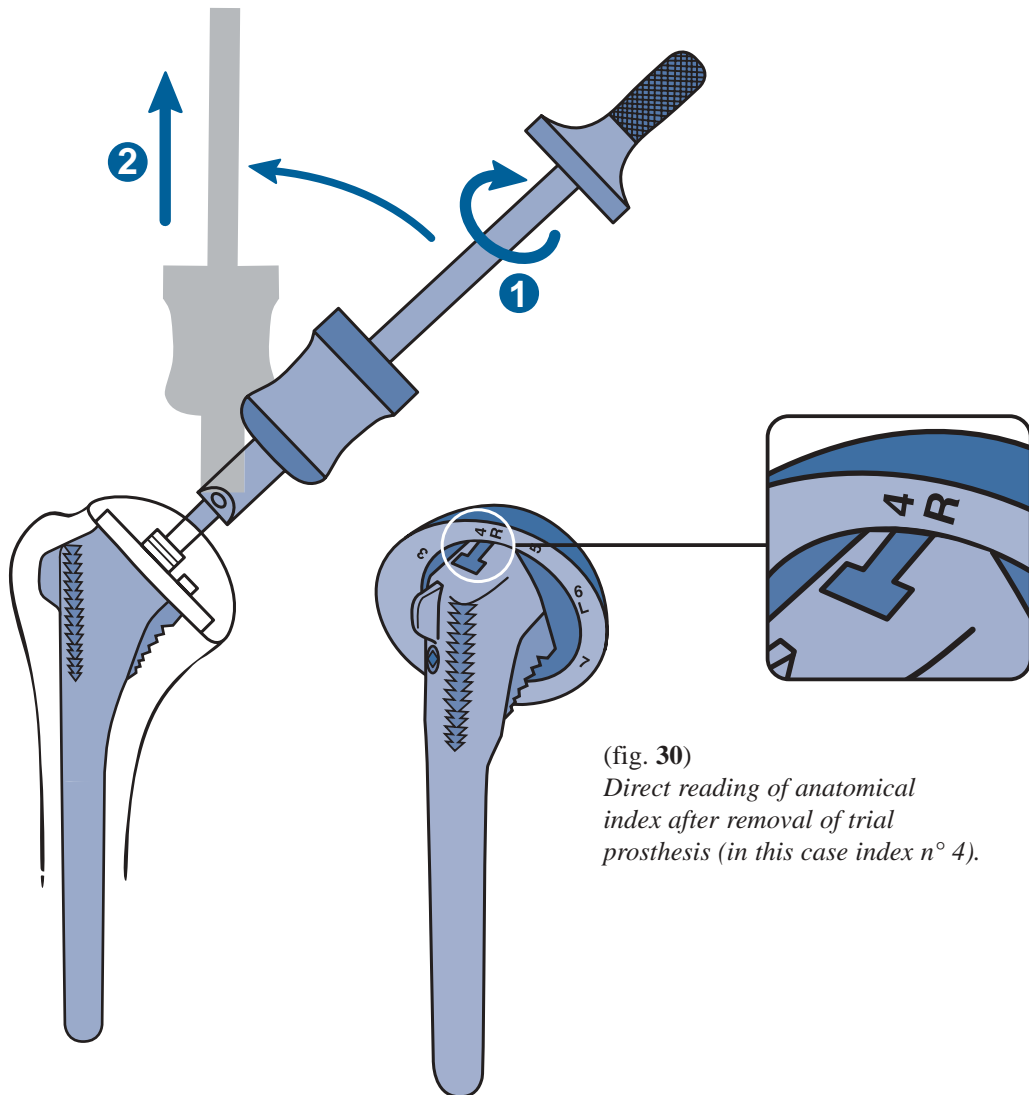
(fig. 29 A)

Posterior offset is preserved by choosing the indexed position which allows perfect coverage of the humeral surface cut.



(fig. 29 B)

The entire trial prosthesis is then removed using the extractor-hammer. The posterior face of each trial head is marked from 1 to 8, corresponding to 8 possible index positions. **The appropriate figure is read from the mark on the superior pole of the neck, to give the selected anatomical index** (fig. 30).



(fig. 30)
Direct reading of anatomical index after removal of trial prosthesis (in this case index n° 4).

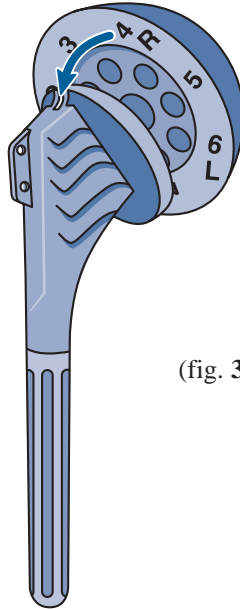
IMPORTANT NOTE

GLENOID REPLACEMENT MUST BE PERFORMED AT THIS POINT, IF NECESSARY.
PLEASE REFER TO THE AEQUALIS GLENOID SURGICAL TECHNIQUE.

10. Humeral implant assembly and positioning

After removing the trial humeral prosthesis, the final stem and head are chosen using the same parameters for diameter and inclination of the stem size and offset of the head.

The head is positioned on the stem, aligning the offset number with its position, using the fin of the implant stem as a reference (fig. 31).

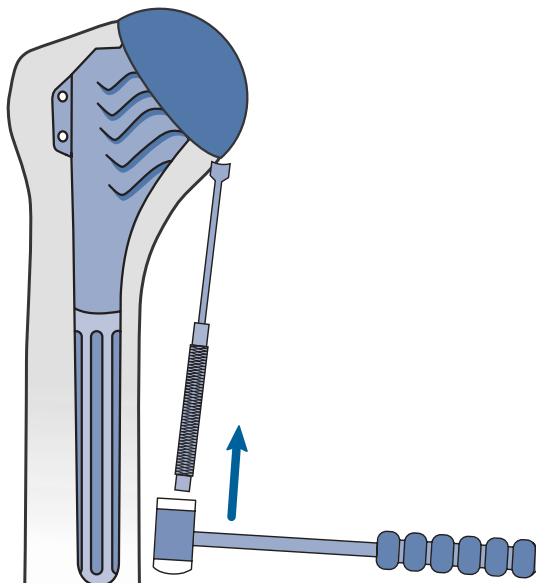


(fig. 31)

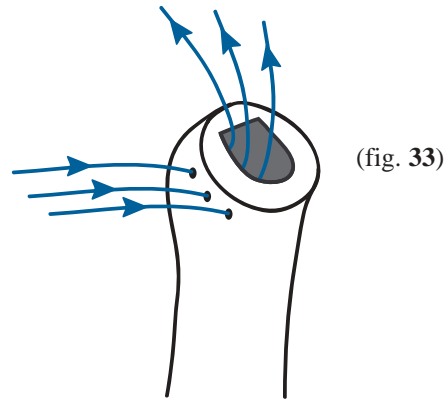
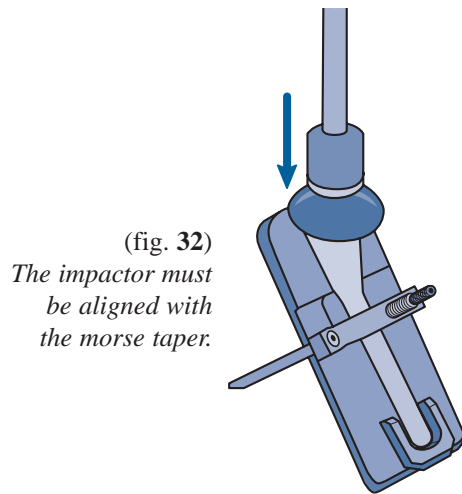
IMPORTANT NOTE

THE HEAD SHOULD BE ASSEMBLED TO THE IMPLANT STEM
WITH CLEAN GLOVES IN A DRY ENVIRONMENT.

Should a humeral head ever have to be removed, position the Humeral Head Removal instrument below the inferior part of the head and firmly tap with the mallet to loosen the head.



The head is impacted onto the stem using the impaction support (fig. 32) with the head impactor and the mallet. Take care not to damage the articulating surface of the implant head.

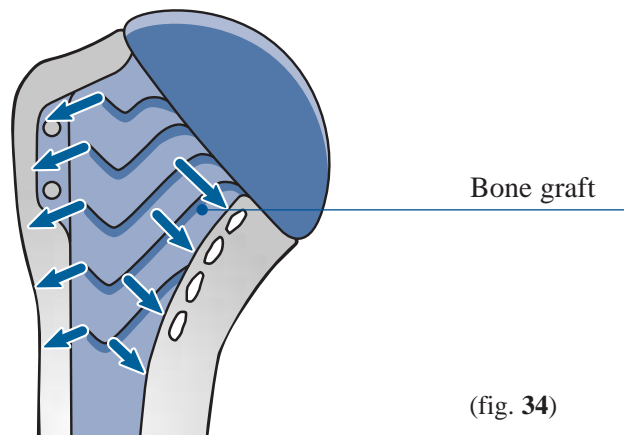


At this stage, the long head of the biceps is cut from the superior glenoid and tenodesed into the groove. Three subscapularis sutures are preplaced through the lateral subscapularis and lesser tuberosity (fig. 33).

The prosthesis is then inserted. Proper orientation of the prosthesis during insertion is assured by positioning the fin into the groove prepared with the retroversion osteotome (fig. 34).

The prosthesis has to be impacted carefully into the medullary canal to avoid metaphyseal fracture.

Note: In case of impingement of the stem in the medullary canal, the stem should be removed and a stem of a smaller diameter should be cemented.



11. Reduction of the prosthesis and closure


Following reduction of the humeral prosthesis, the stability and mobility of the shoulder are tested. The joint is closed by reinsertion of the subscapularis to the coraco-humeral ligament, and to the subscapular remnant, allowing slight slippage of the subscapularis upwards. The wound is closed in layers over an aspiration drain.

Post-operatively the arm is immobilized in a simple sling.

INSTRUMENTS

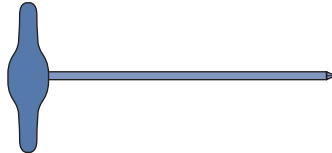
50 cm ruler

Ref. MWA 123



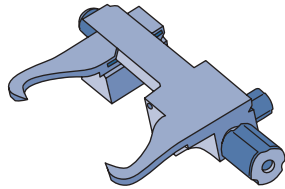
Awl

Ref. MWA 024



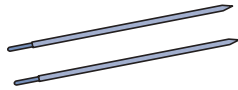
Humeral cutting guide

Ref. MWB 065



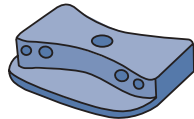
3 mm guide pins

Ref. MJU 051



2 mm humeral Re-cutting guide

Ref. MWB 066



Cylindrical reamers

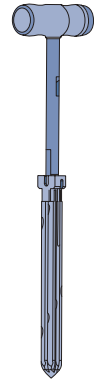
Ø 7 Ref. MWB059

Ø 9 Ref. MWB060

Ø 11 Ref. MWB061

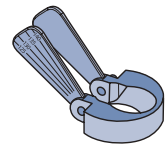
Ø 13 Ref. MWB062

Ø 15 Ref. MWB063



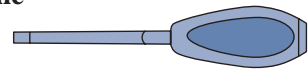
Inclination guide

Ref. MWB058



Retroversion Osteotome

Ref. MWA101



Monobloc Compactors

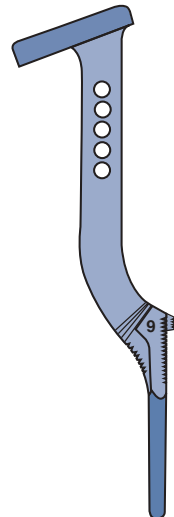
Ø 7 Ref. MWB 050

Ø 9 Ref. MWB 051

Ø 11 Ref. MWB 052

Ø 13 Ref. MWB 053

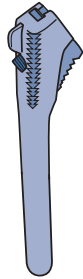
Ø 15 Ref. MWB 054



INSTRUMENTS

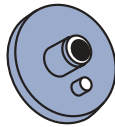Trial stems

Ø 7 mm	Ref. MWB 020
Ø 9 mm	Ref. MWB 021
Ø 11 mm	Ref. MWB 022
Ø 13 mm	Ref. MWB 023
Ø 15 mm	Ref. MWB 024



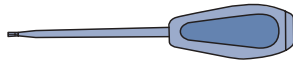
Trial necks

125°	Ref. MWB016
130°	Ref. MWB017
135°	Ref. MWB018
140°	Ref. MWB019



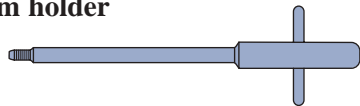
Hexagonal screwdriver 4.5 mm

Ref. MWB012



T. handle trial stem holder

Ref. MWA106



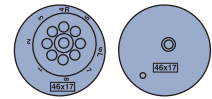
Trial stem impactor

Ref. MWA109

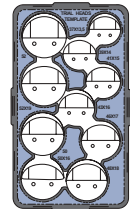


Trial heads

37 x 13.5	Ref. MWA237
39 x 14	Ref. MWA239
41 x 15	Ref. MWA241
43 x 16	Ref. MWA243
46 x 17	Ref. MWA246
48 x 18	Ref. MWA248
50 x 16	Ref. MWA250
50 x 19	Ref. MWA251
52 x 19	Ref. MWA252
52 x 23	Ref. MWA253

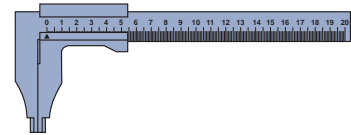


Trial head template



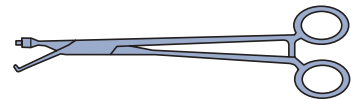
Caliper

Ref. MWA102



Trial head clamp

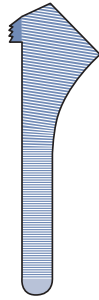
Ref. MWA103



INSTRUMENTS

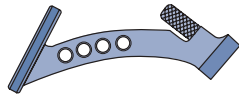
Humeral broaches (for cemented use only)

Ø 7	Ref. MWB034
Ø 9	Ref. MWB035
Ø 11	Ref. MWB036
Ø 13	Ref. MWB037
Ø 15	Ref. MWB038



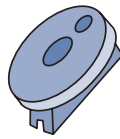Humeral broach handle (for cemented use only)

Ref. MWB015



Humeral cut protectors

125°	Ref. MWB025
130°	Ref. MWB026
135°	Ref. MWB027
140°	Ref. MWB028



Extractor hammer

Ref. MWA118



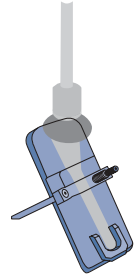
Humeral prosthesis impactor

Ref. MWA108



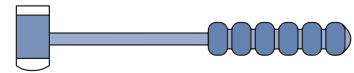
Impaction support

Ref. MWB013



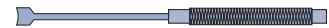
Mallet

Ref. MWA122



Head removal instrument

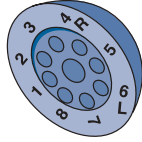
Ref. MWB 067



IMPLANTS

Heads

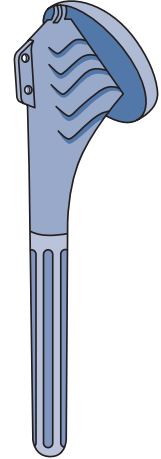
Size	Ref.
37 x 13.5	DWB 237
39 x 14	DWB 239
41 x 15	DWB 241
43 x 16	DWB 243
46 x 17	DWB 246
48 x 18	DWB 246
50 x 16	DWB 250
50 x 19	DWB 251
52 x 19	DWB 252
52 x 23	DWB 253



Humeral stems

∅	125°	130°	135°	140°	Lengths
7	DWB 701	DWB 702	DWB 703	DWB 704	115 mm
9	DWB 711	DWB 712	DWB 713	DWB 714	115 mm
11	DWB 721	DWB 722	DWB 723	DWB 724	115 mm
13	DWB 731	DWB 732	DWB 733	DWB 734	125 mm
15	DWB 741	DWB 742	DWB 743	DWB 744	125 mm

The length is given from the top of the fin to the distal end of the stem.




Extended sizes

(available upon special request only)

Heads

Size	Ref.
54 x 23	DWB254
54 x 27	DWB255

For more information, call toll free
1-888-TORNIER (867-6437)
or contact your local representative



This surgical technique has been developed
in conjunction with TOM NORRIS, M.D.,
(SAN FRANCISCO).

TORNIER

12875 Capricorn Dr., Stafford, TX 77477
Tel: (281) 494-7900. Fax: (281) 494-0206.
info@tornier.com