

Solar® Total Shoulder System

Upper Extremity Surgical Protocol



Solar[®] Total Shoulder System

Upper Extremity Surgical Protocol

Table of Contents

Introduction	1
Patient Positioning	3
Approach	4
Capsulotomy	7
Humeral Head Resection	9
Glenoid Preparation	11
Keeled Glenoid Component Preparation	14
Postoperative Care, Indications, Contraindications, Precautions, Warnings and Adverse Effects	22

This surgical protocol was compiled in conjunction with:

Robert H. Bell, M.D.

Chief, Shoulder Service
St. Thomas/Summa Health Systems
and Crystal Clinic
Akron, Ohio

Peter M Bonutti, M.D.

Assistant Clinical Professor
University of Arkansas
Director—Apogee Medical Research
Private Practice—Bonutti Orthopaedic
Clinic
Effingham, Illinois

Hugh B. Morris, M.D.

Chairman—Department of Orthopaedic
Surgery
Florida Hospital, Orlando
Clinical Instructor—Adult
Reconstruction
ORMC Residency Program, Orlando,
Florida
Reconstructive Hip and Knee Surgeon
Jewett Orthopaedic Clinic, Winter Park,
Florida

Michael D. Mason, D.O.

Staff Surgeon
New England Baptist Hospital
New England Bone & Joint Institute
Assistant Professor of Orthopaedic
Surgery
Boston University School of Medicine
Boston University Medical Center
Boston, Massachusetts

Paul Naylor, M.D., Ph.D.

Tennessee Orthopaedic Clinic
Knoxville, Tennessee

Gerald Rosenberg, M.D.

Chief, Upper Extremity Service
Ohio Orthopaedic Institute
Grant Medical Center
Columbus, Ohio

Stryker would also like to thank the above surgeons for their assistance in the development of this protocol.

Introduction

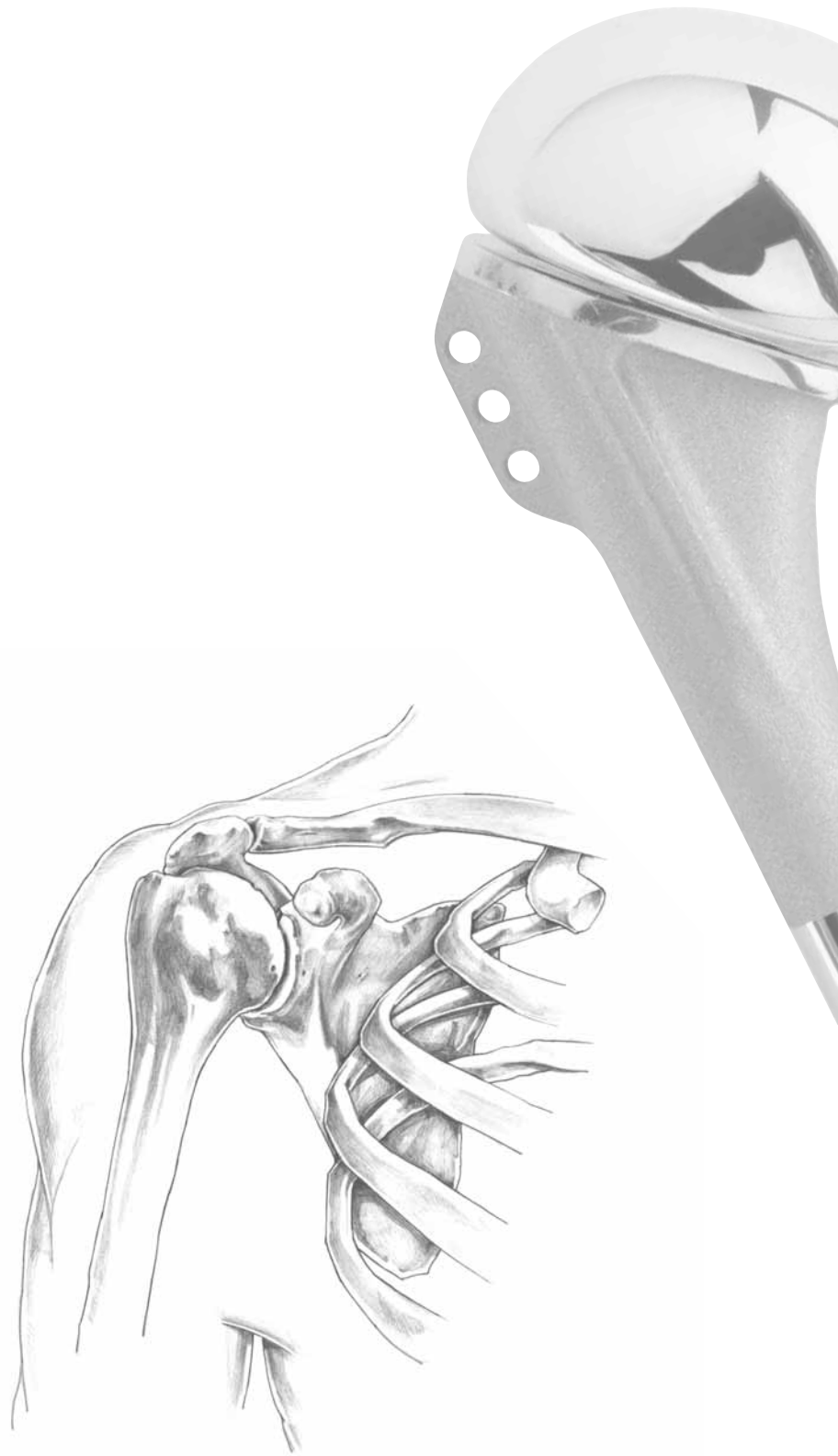Hemi and Total Shoulder Arthroplasty have proven to be successful procedures for numerous forms of arthritis of the glenohumeral joint. Due to advances in implant and instrumentation designs, along with surgical technique, success rates equal those of hip and knee implants and its application has grown steadily in recent years.

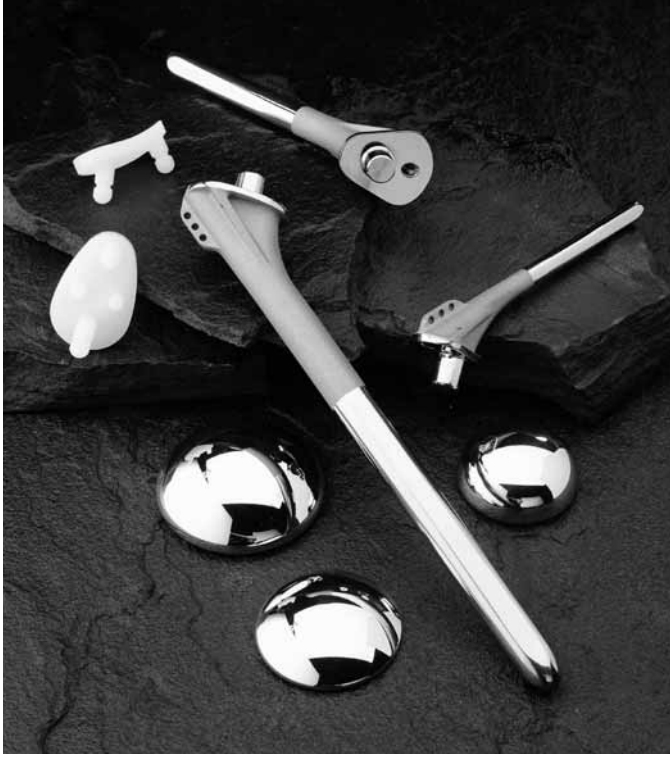



The Solar® Total Shoulder System was designed to address the most common arthritic disorders affecting the shoulder such as rheumatoid, osteo, and post-traumatic arthritis, avascular necrosis and various fractures of the proximal humerus. In most cases of disease involving both the humeral head and the glenoid, with an intact rotator cuff, optimal pain relief and function can be achieved with a total shoulder arthroplasty. In cases where the cuff is deficient and/or the disease process involves only the humeral head, consideration may be given to a hemi-arthroplasty.

Preoperative templating is imperative and assessment for candidates of shoulder arthroplasty must include radiographic studies including an anteroposterior, lateral scapular, Grashey* and axillary view. Additional studies, such as MRI, CT scan and arthrography may be beneficial to assess the integrity of the rotator cuff, deformation of the humeral head and glenoid deformation.

TechTip

*A true A/P and axillary view (Grashey) radiographic would be helpful in determining the true glenohumeral joint space.





Patient Positioning

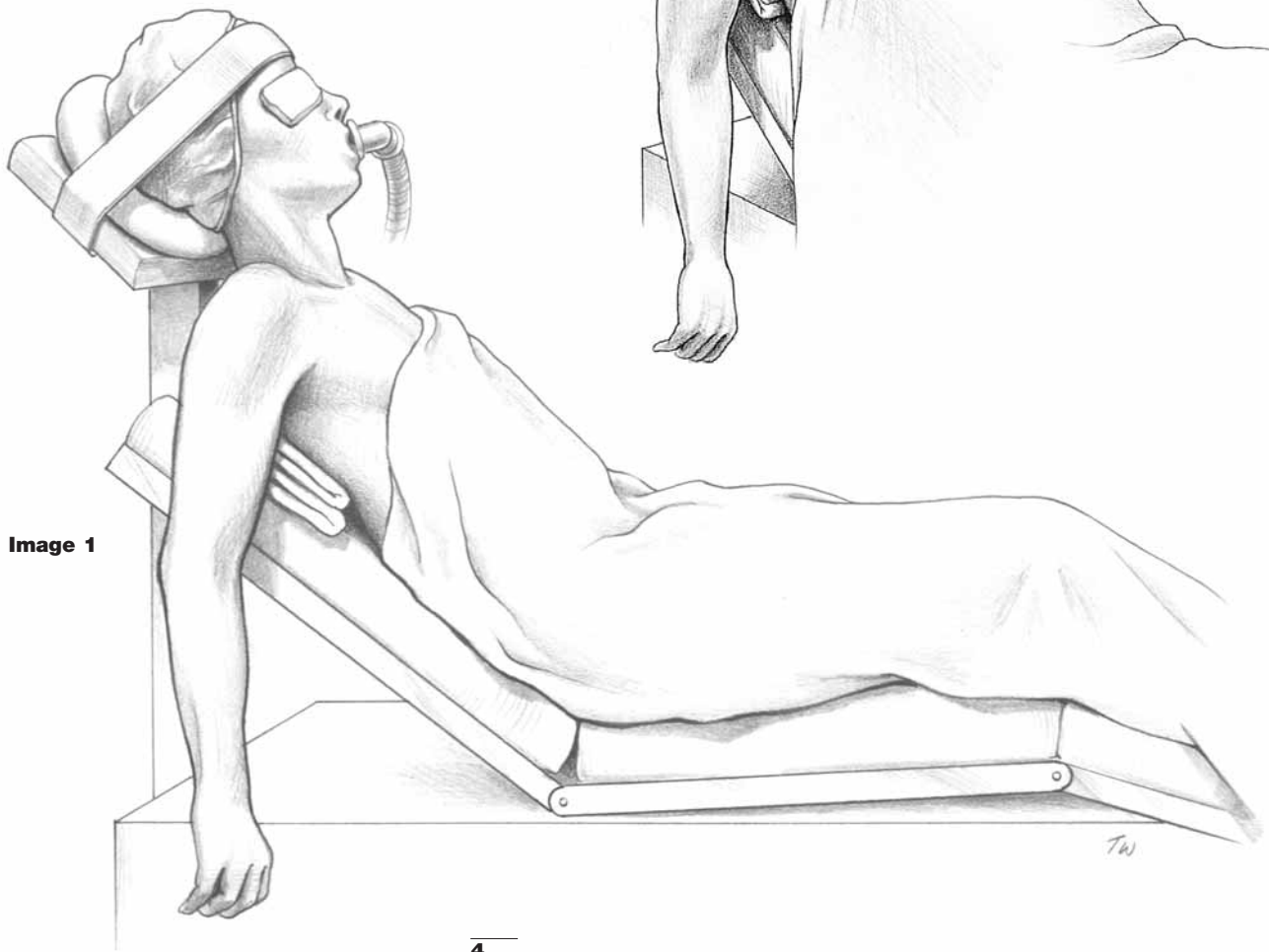For standard shoulder arthroplasty, the patient is positioned in a semi-Fowler beach chair position.* The back is flexed 30 to 45°, the legs are padded and bent. [Image 1] The patient's shoulder is brought to the edge of the table to allow full extension of the arm, thus affording exposure of the humeral shaft. A half liter IV bag or surgical towels are placed beneath the involved scapula to improve exposure of the articular surface. [Image 2]

The head is stabilized with a donut and taped in position, to avoid movement during the procedure. Ideally, anesthesia should be brought to the contralateral side of the table to allow full access to the surgical field.

TechTip

*Consideration may be given to a commercially available beach chair positioner.

Image 2



Approach

For most cases, an extended deltopectoral incision will be adequate to allow exposure to all involved structures. This begins 3-4cm medial to the acromioclavicular joint coursing distally over the coracoid process and along the deltopectoral fold. You will note that the cephalic vein is medial to the coracoid. [Image 3] In cases of hemi-arthroplasty alone, a limited exposure coming from coracoid process distally for a length of 8-10cm should allow adequate exposure. With the incision marked, a local anesthetic with Epinephrine may be injected into the subcutaneous tissue to limit skin bleeding. The incision is then taken down through subcutaneous tissue to the deltopectoral interval. The cephalic vein is identified and taken laterally with the deltoid. [Image 4]

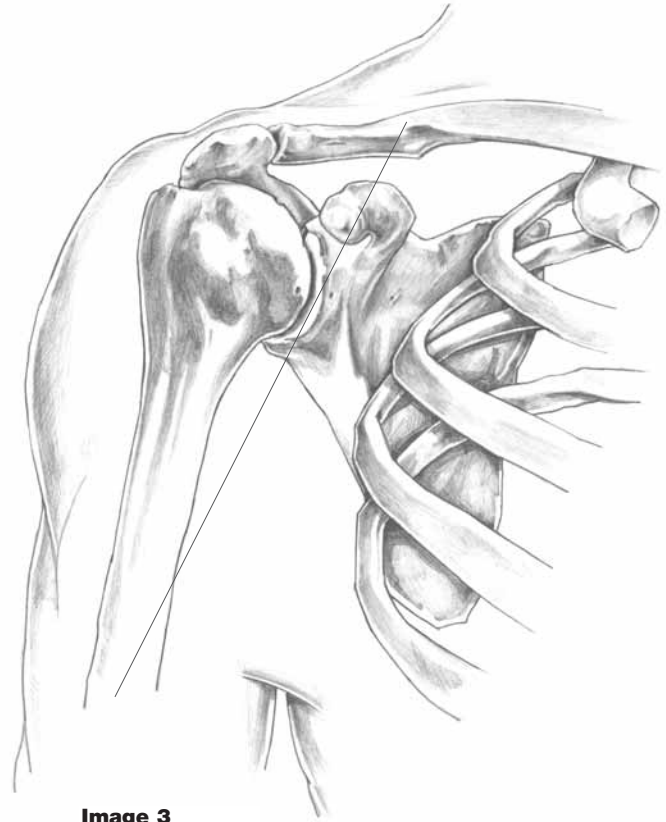


Image 3

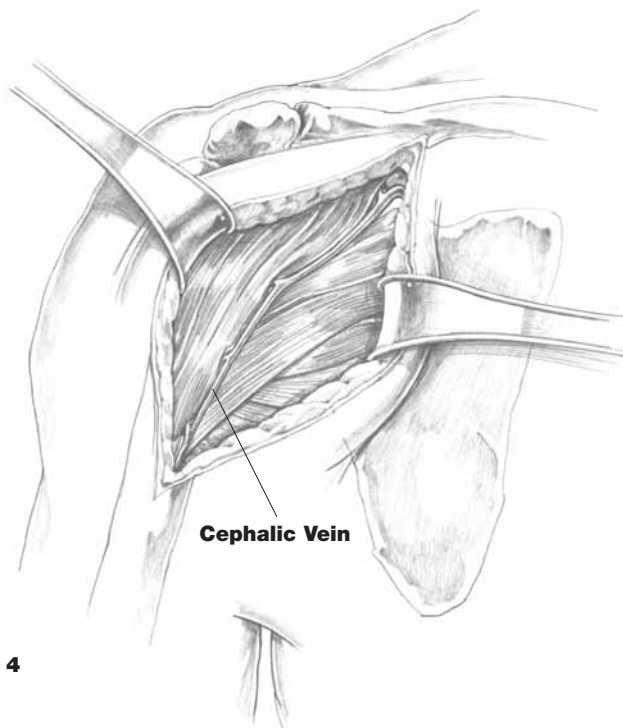


Image 4

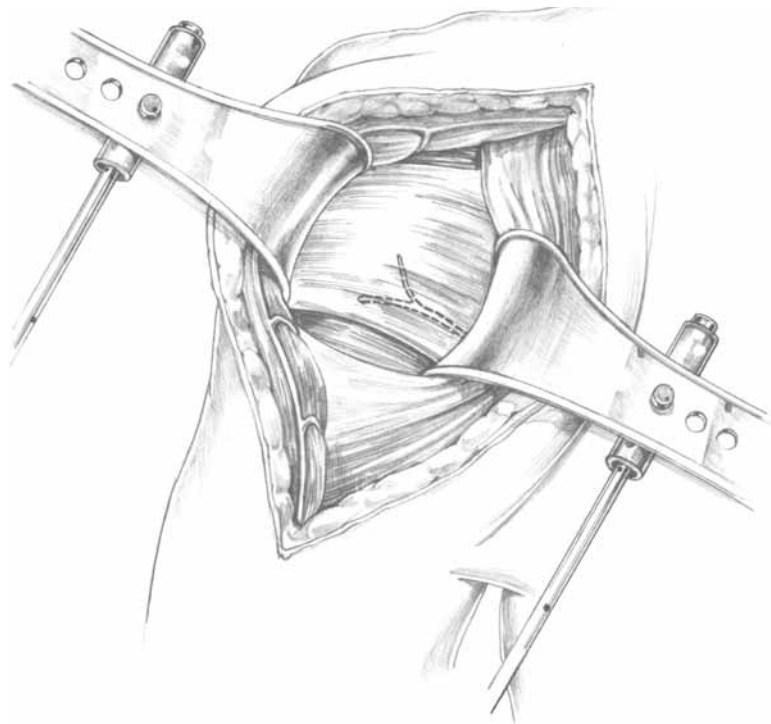


Image 5

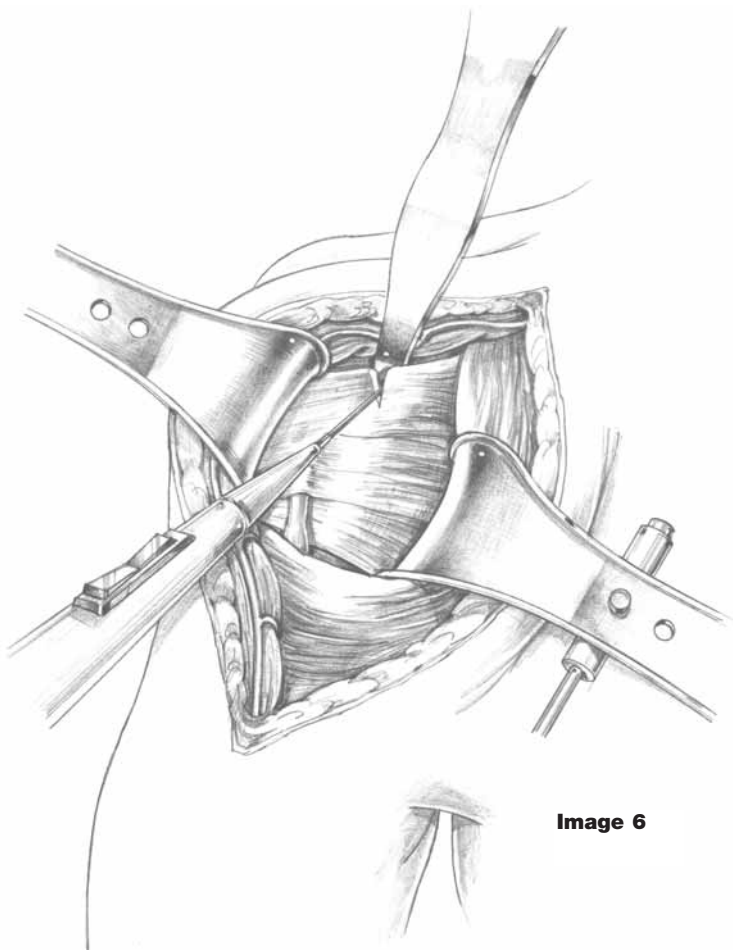


Image 6

A self-retaining or Richardson type retractor may be placed beneath the pectoralis medially and the deltoid laterally. [Image 5] The conjoined tendons, as they originate from the coracoid process, are identified and the interval deep to the tendons and superficial to the subscapularis is developed by finger dissection. The musculocutaneous nerve may be palpated beneath the conjoined tendon. The medial retractor is repositioned in this interval. It is important to keep the blade superior so as to avoid any injury to the musculocutaneous nerve. A blunt retractor is then passed superiorly beneath the coracoacromial ligament and acromion and superficial to the rotator cuff tendons. This allows additional exposure of the rotator interval and the anterior capsule. [Image 6]

At this point, it is advisable to palpate and, if possible, visualize the axillary nerve as it courses along the superficial surface of the subscapularis down into the axillary fold inferiorly. [Image 7] By means of additional external rotation and abduction, many of the capsular structures will be brought laterally, thereby protecting the axillary nerve during capsular release. If there is excessive tension on the pectoralis major, the proximal two-thirds may be released at this point using electrocautery. [Image 8]

Furthermore, if excessive tension is present on the deltoid, a small portion of its tendinous insertion in the humerus distally may be released with electrocautery in a similar fashion.

TechTip

External rotation with abduction lets the axillary nerve fall away and be protected.

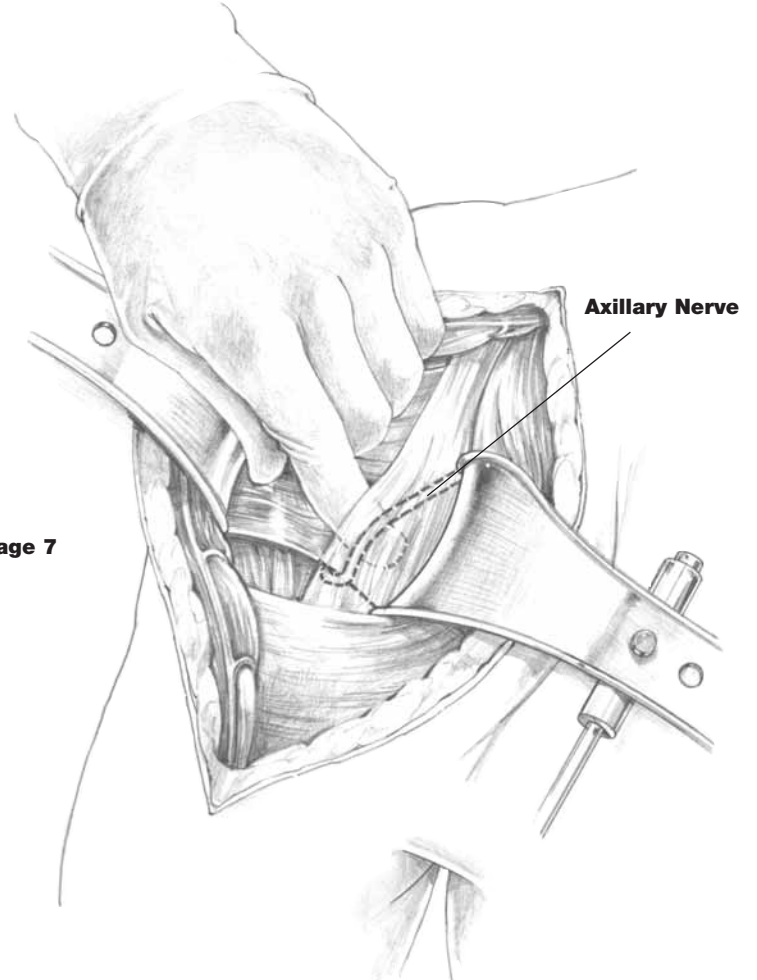


Image 7

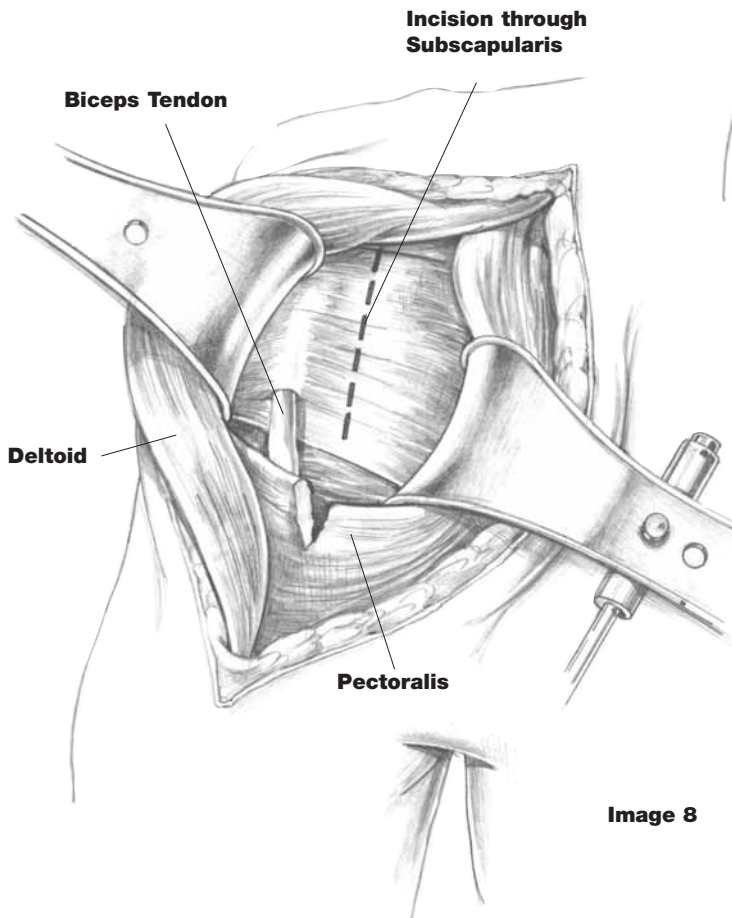


Image 8

Capsulotomy

Prior to performing the anterior capsulotomy for exposure, the surgeon should determine the amount of passive external rotation available given the degree of soft tissue contracture or bony deformity. If the patient has less than 20° of external rotation passively, prior to capsular release, consideration should be given to performing a coronal Z-plasty lengthening of the anterior structures*. In most cases, a full thickness capsulotomy releasing both subscapularis and capsule simultaneously may be performed for exposure. The vertical limb of the capsulotomy begins 1.5cm to 2cm medial to the biceps tendon. This runs from the rotator interval, superiorly to the inferior margin of the subscapularis tendon distally. A horizontal limb, both superiorly and inferiorly, is then created and traction sutures are placed. [Image 9] In most cases of arthritis of the glenohumeral joint, osteophytic spurring on the inferior portion of the humeral head will result in capsular shortening, loss of external rotation, and will necessitate release to allow exposure of the humeral head. This is best accomplished by placing a retractor within the capsule at the inferior margin of the humeral head, externally rotating the arm, adducting and releasing that capsule intra-articularly, thus avoiding injury to the extracapsular axillary nerve. [Image 10]

TechTip

*An evaluation to determine whether anterior or posterior osteophytes are precluding motion should be conducted prior to performing a coronal Z-plasty.

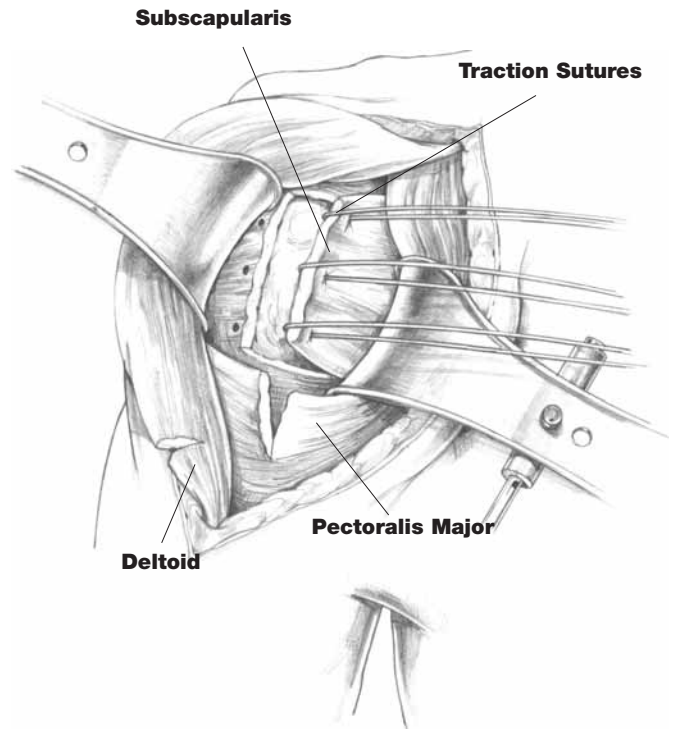


Image 9

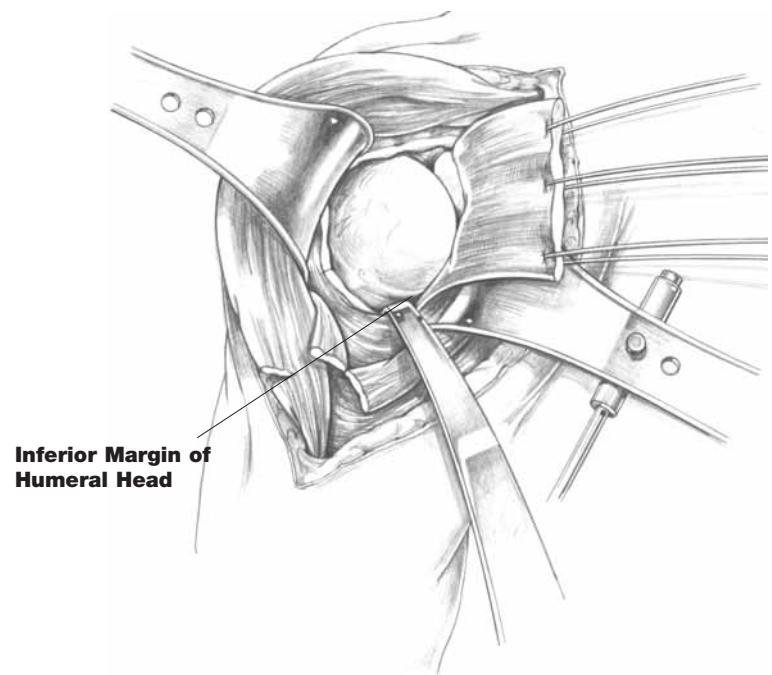


Image 10

Z-Plasty Lengthening for Internal Rotation Contracture

In cases of internal rotation contractures of the shoulder, a coronal lengthening of the anterior subscapularis and capsule will provide an increase in external rotation postoperatively.

The subscapularis is longitudinally dissected off the underlying tuberosity at the level of and immediately adjacent to the biceps tendon, a distance of approximately 1 to 2cm.

[Image 11] As this moves medially, the arm is externally rotated to allow additional exposure of subscapularis and capsular interval. Having brought this to 1 to 2cm medially, a vertical capsulotomy is made, thereby exposing the humeral head. At the time of closure, the medial limb of the subscapularis is repaired to the lateral margin of the capsule, thus lengthening the anterior capsule 1 to 2cm and increasing external rotation by 20°–30°. [Image 12]

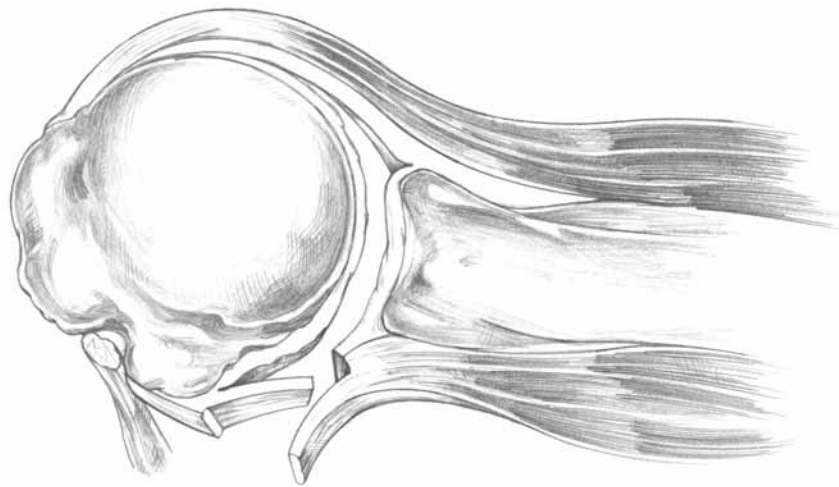


Image 11

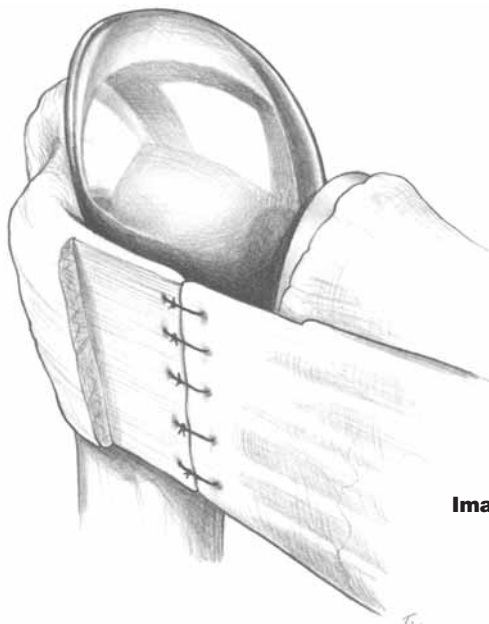
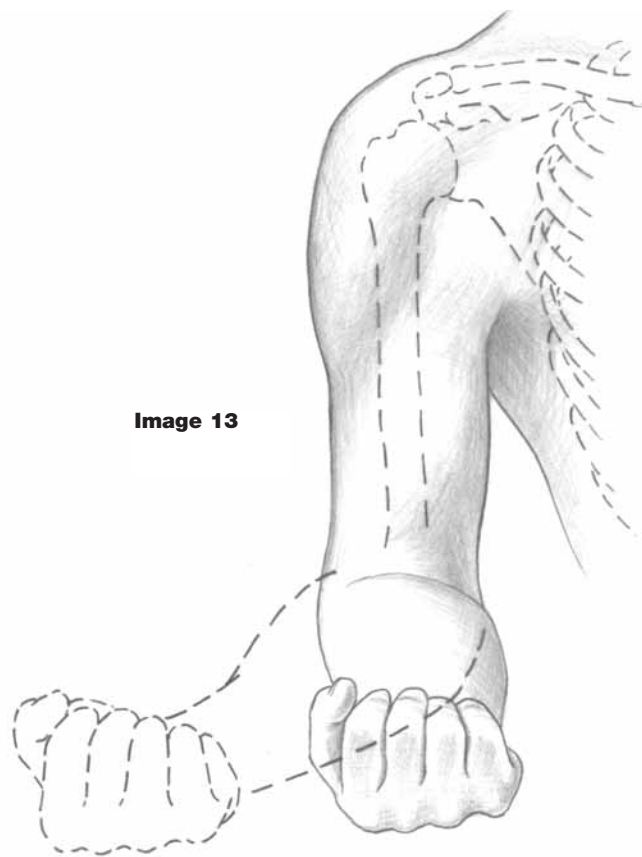


Image 12

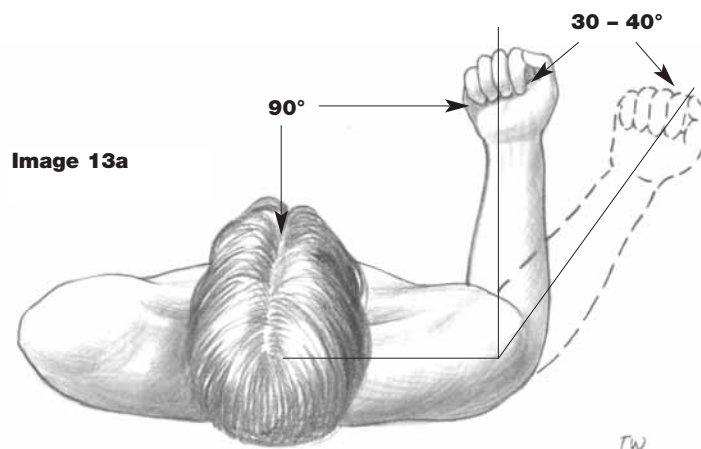
Humeral Head Resection

This step is critical in determining the orientation of the humeral head to the glenoid. Furthermore, the extent of osteophytes, loose bodies, and humeral head deformation needs to be determined pre-operatively with templating and radiographic studies. With the capsulotomy complete and the humeral head delivered for visualization, the articular surface needs to be defined. This may require the removal of osteophytes inferiorly and anteriorly to determine the level of head resection. In most cases, the humeral component should be set in approximately 35°–40° of retroversion.* There are a number of techniques that may be employed to achieve this retroversion. By flexing the elbow 90° and externally rotating the arm 30°–40°, the humeral head cut is made at right angles to the plane of the shaft and head, thereby achieving 30–40 degrees of retroversion. [Images 13 & 13a]



TechTip

*In cases of anterior glenoid erosion as in Rheumatoid patients, increase retroversion prior to resection. In cases of posterior glenoid erosion as in osteoarthritic patients, decrease retroversion prior to resection.



Once the margin of the articular surface is determined, the humeral resection guide is placed on the long axis of the shaft with the arm in 30°–40° of retroversion. The angle of resection (45°) is marked and the humeral cut is initiated.* The guide can be removed and the cut is completed; any residual osteophytes are resected. It is recommended that the resected head be saved for later comparison and sizing of the modular head.

[Image 14]

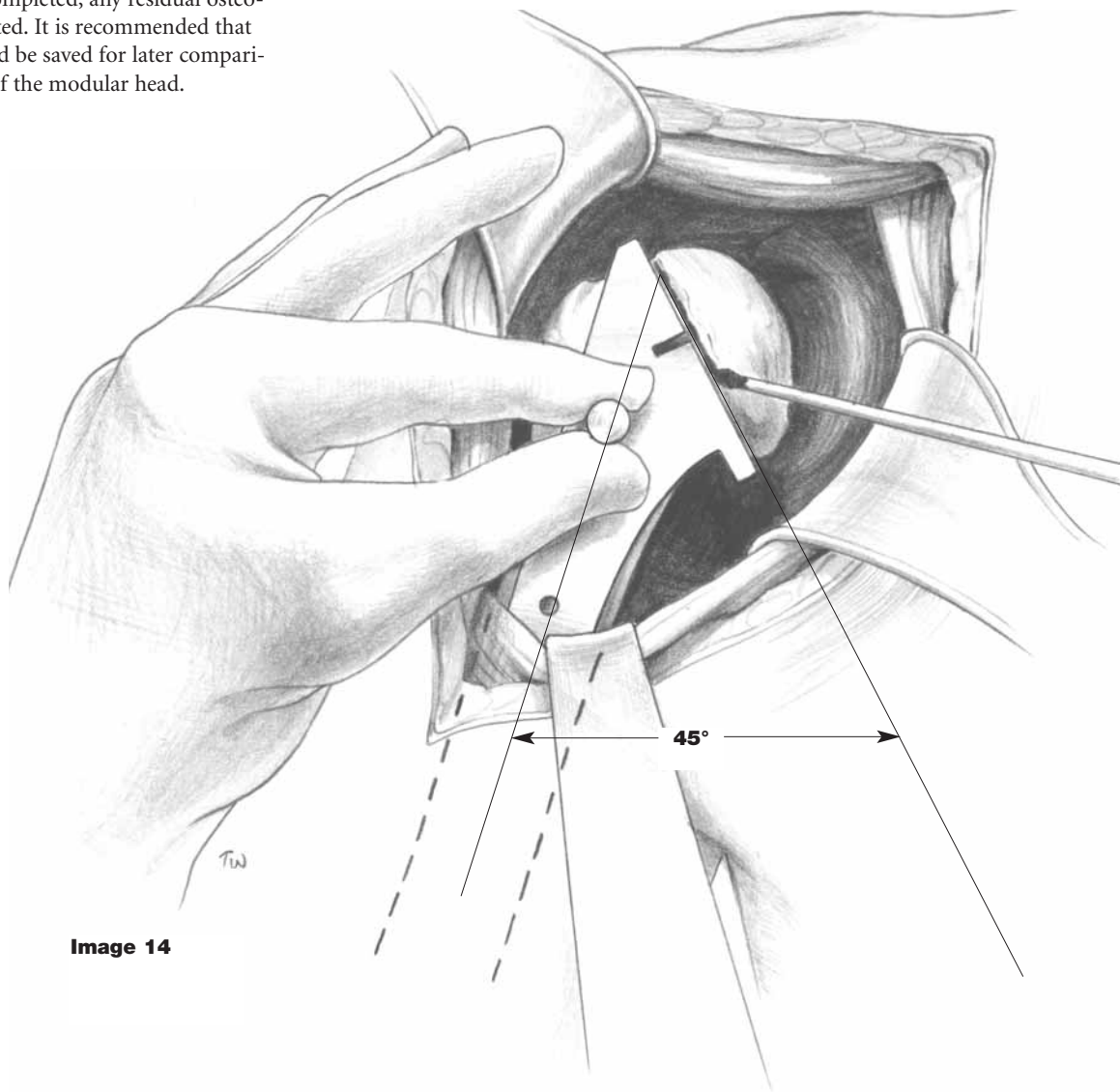


Image 14

TechTips

- * •Care should be taken to protect the biceps tendon and rotator cuff insertion with a small Hohman or Crego retractor during head resection.
- To avoid cutting through the posterior capsule, complete the cut with an osteotome.
- Don't cut too steep an inclination. This would lead to tuberosity impingement.

Glenoid Preparation Pegged Component

Preoperative glenoid assessment is necessary via axillary view, x-ray or CT scan to determine the presence of defects such as excessive wear, intraosseous cysts, or previous fractures. If significant, any of these may require grafting. By means of gentle abduction, external rotation and slight extension, the humeral shaft is brought posterior and a retractor is placed about the posterior lip of the glenoid. Similarly, a fork retractor is placed on the anterior rim of the glenoid to bring the capsule out of the way. Remaining labral tissue is excised and the margins of the glenoid are defined. [Image 15]

In cases where residual glenoid cartilage is present, a curette is used to remove the cartilage then the spherical reamer is used to prepare the glenoid face (not fossa). [Image 16]

TechTips

Glenoid exposure can be a difficult part of total shoulder arthroplasty. The following represent suggestions for improving glenoid exposure:

- Complete release of metaphyseal capsule anteriorly and posteriorly.
- Excision of inferior humeral osteophytes and release of the posterior capsule using a blunt periosteal elevator.
- Resection of posterior humeral osteophytes.
- Release by blunt technique the posterior capsule as it attaches to the posterior aspect of the glenoid.

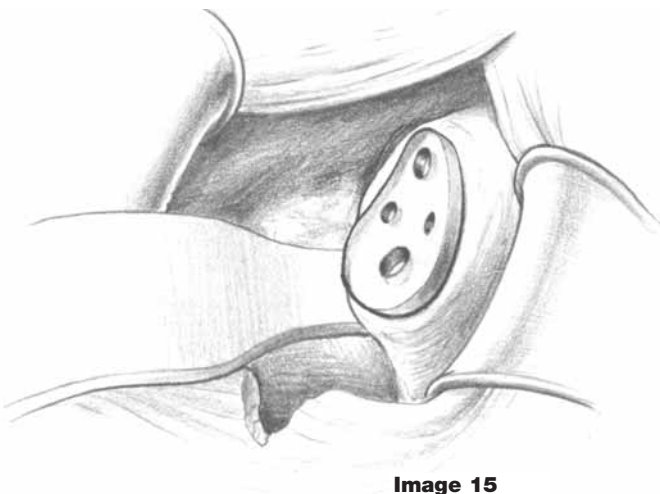
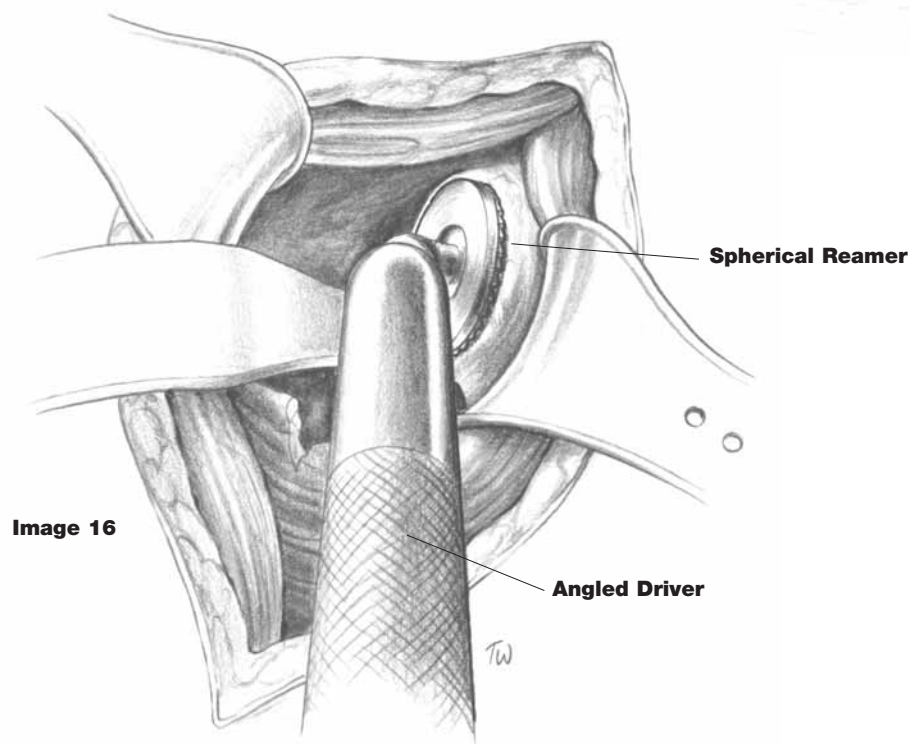


Image 15



TechTip

To mark glenoid peg holes, use cautery to score the surface through the brown sizing guide. Then create starter hole with burr. Then drill. Finish all holes with hand chuck to make sure pegs have bottomed out.

After glenoid sizing is completed with the surface trials, the superior/inferior and anterior/posterior axis is marked. [Image 17] Using these markings as reference, the appropriate size drill guide is centered on the glenoid. The superior drill hole is prepared first, using the universal drill/driver. [Image 18]

The drill guide is reversed and the end with the superior post is inserted into the drilled hole. In similar fashion, the inferior and, in the case of the two larger glenoid components, the anterior and posterior drill holes are made.

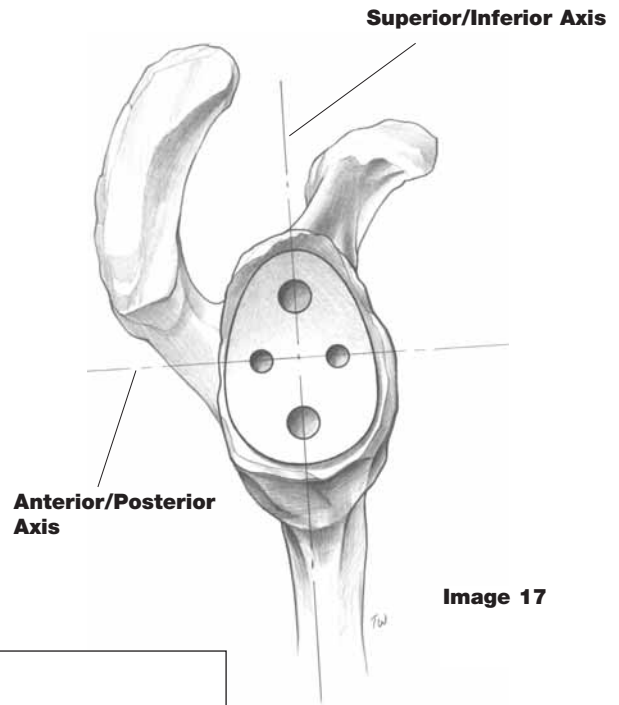


Image 17

Drill Bits		
Catalog No.	Description	Use
5900-2081	Small	Prepare peg holes anterior and posterior on large glenoid components
5900-2082	Large	Prepare superior and inferior peg holes
5900-2084	Starter Drill	Starter drill for peg holes

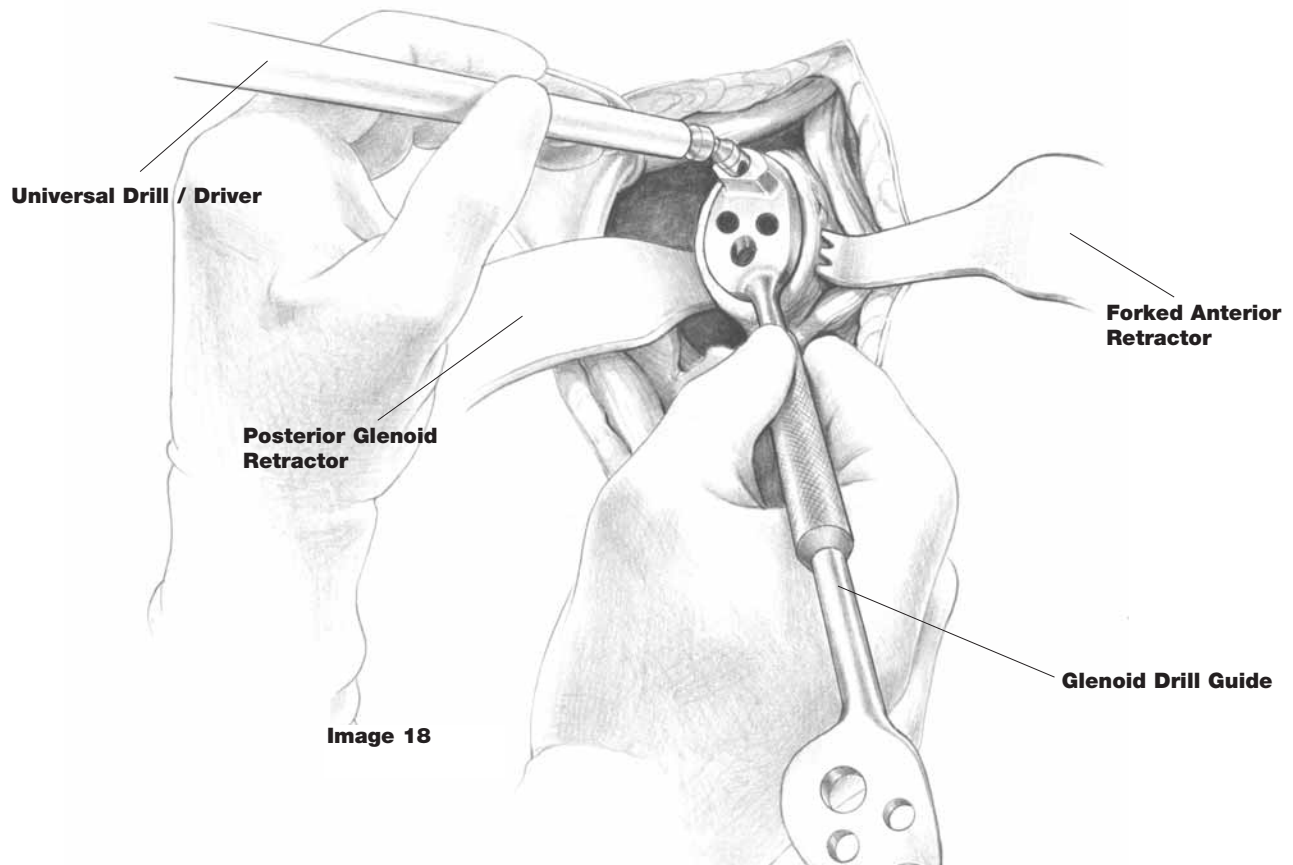


Image 18

Pegged Glenoid Placement

A trial reduction is then performed to make certain that there is a uniform seating of the glenoid component and that none of the pegs are bottoming out. Furthermore, each of the peg holes is checked to make certain that there is no break in the cortical shell.

[Image 19] In preparation for cementation, small pledgets of Gelfoam™ impregnated with thrombin are placed into each of the drill holes for hemostasis. A single batch of polymethylmethacrylate is mixed, the Gelfoam™ is removed and each of the holes is pressurized using a cement delivery system. [Image 20] The implant is then placed and held by using the glenoid pusher or thumb until completion of polymerization. [Image 20a] All excess cement about the glenoid margin is removed.

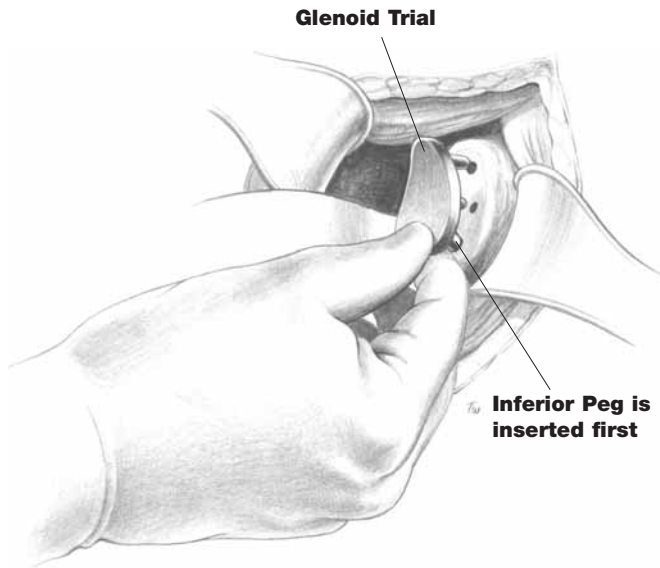


Image 19

TechTip

For hemostasis of glenoid peg or keel holes—pack with epinephrine-soaked pledget sponges → then dry sponge → then cement. Alternatives can be gelfoam or thrombin.

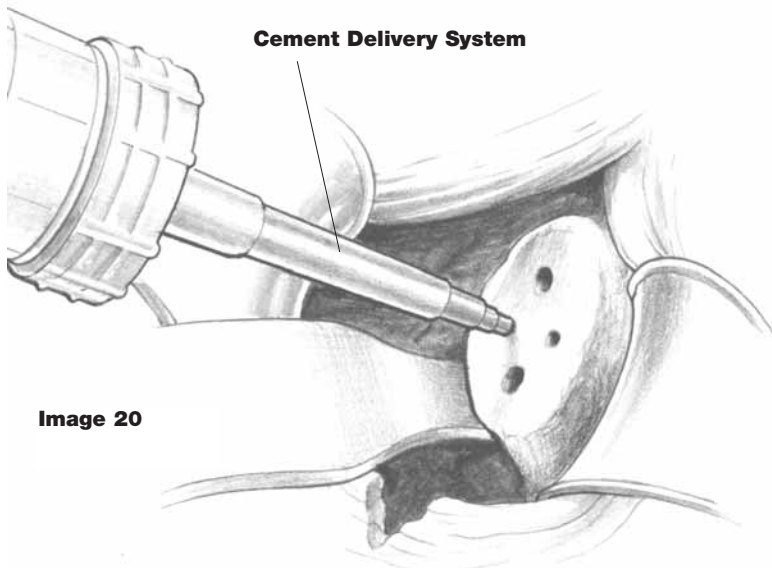
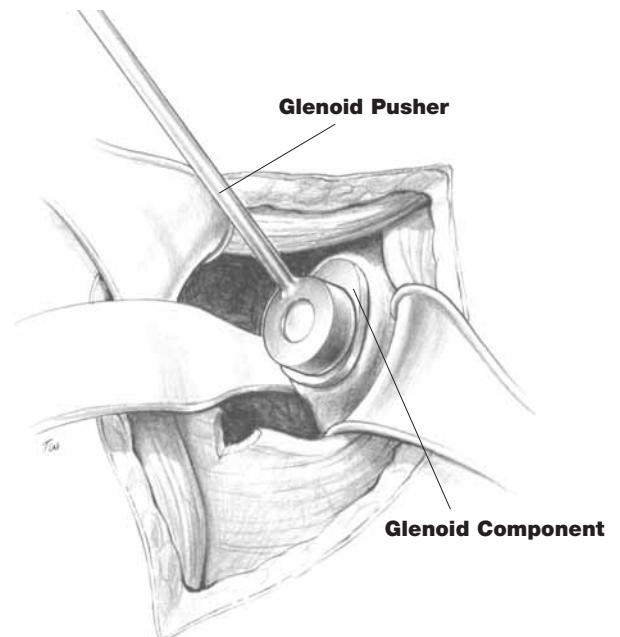


Image 20

Image 20a



Keeled Glenoid Preparation

Preoperative glenoid assessment is necessary to determine the presence of defects such as excessive wear, cysts, or previous trauma. If significant, any of these may require grafting. By means of gentle abduction, external rotation and slight extension, the humeral shaft is moved posteriorly and a posterior glenoid retractor is placed on the glenoid rim. Similarly, an anterior glenoid retractor is placed on the anterior rim of the glenoid to bring the capsule out of the way. Remaining labral tissue is excised and the margins of the glenoid are defined.

In cases where residual glenoid cartilage, or a non-uniform glenoid surface is present, a spherical reamer is used to prepare the glenoid fossa and provide a uniform surface for instrumentation and implant placement. The glenoid fossa is sized using surface templates. [Image 21] When the appropriate coverage and size has been determined, a matching spherical reamer is then used to prepare the surface. [Image 22] The preparation is then checked with the surface templates to ensure a proper curvature has been achieved.

The appropriate sized keeled glenoid guide is located on the glenoid fossa and the preparation is then marked using methylene blue or electrocautery. [Image 23] The keeled glenoid guides are in left and right configurations. The slot in the guide is marked with a line for the corresponding sized keel's width and length. The guide allows for a 1mm cement mantle. If a larger cement mantle is required, the preparation may be opened in a similar fashion. The keeled guide is then removed and the bone is prepared using a high speed burr or similar instrument.

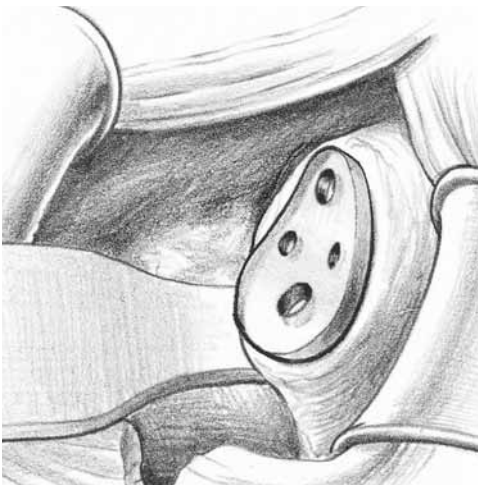


Image 21

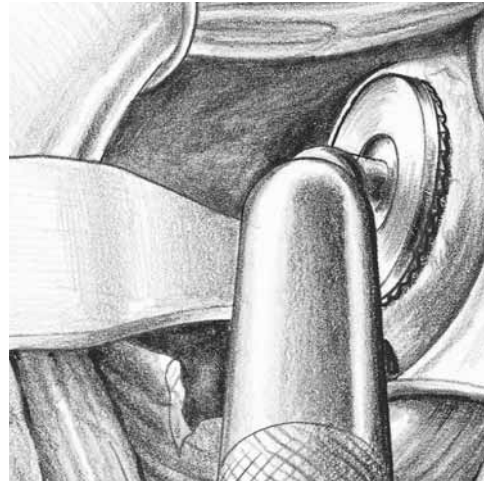


Image 22

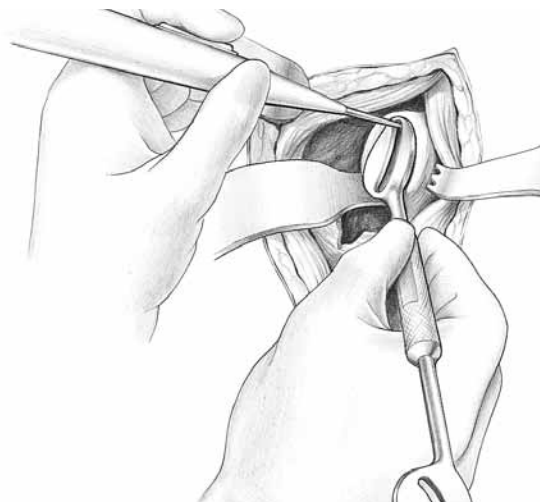


Image 23

Keeled Glenoid Placement

The appropriate sized keeled glenoid trial is then introduced in the preparation and a trial reduction is performed to make certain there is a uniform seating of the component and that the keel is not bottoming out.

[Image 24] In preparation for cementation, small pledgets of Gelfoam™ impregnated with thrombin are placed into the glenoid vault for hemostasis. A single batch of polymethylmethacrylate is mixed, the Gelfoam™ is removed and the preparation is pressurized using a cement delivery system. [Image 25] The implant is then placed and held until polymerization is complete. [Image 26] All excess cement about the glenoid margin is removed.

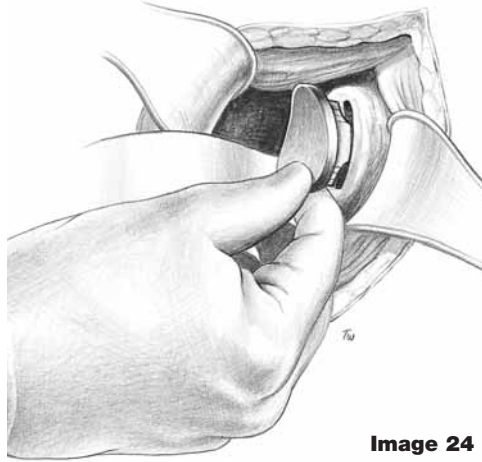


Image 24

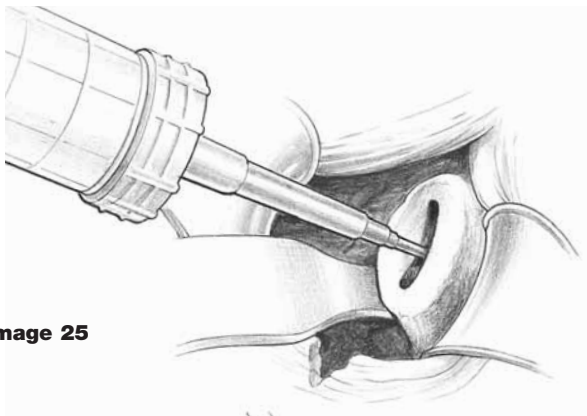


Image 25

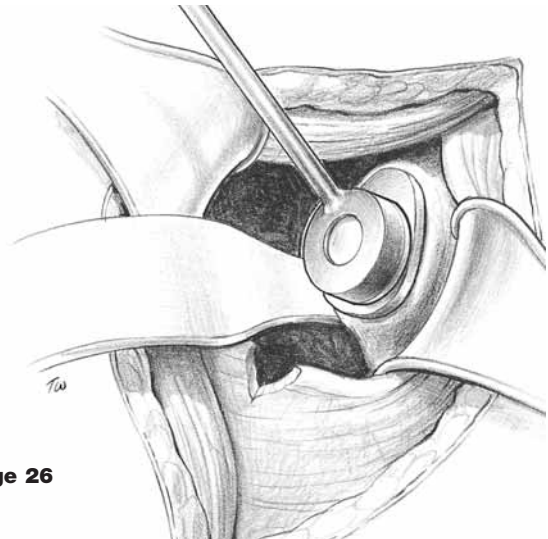


Image 26

Humeral Canal Preparation

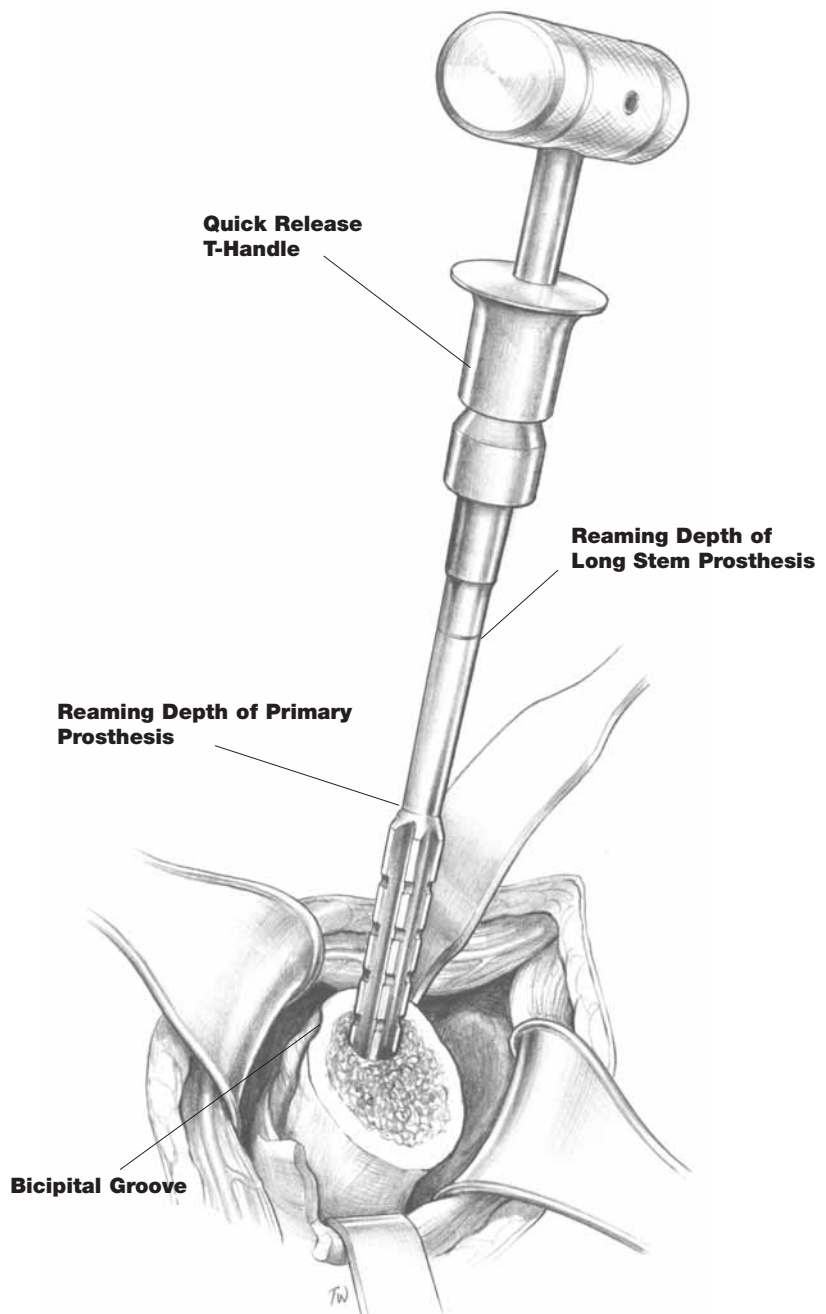
Reaming: A blunt bone hook is placed within the intramedullary canal and gently pulled laterally to deliver the humerus anterior to the glenoid. Retractors are placed beneath the rotator cuff tissue superiorly and medially to provide adequate exposure of the canal for reaming. Reaming begins with bullet-tip straight reamers. Placement should be somewhat lateral and just posterior to the bicipital groove. This will allow for appropriate position within the canal.

Reaming should be performed manually using the quick release T-handle and be progressive in size until friction is felt as the reamer contacts cortical bone. Reaming depth into the canal is to the top of the cutting flutes for a primary prosthesis. If a long stem prosthesis is indicated, reaming depth is to the circumferential groove positioned at the top of the reamer shaft. [Image 27] Note that the last reamer size used will match the distal size of the implant to be used in a pressfit application.

TechTip

It is important not to let the coracoid/conjoined tendon crowd posterior humeral metaphysis and force your canal entry too anterior. IM entry point should be slightly (2mm) posterior over metaphysis and valgus.

Image 27



Broaching: When reaming is completed, progressive sizing of the canal with humeral broaches is performed. The broach is attached to the quick release broach handle using a grooved trunnion. The broach and handle will lock together with the lateral keyway and can be disengaged by the thumb lever. Impaction with a mallet should be performed with careful attention to ensure that the lateral margin of the broach is oriented just posterior [5–10mm] to the bicipital groove. This will incorporate the appropriate degree of retroversion. The broach should be seated to the circumferential groove around the proximal section. Do not seat the broach beyond this line. [Image 28] The last broach used for reaming can be left in place and modular head trials can be tested. [Image 29]

Image 28

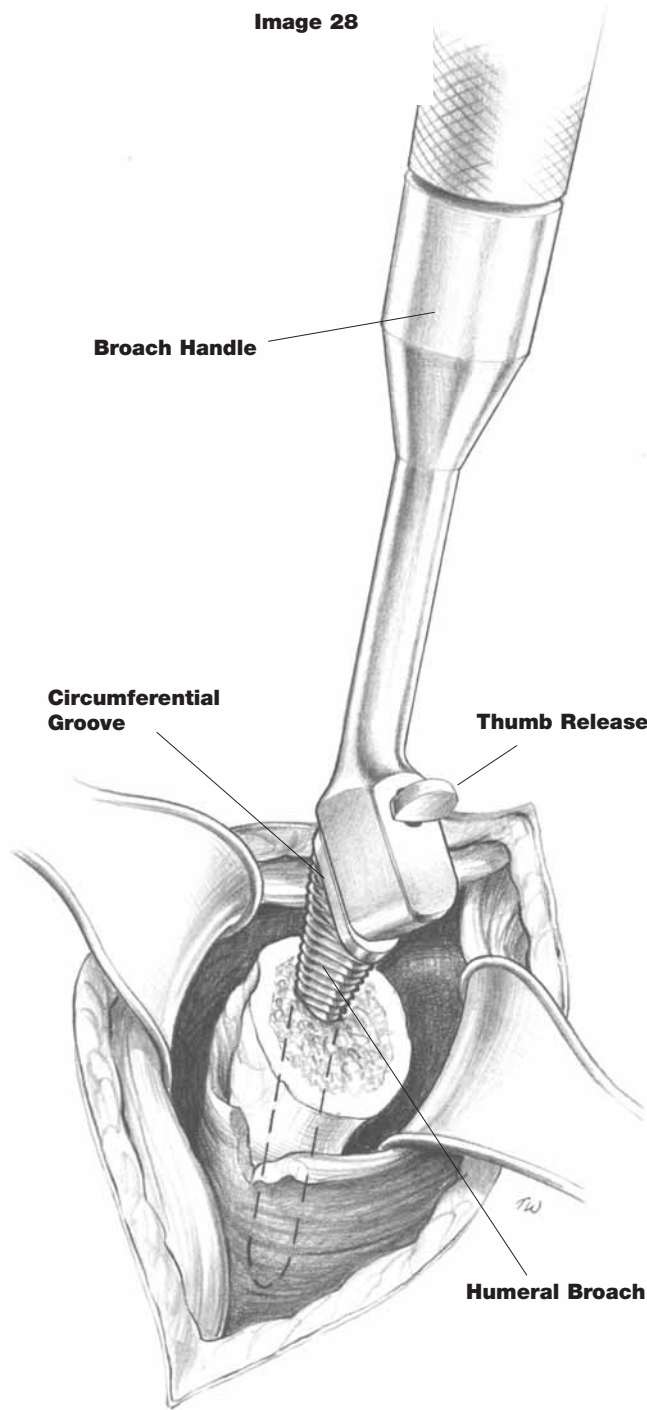
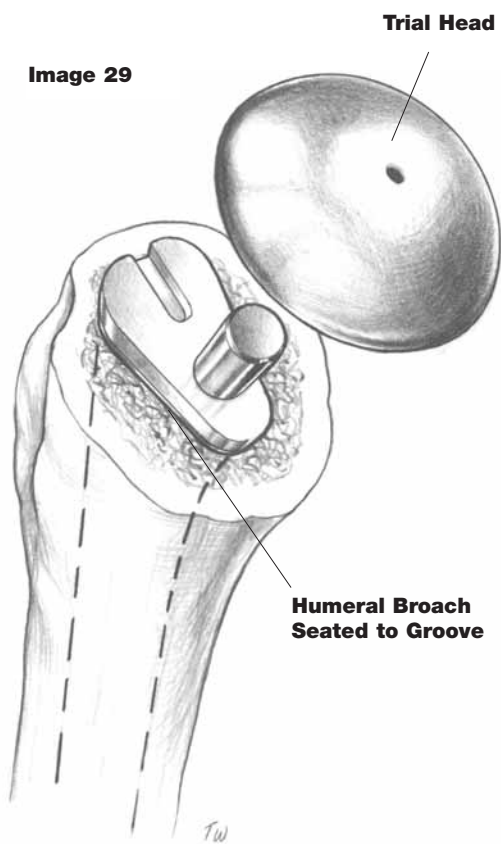


Image 29



TechTip

The humeral head height should be at or slightly superior to the greater tuberosity height.

Modular Head Selection: The sizing of the modular head is important for success of this procedure. The previously resected head is compared with the modular trial head to determine both width and height. When a glenoid is used, this lateralizes the joint line so the humeral head height will be 4mm less than the resected head. [Images 30–30A] Consideration must be given to head deformity and rotator cuff tensioning. The ideal modular head should achieve the following: 1) proper tensioning of the rotator cuff tendons; 2) good match to anterior/posterior humeral width; 3) top of the modular head equal to or slightly superior to greater tuberosity; 4) enables 50% translation of the humeral head on the glenoid both anteriorly and posteriorly; 5) enables internal rotation with forearm across abdomen, and 30–40° external rotation.

Fin Cutter: With humeral stem size chosen, the fin cutter is now introduced. Paying careful attention to orientation, the lateral fin of the fin cutter should line up with the path cut by the humeral broach. Final version will be established when the anteroposterior fins of the cutter are seated flush to the humerus. Only one fin cutter needs to be introduced; which should match the last size of broach and reamer used. [Image 31]

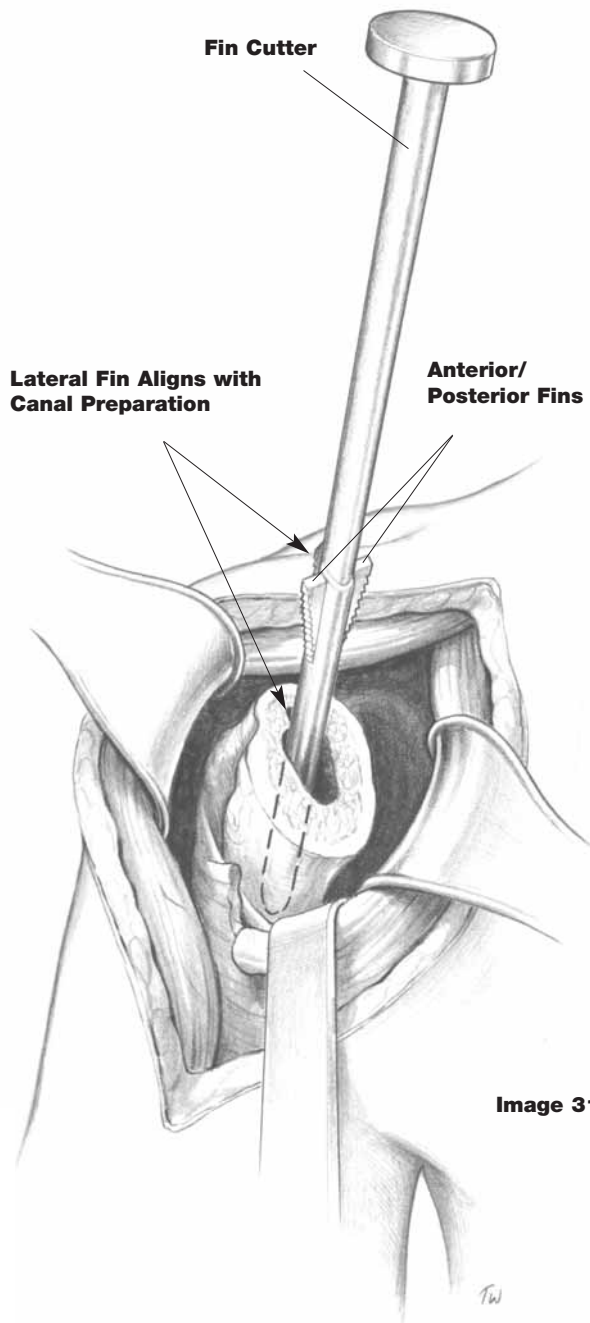


Image 31

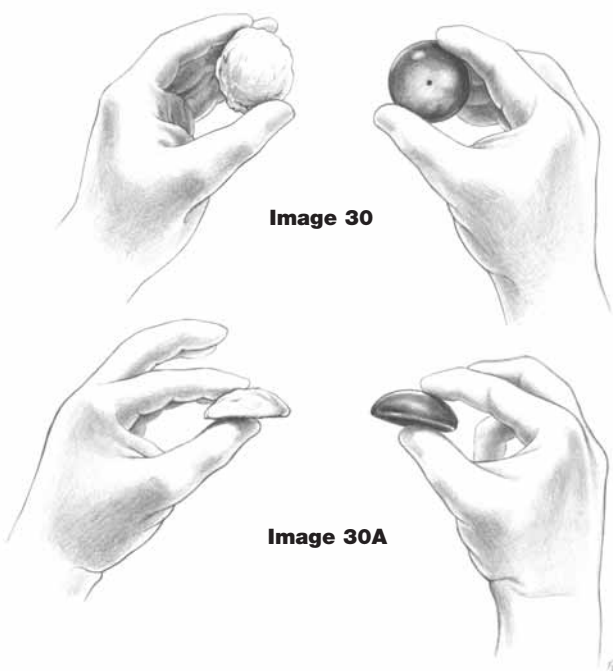


Image 30

Image 30A

TechTips

The following criteria should be met if appropriate head size has been achieved:

- Internal rotation of the arm with the elbow flexed 90° to the abdomen without undue tension on the posterior capsule.
- External rotation to 40°–45° while being able to bring the anterior capsular structures back to their original site of release.
- External rotation to 90° without dislocation of the humeral head on the glenoid.
- 50% translation of the humeral head on the glenoid both anteriorly and posteriorly with a slight inferior translation.
- The height of the modular head should be at or greater than that of the greater tuberosity.
- Additionally, inspect glenoid to see if you need to alter degree of retroversion.

Humeral Component Placement

A decision is made regarding cementation once both humeral head and modular head implant sizes have been determined. In most cases, a pressfit of the humeral component will be possible. If there is a question of the adequacy of the fit or the quality of the cortical bone, cementation is a viable option with a move to a smaller sized humeral component.

Cement Application: After removal of the humeral broach, the canal is thoroughly cleansed and dried. The humeral component two distal sizes smaller than the last size humeral broach and fin cutter used correspond to the correct cemented stem size. [Image 32] Varying cement techniques can be utilized per patient indications. The component is introduced into the canal using the stem impactor which is placed over the trunnion and into the version hole located lateral to the trunnion. Continue to introduce until final placement is achieved. Be sure to remove any excess cement. [Image 33]

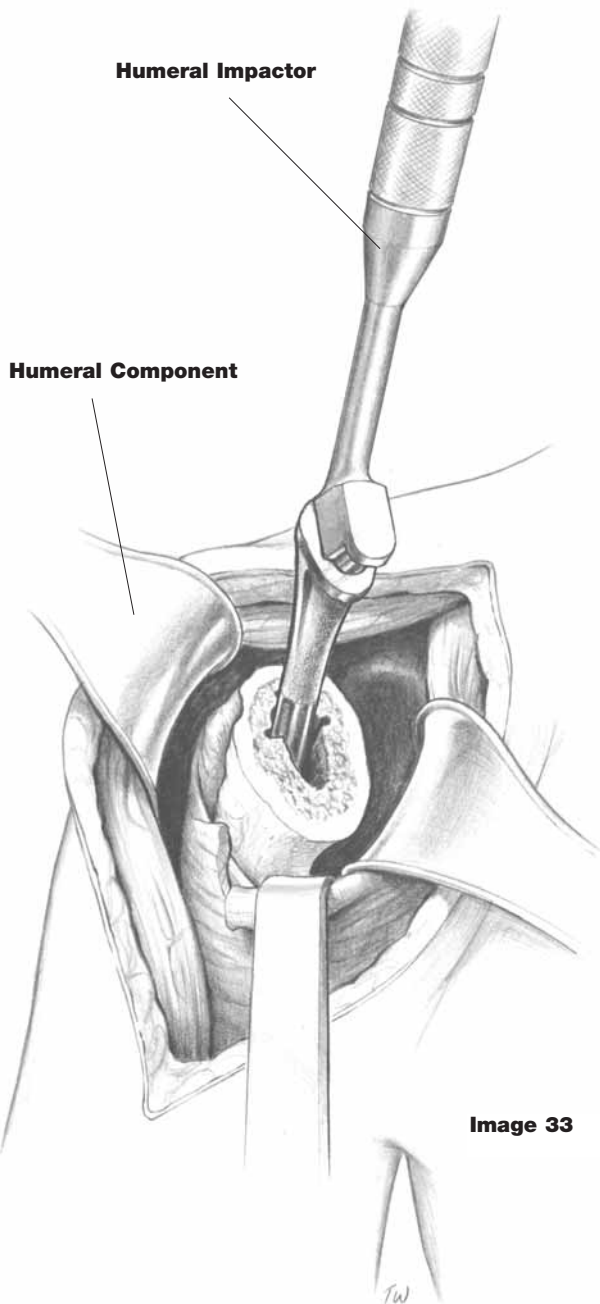


Image 33

Image 32

Cemented Application				
Implant Catalog #	Distal Size	Cylindrical Reamer Catalog #	Broach Catalog #	Fin Cutter Catalog #
5351-4103	7mm	5900-6009	5900-7105	5900-8105
5351-4104	8mm	5900-6010	5900-7107	5900-8107
5351-4105	9mm	5900-6011	5900-7107	5900-8107
5351-4106	10mm	5900-6012	5900-7109	5900-8109
5351-4107	11mm	5900-6013	5900-7109	5900-8109
5351-4108	12mm	5900-6014	5900-7111	5900-8111
5351-4109	13mm	5900-6015	5900-7111	5900-8111
5351-4110	14mm	5900-6016	5900-7113	5900-8113
5351-4111	15mm	5900-6017	5900-7113	5900-8113

Pressfit Application: After removal of the humeral broach, the correct sized implant [Image 34] is inserted into the humeral canal. Attention must be paid to version and to aligning the fins of the prosthesis with those of the humeral canal. Final seating of the implant is achieved using the stem impactor as mentioned above. [Image 35] As with either application, trial heads may again be used to evaluate range of motion adequacy, soft tissue tensioning and to check for impingement.

Humeral Bearing Head Attachment: Thoroughly clean and dry the trunnion on the humeral component. Place the bearing head on the trunnion and secure it in place using the humeral head impactor and a mallet. Several sharp mallet blows are used to seat the head. Be sure the angle of the driver is in line with the axis of the trunnion (90° to collar face). [Image 36]

Image 34

Pressfit Application

Implant Catalog #	Distal Size	Cylindrical Reamer Catalog #	Broach Catalog #	Fin Cutter Catalog #
5351-4103	7mm	5900-6007	5900-7103	5900-8103
5351-4104	8mm	5900-6008	5900-7105	5900-8105
5351-4105	9mm	5900-6009	5900-7105	5900-8105
5351-4106	10mm	5900-6010	5900-7107	5900-8107
5351-4107	11mm	5900-6011	5900-7107	5900-8107
5351-4108	12mm	5900-6012	5900-7109	5900-8109
5351-4109	13mm	5900-6013	5900-7109	5900-8109
5351-4110	14mm	5900-6014	5900-7111	5900-8111
5351-4111	15mm	5900-6015	5900-7111	5900-8111
5351-4112	16mm	5900-6016	5900-7113	5900-8113
5351-4113	17mm	5900-6017	5900-7113	5900-8113

NOTE: When using a long stem prosthesis, use the same sequence.

Humeral Impactor

Humeral Component

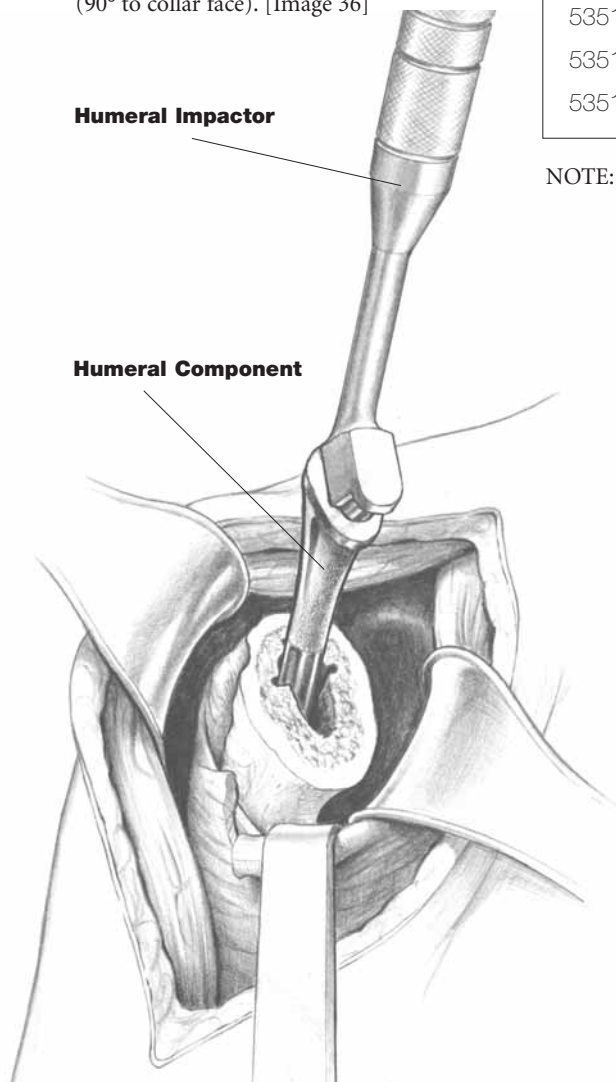
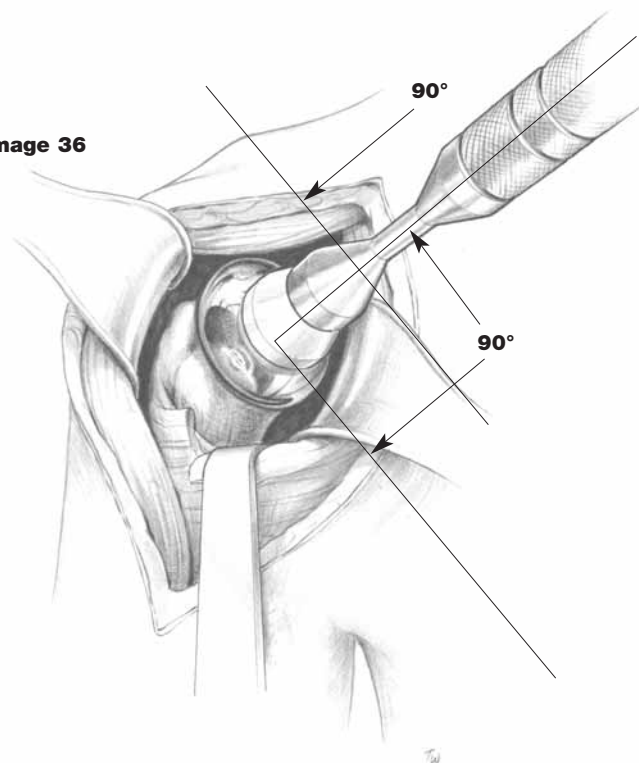


Image 35

Image 36



Repair of Capsulotomy

The shoulder is reduced and stability is confirmed. The anterior capsulotomy and subscapularis are repaired anatomically with non absorbable suture material. Attention should be directed not only to the anterior capsule, but also the rotator interval. In cases of a coronal Z-plasty, the lateral margin of the subscapularis is repaired to the residual stump of lateral capsule [reference Image 11]. The deltopectoral interval is allowed to re-approximate itself and is loosely repaired with 3.0 absorbable suture material. Subcutaneous and skin layers are closed with 3.0 and 4.0 absorbable sutures. Suction drainage may be used as needed.

Immediate Post-Operative Care

Patients may be placed in a cold therapy device for postoperative cryotherapy and a simple sling. Physical therapy is initiated on the first or second postoperative day, as patient comfort allows. Therapy should consist of gentle assisted forward elevation and external rotation as well as pendulum exercises. Patients may be discharged on the second or third postoperative day and started on a formal physical therapy program.

TechTip

Closure: The subscapularis can be repaired to the anterior humeral neck through drill holes if more external rotation is needed.

Postoperative Care, Indications, Contraindications, Precautions, Warnings and Adverse Effects

Description

Stryker® shoulder prostheses consist of both humeral and glenoid components. Depending on design, the humeral components may be used in conjunction with a glenoid component for conventional total shoulder arthroplasty or to articulate directly with the anatomic glenoid in a hemi-shoulder application. The components are intended for implantation within the humeral and glenoid fossa preparations in cemented or cementless applications dependent upon device design (consult component package labeling for application restrictions).

Humeral Components: The humeral component is available in modular design. The selection of the appropriate humeral component is dependent upon the type of arthroplasty intended, bone geometry and the type of fixation. The modular humeral design consists of both humeral stem and interchangeable humeral head components. The modular head components are available in diameters ranging from 40mm to 55mm in 5mm increments and in selected thicknesses ranging from 12mm to 34mm.

Glenoid Components: The glenoid component consists of an all-polyethylene design available in an array of sizes. Each size has a thickness of 4mm.

Materials:

- **ASTM F-1537 Cobalt chromium alloy**
Humeral heads,
- **ASTM F-90 Cobalt chromium alloy**
Glenoid x-ray marking wire
- **ASTM F-136 Titanium 6AL-4V ELI alloy**
Humeral stem component
- **ASTM F-648 ultra-high molecular weight**
Glenoid component polyethylene (UHMWPE)

Indications

- Aseptic necrosis of the humeral head.
- Painful, disabling joint disease of the shoulder resulting from: degenerative arthritis, rheumatoid arthritis, or post-traumatic arthritis.
- Proximal humeral fracture and/or dislocation.
- Revision of previous unsuccessful total shoulder replacement, resurfacing or other procedure.
- Clinical management problems where arthrodesis or alternative reconstructive techniques are less likely to achieve satisfactory results.

Contraindications

- Any active or suspected latent infection in or about the shoulder joint.
- Any mental or neuromuscular disorder which would create an unacceptable risk of prosthesis instability, prosthesis fixation failure, or complications in postoperative care.
- Bone stock compromised by disease, infection or prior implantation which cannot provide adequate support and/or fixation to the prosthesis.
- Skeletal immaturity.
- Absent, irreparable or non-functioning rotator cuff and other essential muscles.
- Patients whose anticipated activities would impose high stresses on the prosthesis and its fixation.
- Obesity. An overweight or obese patient can produce loads on the prosthesis which can lead to failure of fixation of the device or to failure of the device itself.

Precautions

- Before clinical use, the surgeon should thoroughly understand all aspects of the surgical procedure and limitations of the device. Patients should be instructed in the limitations of the prosthesis, including, but not limited to, the impact of excessive loading through patient weight or activity, and be taught to govern their activities accordingly. If the patient is involved in an occupation or activity which includes substantial walking, running, lifting, or muscle strain, the resultant forces can cause failure of the fixation, the device, or both. The prosthesis will not restore function to the level expected with normal healthy bone, and the patient should not have unrealistic functional expectations.
- Appropriate selection, placement and fixation of the shoulder components are critical factors which affect implant service life. As in the case of all prosthetic implants, these components are affected by numerous biologic, biomechanic and other extrinsic factors, thereby limiting the service life and durability of the product. Accordingly, strict adherence to the indications, contraindications, precautions and warnings for this product is essential to potentially maximize its service life.
- Care must be taken to protect the components and any polished bearing surfaces from being marred, nicked or notched as a result of contact with metal or abrasive objects.

Utilization and Implantation

- The recommended trial components should be used for size determination, trial reduction and range of motion evaluation, thus preserving the integrity of the actual implants and their sterile packaging.
- Radiographic templates are available to assist in the preoperative prediction of component size and style.
- The Stryker Surgical Protocols provide additional procedural information.

Warnings

- Discard all damaged or mishandled implants.
- Never reuse an implant, even though it may appear undamaged.
- Polished bearing areas must not come in contact with hard or abrasive surfaces.
- Bearing areas must always be clean and free of debris prior to assembly.
- Contouring and bending of an implant may reduce its fatigue strength and cause failure under load.
- Care should be taken not to cut through surgical gloves when handling any sharp-edged orthopaedic device.
- Stryker strongly advises against the use of another manufacturer's component with any Stryker shoulder component. Any such use will negate the responsibility of Stryker for the performance of the resulting mixed component implant.
- Removal of an unloosened implant may require the use of special instruments to disrupt the interface at the implant surface.
- Return all packages with flaws in the sterile barrier to the supplier. Do not resterilize.
- Loosening of total shoulder components can occur. Early mechanical loosening may result from inadequate initial fixation, latent infection, premature loading of the prosthesis or trauma. Late loosening may result from trauma, infection, biological complications, including osteolysis, or mechanical problems, with the subsequent possibility of bone erosion and/or pain.
- Fatigue fracture of total shoulder components has occurred in a small percentage of cases.
- Peripheral neuropathies, nerve damage, circulatory compromise and heterotopic bone formation may occur.
- Serious complications may be associated with any total joint replacement. These complications include, but are not limited to: genitourinary disorders; gastrointestinal disorders; vascular disorders, including thrombus; bronchopulmonary disorders, including emboli, myocardial infarction or death.

Adverse Effects

- While the expected life of total shoulder replacement components is difficult to estimate, it is finite. These components are made of foreign materials which are placed within the body for the potential restoration of mobility or reduction of pain. However, due to the many biological, mechanical and physicochemical factors which affect these devices, but cannot be evaluated in vivo, the components cannot be expected to indefinitely withstand the activity level and loads of normal healthy bone.
- Dislocation of the total shoulder prosthesis can occur due to inappropriate patient activity, trauma or other biomechanical considerations.
- Wear of polyethylene components has occurred and literature reports have associated its occurrence with bone resorption, loosening and infection.
- With all implant devices, asymptomatic, localized progressive bone resorption (osteolysis) may occur around the prosthetic components as a consequence of foreign-body reaction to the particulate matter of cement, metal, ultra-high molecular weight polyethylene (UHMWPE) and/or ceramic. Particulate is generated by interaction between components, as well as between components and bone, primarily through wear mechanisms of adhesion, abrasion and fatigue. Secondly, particulate can also be generated by third-body wear. Osteolysis can lead to future complications, including loosening, necessitating the removal and replacement of prosthetic components.
- Metal sensitivity reactions have been reported following joint replacement.
- Adverse effects may necessitate reoperation, arthrodesis of the involved joint and/or amputation of the limb.

Sterilization

- The packaging of all sterile products should be inspected for flaws in the sterile barrier before opening. In the presence of such a flaw, the product must be assumed non-sterile. Special trial prostheses are available to avoid having to open any aspect of the sterile package prior to component use.
- Care should be taken to prevent contamination of the component. In the event of contamination, this product must be discarded.
- If the package is opened, but the product is not used, the prosthesis must not be resterilized and must be discarded or returned to the supplier.

CAUTION: Federal law (U.S.A.) restricts this device to sale by or on the order of a licensed physician.

WARNING: THE GLENOID COMPONENT IS INTENDED FOR CEMENTED USE ONLY IN THE U.S.A.



Joint Replacements

Trauma

Spine

Micro Implants

Orthobiologics

Instruments

Interventional Pain

Navigation

Endoscopy

Communications

Patient Handling Equipment

EMS Equipment

325 Corporate Drive
Mahwah, NJ 07430
t: 201 831 5000

www.stryker.com

The information presented in this brochure is intended to demonstrate the breadth of Stryker product offerings. Always refer to the package insert, product label and/or user instructions before using any Stryker product. Surgeons must always rely on their own clinical judgment when deciding which treatments and procedures to use with patients. Products may not be available in all markets. Product availability is subject to the regulatory or medical practices that govern individual markets. Please contact your Stryker representative if you have questions about the availability of Stryker products in your area.

The marks bearing the symbol TM are trademarks of Stryker.
The marks bearing the symbol [®] are registered trademarks of Stryker.

Literature Number: **LSPUE-4**
GC/GS 1.75m 10/04

Copyright © 2004 Stryker
Printed in USA