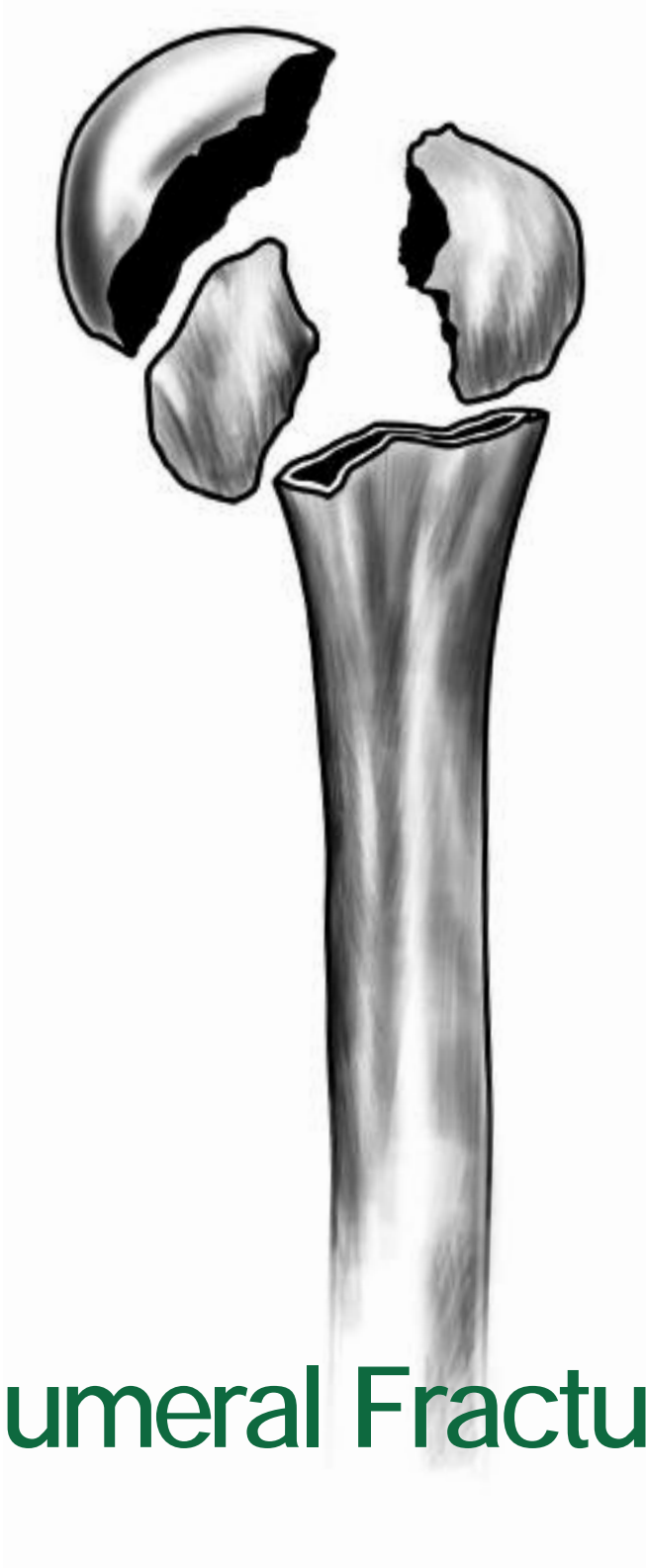



Solar[®] Humeral Fracture System

Surgical Protocol

Table of Contents

Table of Contents

| | |
|--------------------------------------|----|
| Step By Step Procedure..... | 1 |
| Patient Positioning..... | 3 |
| Surgical Exposure | 4 |
| Preparation of Humeral Shaft..... | 7 |
| Trialing of Humeral Components | 7 |
| Cementing..... | 10 |
| Tuberosity Reattachment | 10 |
| Post-Operative Rehabilitation..... | 12 |

This surgical protocol was compiled in conjunction with:

Steven R. Groman, MD
Assistant Clinical Professor of Orthopedics,
Oregon Health Sciences University
Head,
Hand & Upper Extremity Service
Kaiser - Sunnyside Medical Center
Clackamas, Oregon

Step by Step Procedure (At A Glance)

Surgical Technique for Three and Four Part Fractures of the Proximal Humerus

Step 1: Position patient in the semi-beach chair upright position.

Step 2: A long deltopectoral approach is utilized, using the corocoid process, palpated glenohumeral joint and the humerus as guides.

Step 3: Identify biceps tendon and its course. Dissect soft tissue until adequate exposure has been reached.

Step 4: Sequentially hand ream the distal canal until desired diameter is reached (*image 1*).

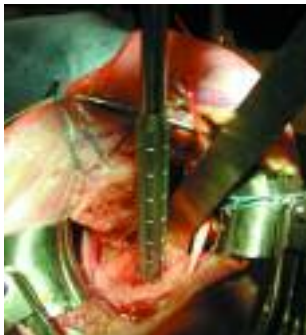

image 1

Step 5: Tuberosities need to be identified, isolated, tagged and immobilized.

Step 6: Place humeral trial stem into humeral canal (*image 2*).

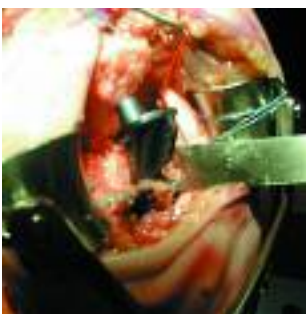


image 2

Step 7: Position lateral fin approximately 1cm posterior to bicipital groove (*image 3*).

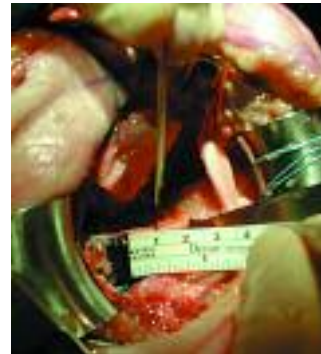

image 3

Step 8: Place a 1cm piece of cortico-cancellous wedge-shaped bone under medical collar of humeral component (*image 4*).

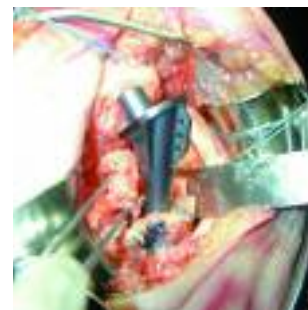


image 4

Step 9: Select the humeral head trial that approximates the diameter and thickness of the patient's humeral head (*image 5*).



image 5

Step 10: Place humeral head onto trial and adjust to achieve proper version and height of prosthesis (*image 6*).

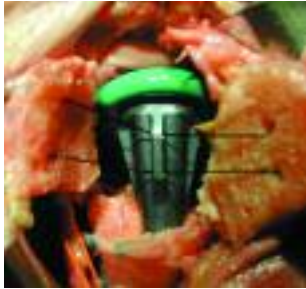

image 6

Step 11: Pull tuberosities around the humeral head, on either side of the humeral component, to assure full closure of tuberosities. Assess for ROM (*image 7*).

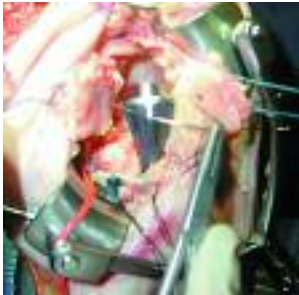


image 7

Step 12: Drill holes in humeral shaft cortex for insertion of anchoring sutures for eventual attachment of tuberosities (*image 8*).

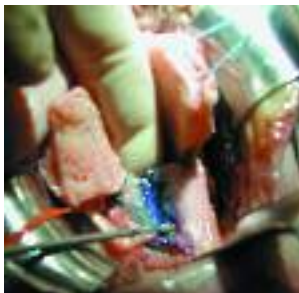

image 8

Step 13: Inject methyl methacrylate cement into the distal canal.

Step 14: Insert humeral component into canal using bone wedge to achieve proper height (*image 9*).

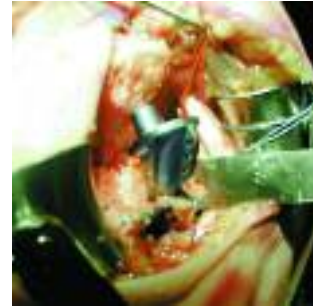

image 9

Step 15: Remove excess cement from incision. Reattach tuberosities to humeral shaft and close incision as required (*image 10*).

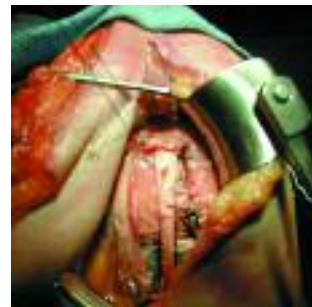

image 10

The Solar[®] Shoulder Fracture System is designed to permit accurate and reproducible implantation of a humeral head replacement for indicated proximal humeral fractures. Proper soft tissue tensioning and humeral component positioning can be achieved to facilitate postoperative mobility and improved function, with the use of this streamlined instrumentation system.

Patient Positioning

The patient should be placed in the semi-upright beach chair position with the operative shoulder off the side of the table so that the arm can be freely moved about (*image1*). This will permit the shoulder to be brought into full adduction and extension, aligned perpendicularly to the operating room floor, in order to gain full access to the humeral diaphysis. The patient's head should be secured to a headrest. Perform pre-operative preparation of arm, including the shoulder, axilla, and adjacent chest wall anteriorly and posteriorly.

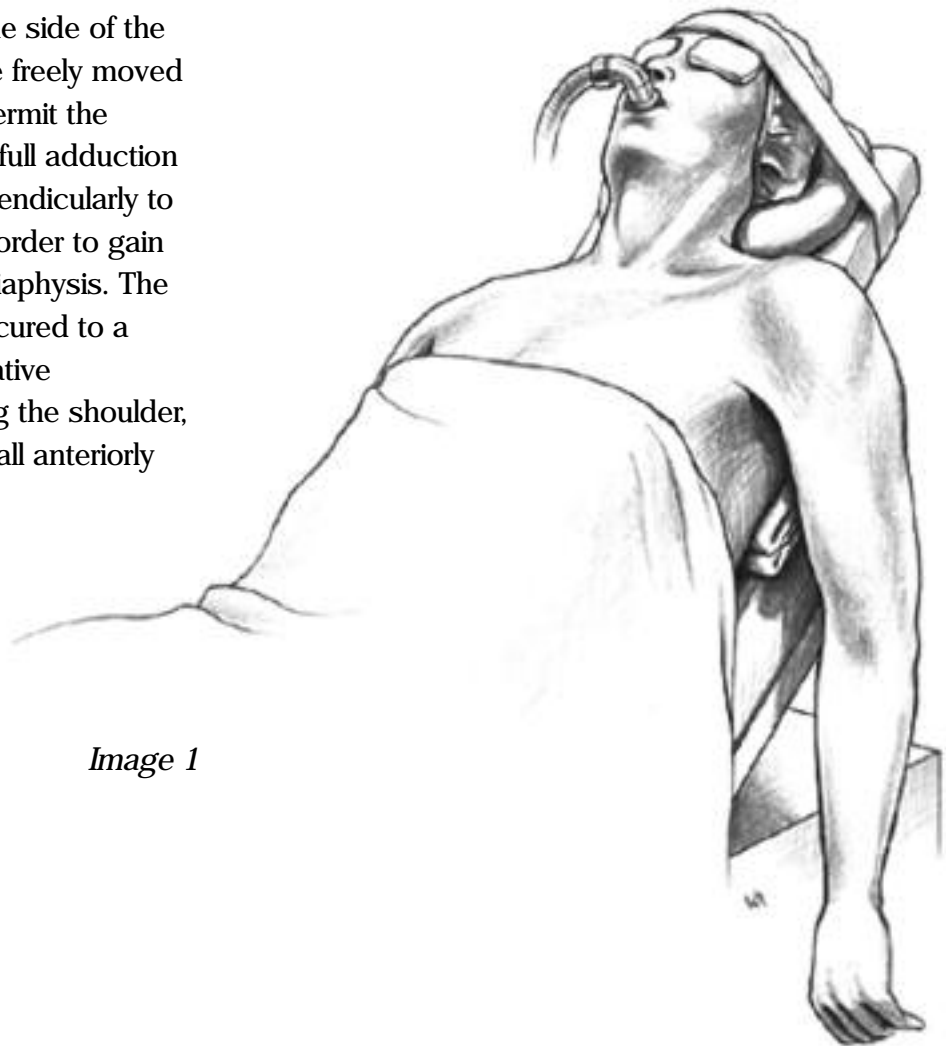


Image 1

Surgical Exposure:

A long deltopectoral approach is utilized, using the coracoid process, palpated glenohumeral joint and the humerus as the guides (*image 2*). Care should be taken in identifying the bony anatomy, as these landmarks can be particularly difficult to find in swollen shoulders or in obese patients.

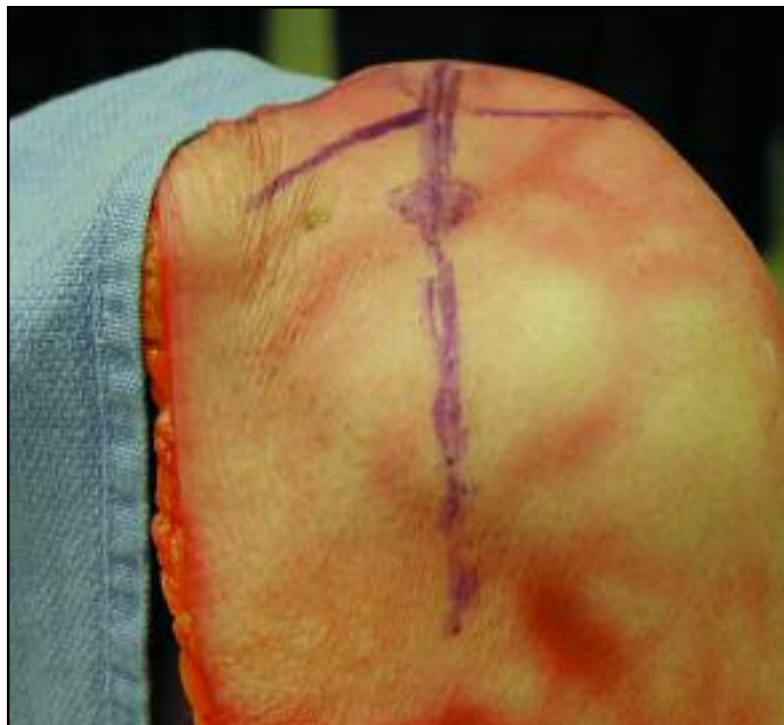


Image 2

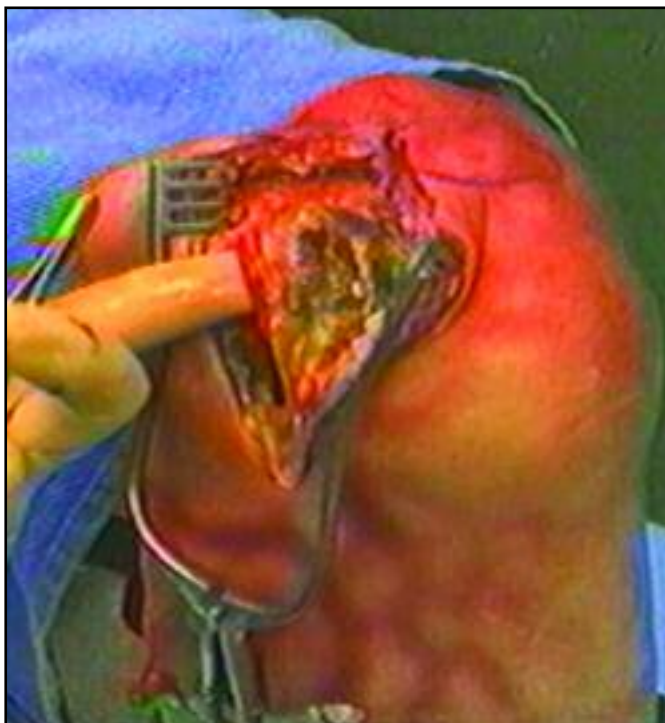


Image 3

The cephalic vein is identified and retracted laterally with the deltoid, as the deltopectoral interval is then developed (*image 3*).

The upper fibers of the tendon of the pectoralis major should be released from the proximal humeral shaft to improve the exposure of the shaft. Retractors are then placed as the dissection is carried deeper.

The greater and lesser tuberosities are identified and the, often-hemorrhagic, subdeltoid bursa is debrided off the humeral head. The axillary nerve is palpated along the anterior border of the subscapularis (*image 4*), and followed in its course beneath the axillary pouch. Its position should be noted and care should be taken to protect the nerve from injury. The biceps tendon should be identified (*image 5*) and the overlying tissue incised to release it from its groove. It is then followed proximally over the superior portion of the humeral head and then the rotator interval. A division is made in the tissues overlying the humeral head in line with this interval. The tuberosities are then separated and grasped with tissue-holding forceps.

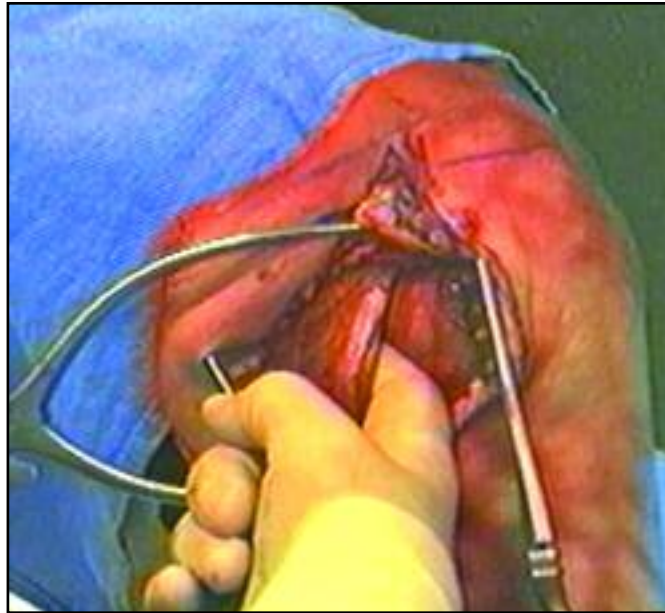


Image 4

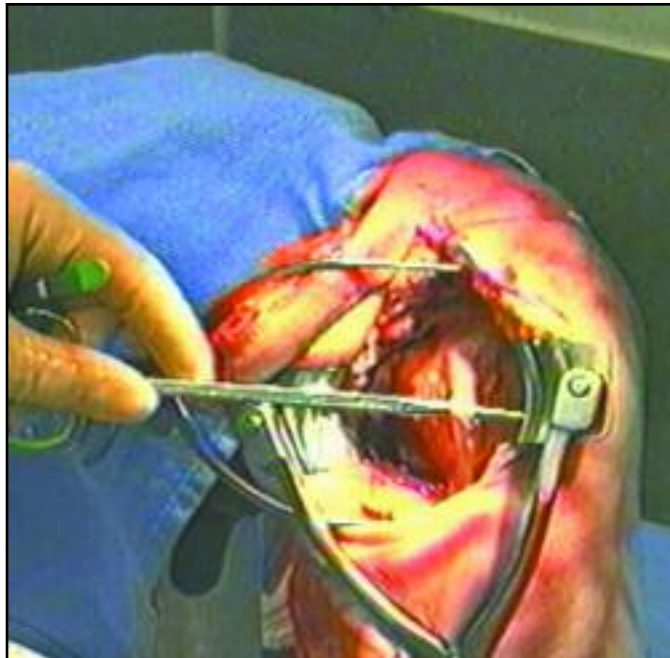


Image 5

Sutures are passed into the soft tissue and bone (*image 6*) at the attachment of the subscapularis and infraspinatus to the lesser and greater tuberosities, respectively. Heavy non-absorbable #2 or #5 cottony dacron should be used. Occasionally, the humeral head may have remnants attached either to the greater, or more commonly, the lesser tuberosity. These remnants must be carefully osteotomized at the anatomic neck to free the tuberosity. Save the humeral head for later use both as a sizing template and a source of cancellous bone graft (*image 7*).

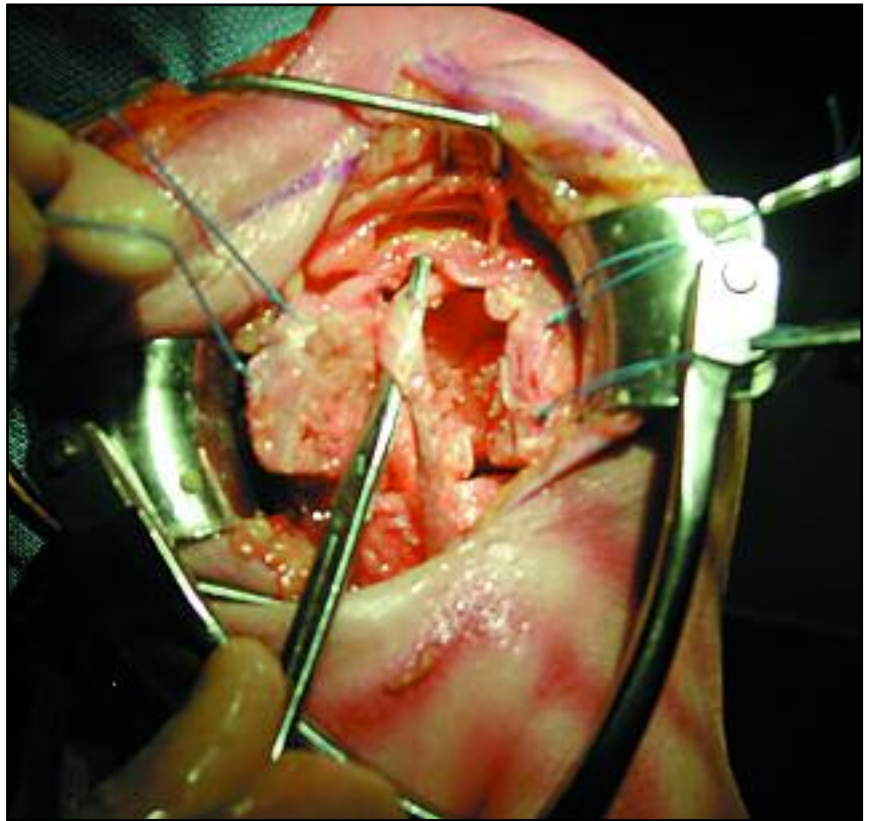


Image 6

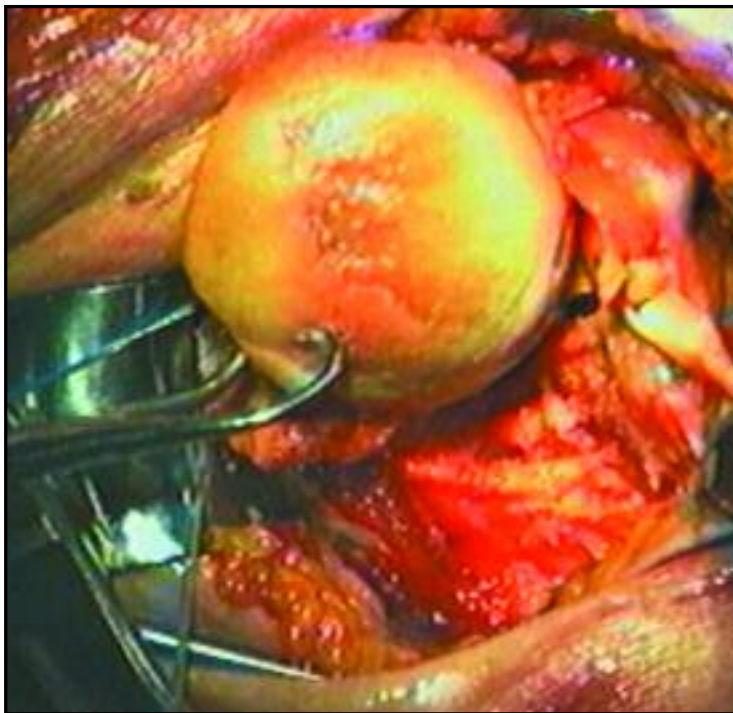


Image 7

Release any capsular attachments at the bases of the tuberosities that remain to free them from the shaft. No dissection of the bony fragments of the tuberosities is needed nor desired, and care should be taken to maintain their soft-tissue attachments. The biceps tendon should be temporarily rerouted, lateral to the greater tuberosity, to gain a clear view of the glenoid. The glenoid cavity should be cleaned well of bony fragments and hematoma, and thoroughly irrigated.

Preparation of the Humeral Shaft:

The humeral shaft is now delivered into the wound, as the arm is extended and adducted. Medial soft tissue attachments at the proximal end may need to be released to allow the shaft to be delivered anteriorly. The proximal 1/3 of the pectoralis major insertion may be released.

Two retractors are placed behind the shaft and the intramedullary canal is debrided of hematoma and any bony debris. It is not desirable to actually ream out the contents of the intramedullary canal and no attempt should be made to ream to cortical bone, which is frequently thin. Often, the fatty marrow and lack of cancellous bone in the humeri of the elderly allow "sizing" the humeral canal by simply placing the reamer or a prosthetic trial stem down the canal and making an assessment from this (*image 8*). One should allow for an approximately 1 mm circumferential cement mantle when sizing the prosthetic stem.

If there is metaphyseal comminution, such as butterfly fragments, they should be cerclaged together before proceeding.

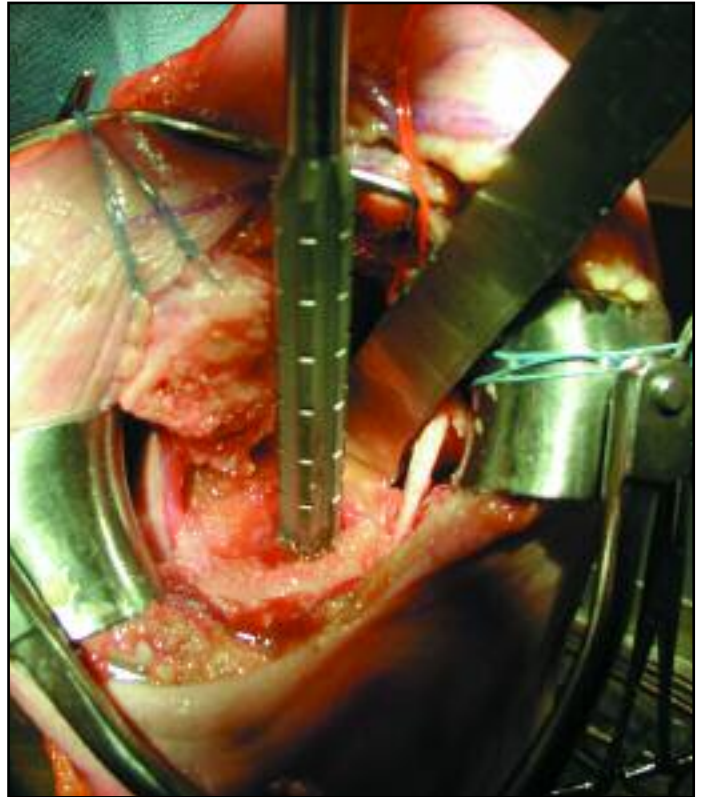


Image 8

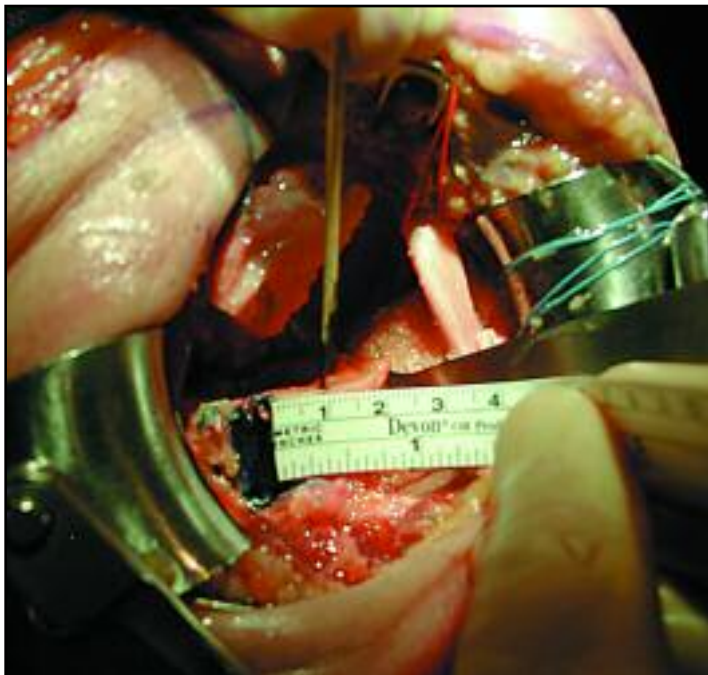

Image 9

Trialing the Humeral Components and Soft-tissue Balancing:

Proper soft tissue tension to provide for stability, mobility and optimal bio-mechanical advantage, requires proper height and version adjustments of the stem, and proper head diameter and thickness. The Solar® Fracture system provides excellent flexibility in choosing the appropriate combination of implant components and heads due to the wide array of sizes.

The humeral stem trial is inserted down the intramedullary canal. Since the natural position of the humeral head is in retroversion to the humeral shaft, some reference point to re-establish this relationship must be defined. To position the prosthetic stem in the appropriate retroversion, place the lateral fin of the humeral component approximately 1 cm posterior to the bicipital groove, at the proximal end of the canal (*image 9*).

Furthermore, with the arm placed so that the hand and forearm align perpendicular to the plane of the operating table, the trunnion should point toward the glenoid (*image 10*).

The humeral implant should sit slightly "proud" to the medial edge of the fracture (the calcar), to position the base of the collar at the level of the anatomic neck of the native shoulder when trialing. (This position is noted and will need to be reproduced upon implantation).

The tuberosities must be brought around the stem, under the prosthetic collar, without undo tension, and must permit adequate ROM in all planes.

If necessary, choose a slightly smaller or thinner head. To achieve these requirements, debulk the tuberosity bone, and if necessary, release the capsule as described earlier.

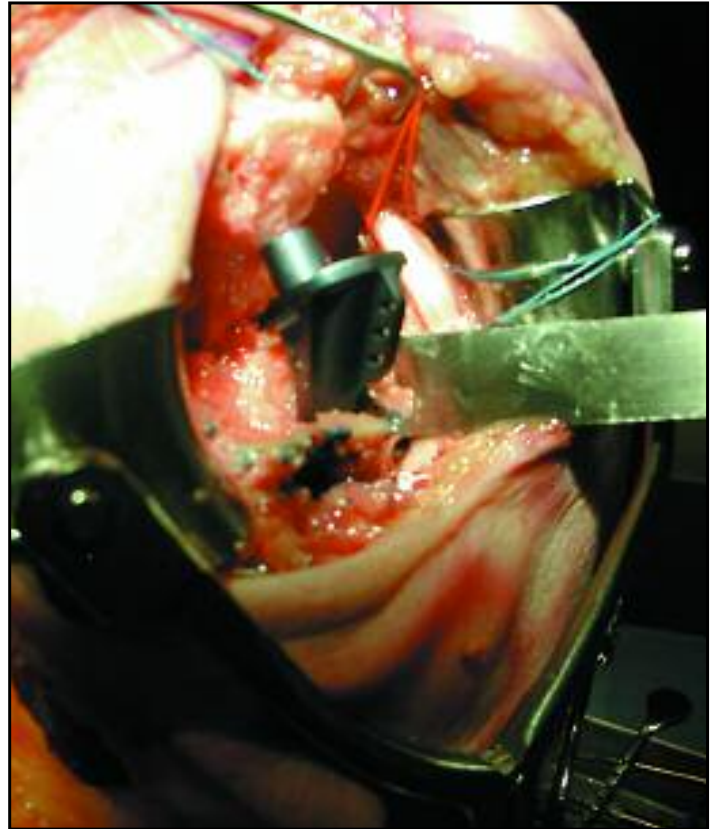


Image 10

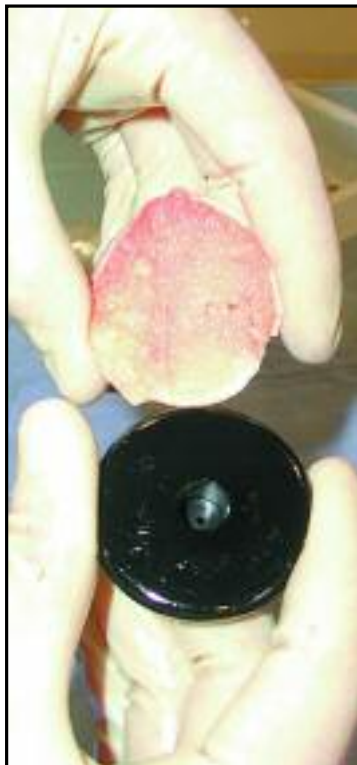

Image 11A



Image 11B

The trial humeral head is chosen to be approximately the same diameter and thickness as (or slightly smaller than) the patient's native humeral head (*image 11A & 11B*).

A cortico-cancellous wedge-shaped piece of bone can now be shaped from the humeral head. This piece of bone should be placed under the medial collar of the prosthesis to fill and support the gap medially, between the collar and the end of the "calcar" area of the shaft fracture. This will give additional support post-implantation, as well as aid to reduce "settling" of the implant while the cement is hardening (*image 12*).

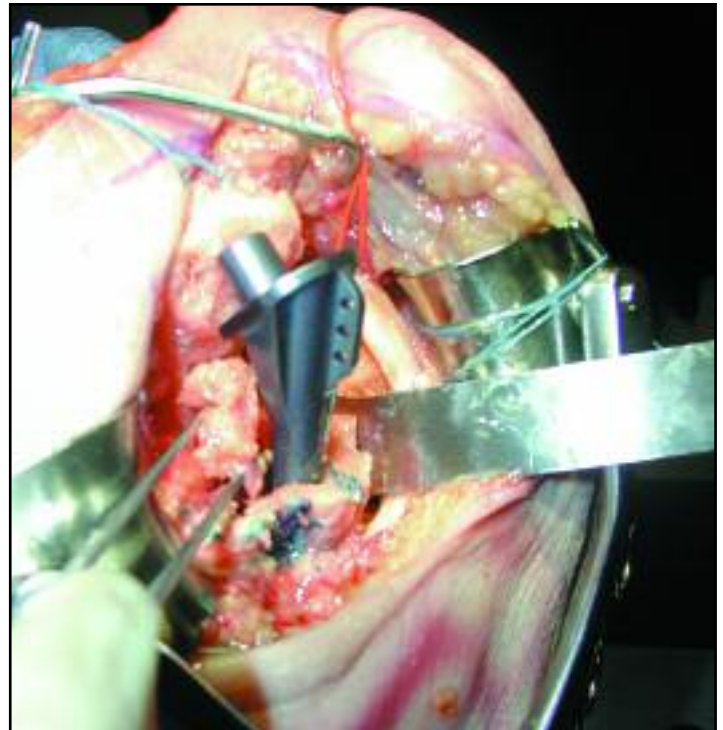


Image 12

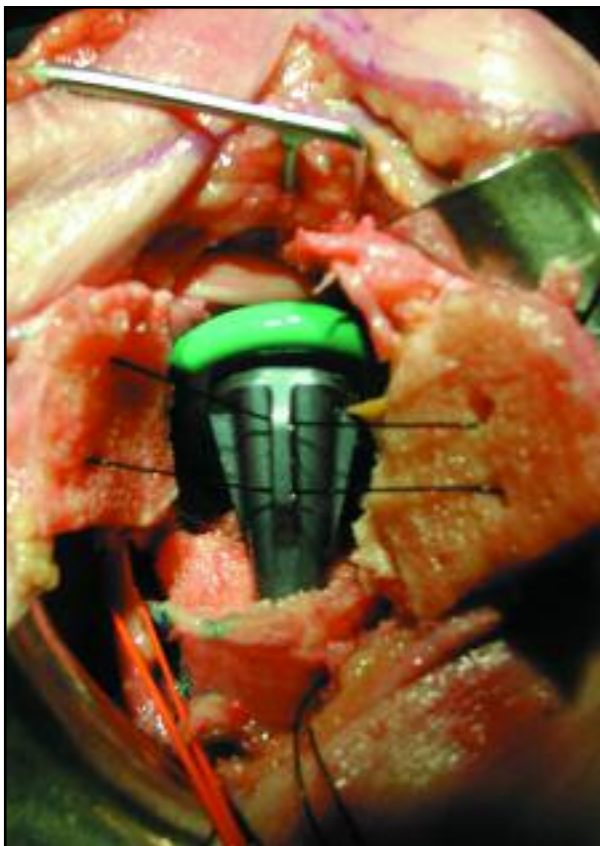

Image 13

Both tuberosities can now be brought around the humeral head, on either side of the humeral component to ensure that closure of the tuberosities and adequate ROM can be attained (*image 13*). Internal and external rotation can now be checked, as well as stability, while maintaining the tuberosities in position and ranging the shoulder. Elevation of 150° is desirable. At least 45° of external rotation, and internal rotation to the posterior axillary line should be achieved.

The hand should be placed across the chest and touch the opposite shoulder and axilla. If there is limitation of motion in rotation, check to be sure that sufficient tuberosity and any remnant of the humeral head have been trimmed (best accomplished from the intra-articular side of the joint), and that the head size is not too thick. Make adjustments as necessary. The trial component may now be removed.

Drill holes must be made in the humeral shaft cortex for insertion of anchoring sutures that will eventually pull the tuberosities down to the shaft. Four drill holes, just large enough to pass the needle of a double-armed #5 cottony Dacron suture through them, are made in the shaft at about 1 cm below the fracture line, and centered about the bicipital groove on the shaft (image 14). The free ends of the suture are brought out external to the shaft. The drill holes may be placed 2 cm distal to the fracture line if bone is very soft. The humeral canal is then irrigated and dried, and debris removed.

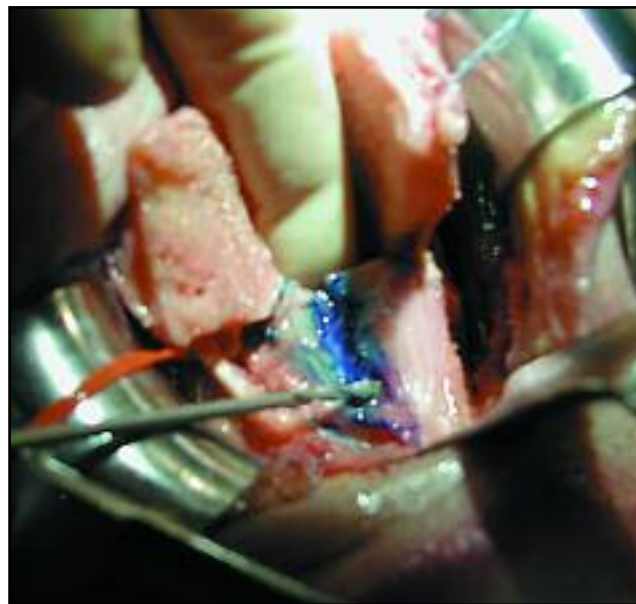


Image 14

Cementing: Simplex® P Bone Cement (Methyl methacrylate cement), of slightly doughy consistency, is now injected into the canal. It is not necessary to insert a bone plug or cement restrictor into the canal since the cement should not be injected very far distally or in a very liquid form. The cement's primary purpose is to provide proximal rotational control of the Solar humeral component

Excessive cement should be removed from around the stem, especially in the two lateral quadrants. Bare metallic implant should show so that there is plenty of room to reattach the tuberosities. Medially, the previously designed cortico-cancellous wedge should be impacted into position as an additional calcar support. While the cement is hardening, cancellous bone from the humeral head should be harvested and saved for placement under the tuberosities prior to their full reattachment.

Tuberosity re-attachment: Once the cement fully cures, irrigate the joint and wound to remove any debris. The sutures in the tuberosities can now be brought through the holes in the lateral fin in order to close the interval between the greater and lesser tuberosities aligned with bicipital groove (image 15). Aligning the closure with the bicipital groove may require readjusting the suture placement so that more of the greater tuberosity and less of the lesser tuberosity is grasped with the sutures.

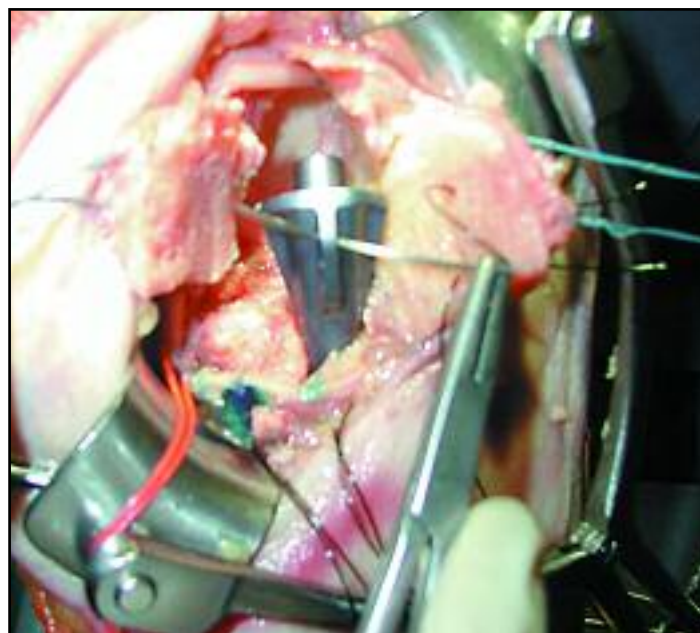


Image 15

Placing the lesser tuberosity too far laterally will result in loss of external rotation. The sutures should be brought through the opposite tuberosity after passing through the fin holes, so that transversely tying the sutures now brings the tuberosities together. Do not tie these sutures yet. Using the previously placed sutures in the shaft with their needles attached, place them into the soft tissues (the rotator cuff tissue) just superior and lateral to the tuberosities, in a figure-of-eight fashion, incorporating both tuberosities in each set of sutures (image 16). Do not place these sutures through the holes in the prosthetic stem.

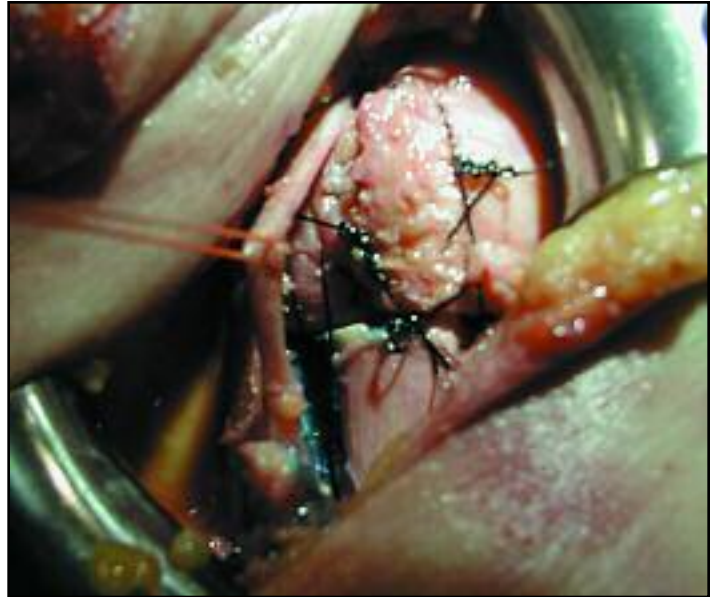


Image 16

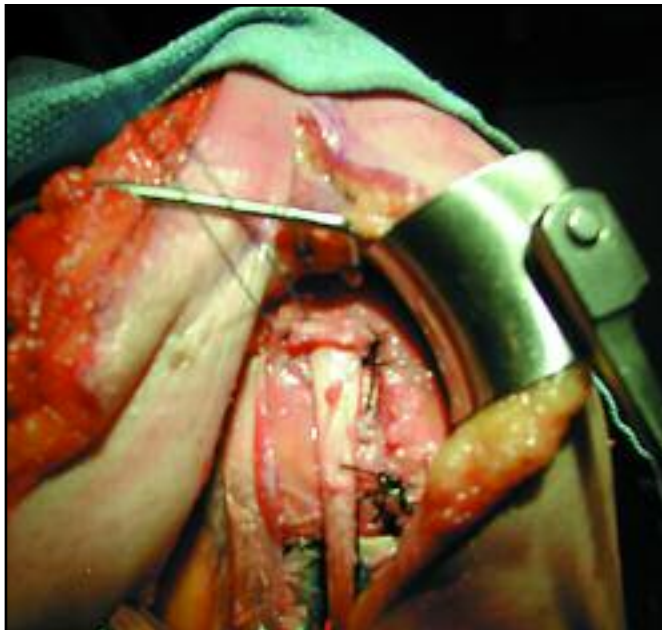

Image 17

Tie the first set of transversely placed inter-tubercular sutures first. Then, prior to pulling the tuberosities distally with the other set of figure-of-eight-sutures, place as much of the cancellous pieces of bone graft under the lateral portion of the Solar humeral component collar (anteriorly and posteriorly) as possible. Bone graft should also be placed down to the upper part of the shaft to enhance bony union of the tuberosities. Finally, the sutures can be pulled taught and tied down. The tuberosities should now be horizontally approximated, as well as closely applied to the shaft, adjacent to the implant and slightly overlapping the bony humeral shaft. Allow the biceps tendon to fall back in to place. The rotator interval may be re-approximated at this point with non-absorbable suture (image 17).

The resulting construct can now be tested for range-of-motion and stability. The entire construct should move as a unit, permitting 150° of elevation, 45° - 60° of external rotation, and internal rotation to the posterior axillary line and the opposite axilla. Routine closure of the delto-pectoral interval, subcutaneous tissue and skin is then performed. Light dressings and a sling are then applied.

Post-Operative Rehabilitation (as suggested by Steven R. Groman,

Immediately Postop:

Sufficient analgesics are required to allow the patient to begin ROM exercises immediately post-operatively. Motions are passive, and can generally be done by the patient with monitoring. Self-assisted passive range of motion (PROM) using the opposite arm as the motor with relaxation of the operative arm, can be taught, and should be done in a supine position. Additional devices such as pulleys, sticks, etc., may be of benefit, but caution should be maintained to not force the shoulder too aggressively. Substituting motions, such as shoulder shrugging, should be discouraged as well. Most patients can achieve at least $2/3$ of the motion achieved on the operating room table within 2 days. Encouragement and monitoring is imperative, however, to achieve maximal results.

First 6 Weeks:

The same self-assisted PROM techniques are practiced several times per day by the patient. Active use of the hand and forearm may be permitted, and elbow ROM should not be neglected. By the end of 6 weeks, generally there is sufficient healing of the tuberosities so that active motions can be initiated. X-rays of the shoulder in AP-Internal and external rotation and an axillary view can aid in this determination.

After 6 Weeks:

Generally, all external support can be discarded and gentle active motions are allowed. Rotator rehabilitation is begun and patients are not permitted to lift until good strength and good active ROM is achieved. It can take many months, often up to a year, to achieve maximum results.

(Steven R. Groman, MD)

