

**EVOLVE®**

Modular Radial Head

SURGICAL TECHNIQUE



**WRIGHT.**



**EVOLVE®**  
modular **RADIAL HEAD**

surgical technique 1-5

*in situ* assembly 6-7

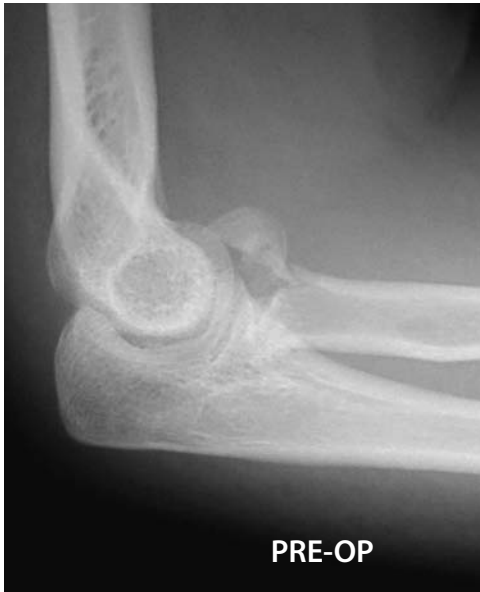alternate O.R. back table assembly 8

Proper surgical procedures and techniques are the responsibility of the medical professional. The following guidelines are furnished for information purposes only as techniques used by Graham King, M.D. and Stuart Patterson, M.D. Each surgeon must evaluate the appropriateness of the procedures based on his or her personal medical training and experience. Prior to use of the system, the surgeon should refer to the product package insert for complete warnings, precautions, indications, contraindications and adverse effects. Package inserts are also available by contacting Wright Medical Technology, Inc.

## EVOLVE® modular RADIAL HEAD

## SURGICAL TECHNIQUE

### introduction



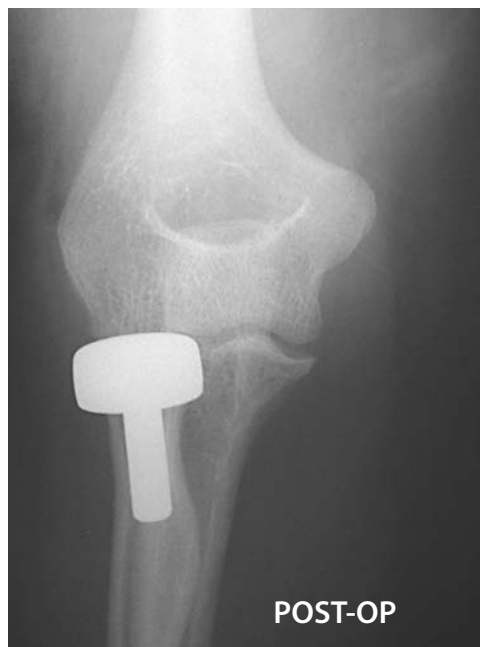Undisplaced radial head fractures should be managed non-operatively while displaced radial head fractures should be treated with open reduction and internal fixation if technically feasible. Comminuted displaced radial head fractures, which cannot be reconstructed with stable internal fixation, should be managed with radial head excision or prosthetic replacement.

In the setting of an associated elbow dislocation, radial head excision without replacement is contraindicated due to valgus instability arising from concomitant injury to the medial collateral ligament of the elbow. The diagnosis of disruption of the medial collateral ligament and/or interosseous membrane is more problematic in patients without an associated elbow or distal radioulnar joint dislocation. In one study, all patients with comminuted radial head fractures without an associated elbow dislocation had insufficiency of the medial collateral ligament or interosseous membrane as documented by stress radiographs<sup>1</sup>. Given this high frequency of unrecognized soft tissue injury with comminuted radial head fractures, it is not surprising that some authors recommend that primary prosthetic substitution should be performed in all patients where radial head resection is required.

Dr. Graham King and colleagues at St. Joseph's Health Centre in London, Ontario, Canada, performed a cadaveric study evaluating the ability of radial head implants to stabilize the medial collateral ligament deficient elbow. Their findings showed that metallic implants improved elbow stability as measured by a significant decrease in varus-valgus laxity." Additionally, they found that elbow stability following radial head resection and metallic implant arthroplasty was similar to the stability of an intact radial head in the medial collateral ligament deficient elbow<sup>2</sup>.

As in radial head resection alone for a comminuted fracture, radial head resection and replacement arthroplasty should be done soon after the fracture occurs, preferably within a few days.

The EVOLVE® modular radial head system employs the advantages of years of laboratory and clinical research to create the next generation of modular radial head arthroplasty. By creating a two part, modular design, the implant system offers the surgeon the ability to appropriately match the patient's anatomy. In addition, the capability of *in situ* assembly, allows for easier implant insertion and less surgical trauma to the joint.



**STEP 1**

Radiographs of the contralateral elbow and both wrists are helpful in preoperative planning. Templates can be used to estimate the radial head and stem sizes to be used. With the patient in either the supine or lateral decubitus position, a posterior midline longitudinal skin incision is used just lateral to the tip of the olecranon. A full thickness lateral flap (fasciocutaneous) is elevated on the deep fascia to protect the cutaneous nerves. The posterior midline incision permits access to the medial side of the elbow should repair of the medial collateral ligament be necessary to restore elbow stability. In patients with isolated injuries to the radial head, a traditional lateral skin incision may be employed, however, care should be taken with cutaneous nerves which usually cross the incision.

The radiocapitellar joint is exposed through the interval between the anconeus and extensor carpi ulnaris muscles (Kocher approach) | FIGURE 1.

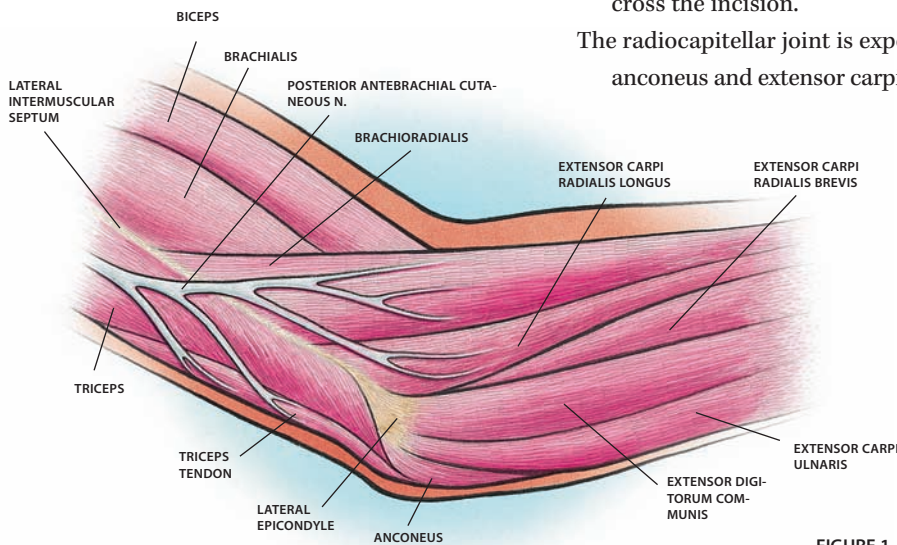
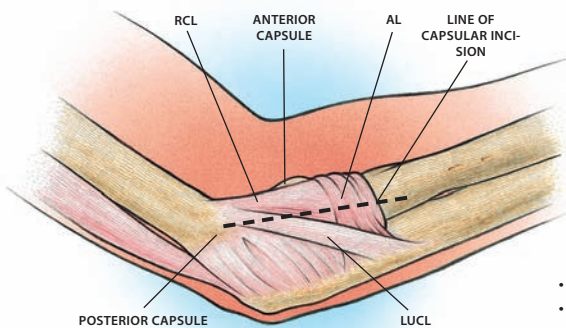


FIGURE 1

The extensor carpi ulnaris is elevated slightly anteriorly and superficially to the lateral ulnar collateral ligament complex, an important varus and rotational stabilizer of the elbow. The radial collateral (RCL) and annular ligaments (AL) are divided longitudinally at the level of the mid-aspect of the radial head. The motor branch of the radial nerve (posterior interosseous nerve), that passes around the radial neck, is protected by keeping the forearm pronated during the exposure, and by avoiding dissection into the supinator muscle | FIGURE 2).

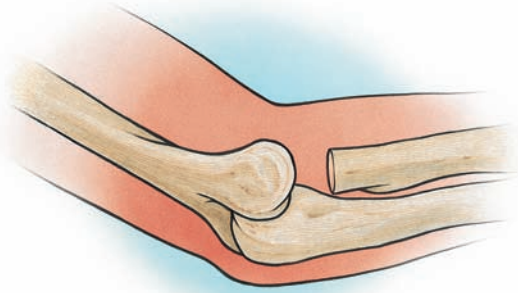

- RCL - RADIAL COLLATERAL LIGAMENT
- AL - ANNULAR LIGAMENT
- LUCL - LATERAL ULNAR COLLATERAL LIGAMENT

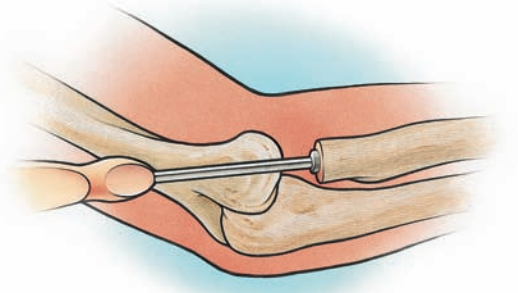
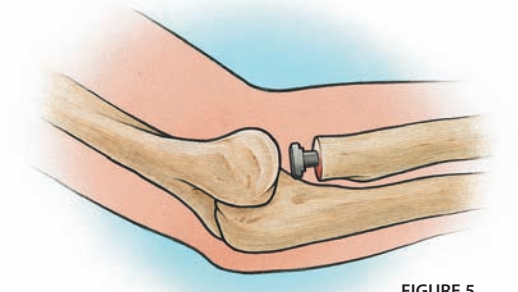
FIGURE 2

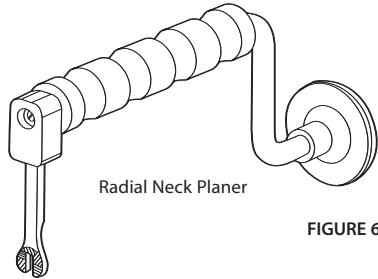
**STEP 2**

Using a microsagittal saw, the remaining radial head is resected at the level of the radial neck fracture, perpendicular to the neck | **FIGURE 3**. Care should be taken to avoid excessive resection of the radial neck, as this may preclude implant placement. Preoperative templating is helpful in determining the appropriate level of resection. The radial shaft is retracted posterolaterally to improve exposure.

**FIGURE 3****STEP 3**

Using the smallest stem broach, an opening is created in the medullary canal | **FIGURE 4**. Sequentially larger stem broaches are used to gently ream the radial neck. The largest broach that easily fits is used to select the diameter of the trial stem. The trial stem should fit into the radial neck without force and have a loose but not sloppy fit in the medullary canal of the radius | **FIGURE 5**.

**FIGURE 4****FIGURE 5**



Radial Neck Planer

FIGURE 6

**STEP 4**

The radial neck planer | FIGURE 6 is slipped over the trial stem and rotated back and forth to create a smooth contact surface on the radial neck, perpendicular to the longitudinal axis of the radial neck. Axial force is applied to the handle at the top of the planer while planing | FIGURE 7.

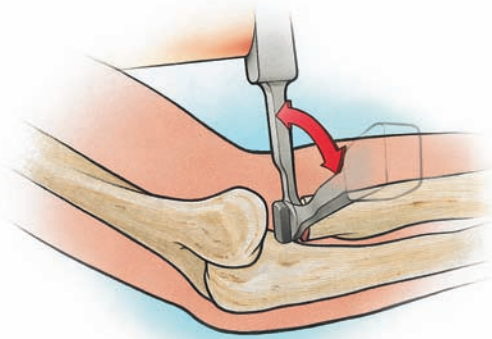


FIGURE 7

**STEP 5**

The appropriate diameter trial head is chosen based on pre-operative templating and backtable reassembly of the comminuted radial head fracture. The base of the table assembly fixture can be used as a sizing template for the reassembled fracture pieces. When in doubt between two head sizes, the larger diameter implant is selected. Head thickness is chosen based on the height of the resected radial head. The trial head is screwed onto the trial head sizer insertion tool. The trial stem sizer insertion tool is placed into the keyway of the trial stem sizer to hold the stem in place as the trial head is slipped onto the trial stem platform | FIGURE 8A.

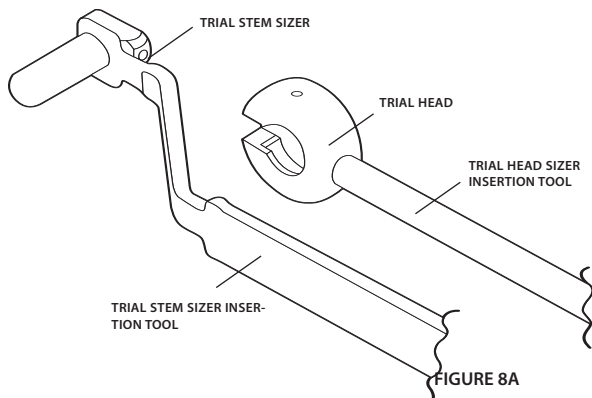


FIGURE 8A

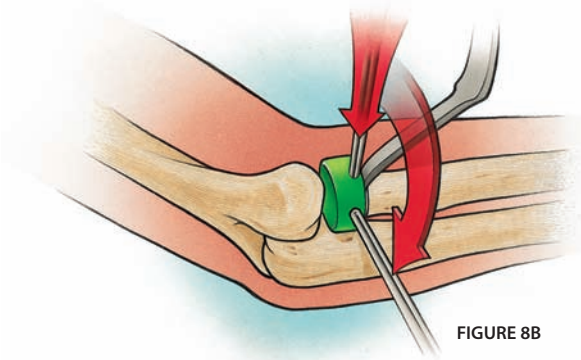


FIGURE 8B

Once the trial head has slipped over the stem platform, the trial head sizer insertion tool is rotated with respect to the trial sizer stem insertion tool (FIGURE 8B). When the trial head has been rotated 90°, the trial head and stem will lock together via a ball plunger connection | FIGURE 8C.

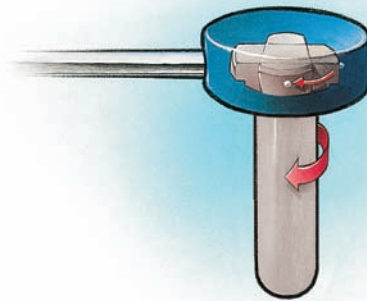


FIGURE 8C

Unscrew the trial head sizer insertion tool from the trial head and remove the trial stem sizer insertion tool | FIGURE 9. Reduce the elbow with the trial implants in place. Good contact between the trial radial head and the capitellum in addition to smooth motion on passive flexion and extension of the elbow and rotation of the forearm should be noted. Some translation of the trial radial head relative to the capitellum is normal with forearm rotation. The appropriate thickness of the radial head implant is assessed with the forearm held in pronation and with a valgus load applied to compensate for the lateral destabilization induced by the surgical approach. The trial head should articulate with the most proximal margin of the proximal radioulnar joint at approximately the same level as the coronoid process. An image intensifier should be used to evaluate ulnar variance at the wrist. An implant that is too thick will have ulnar negative variance and an implant that is too thin will have ulnar positive variance relative to the contralateral wrist. The ulnohumeral joint should also be visualized with the image intensifier to ensure that the joint space is symmetrical. A prosthesis that is too large will result in varus alignment with opening of the medial ulnohumeral joint space relative to the lateral ulnohumeral joint space.

#### STEP 6

If the trial reduction is not acceptable, applicable procedural steps 2-5 are repeated and trials chosen as appropriate.

#### STEP 7

Once optimal sizing has been determined, the trial head is reattached to the trial head sizer insertion tool and the trial stem sizer insertion tool is placed back into the keyway of the trial stem. The trial head is unlocked from the trial stem by rotating 90 degrees again, and the trial head removed from the joint space. The trial stem is then removed from the joint space and the joint is thoroughly irrigated.

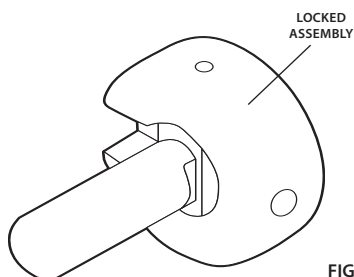


FIGURE 9

## EVOLVE® modular RADIAL HEAD *IN SITU* ASSEMBLY

---

### STEP 8

The appropriate size of stem implant is selected and placed into the radial canal | FIGURE 10.

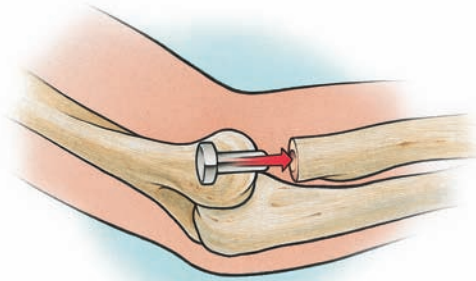


FIGURE 10

### STEP 9

The appropriate size of head implant is selected and prepared for implantation. Using finger control, the head implant is placed into the joint space with the female taper over the stem implant male taper | FIGURE 11. At this point the implants are in position to be locked. Ensure the locking instrument is assembled for the right or left elbow as necessary. The appropriate plastic head insert is placed onto the head side of the assembly tool jaws | FIGURE 13.

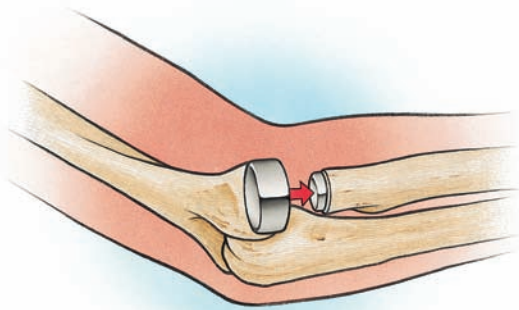


FIGURE 11



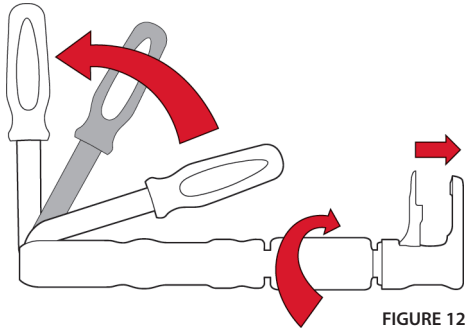


FIGURE 12

**STEP 10**

The lever arm of the assembly tool is opened away from the instrument body | FIGURE 12. Using the screw mechanism on the assembly tool shaft, the jaws of the assembly tool are adjusted to the approximate head height. The assembly tool jaws are placed into the joint space | FIGURE 13 so that the implant head is fully seated on the plastic head insert and the stem platform is resting on the stem portion of the jaws. Final hand tightening of the assembly tool jaws is performed to eliminate any space between the jaws and the implant components. The lever arm is brought toward the instrument body until the handle is fully closed | FIGURE 14. To ensure the 2000N-assembly load has been reached, leave the assembly tool in the joint space and repeat Step 10.

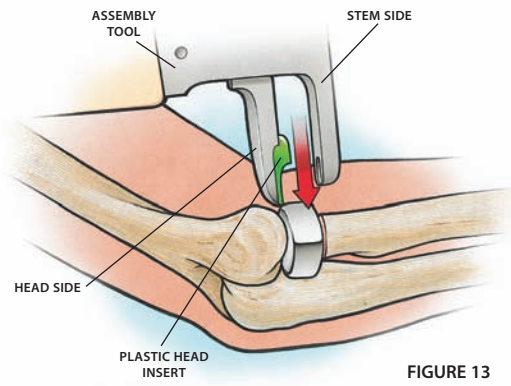


FIGURE 13

**STEP 11**

The assembly tool is removed from the joint space. The annular and radial collateral ligaments are repaired using absorbable No. 1 sutures. The fascial interval between the anconeus and extensor carpi ulnaris muscles is closed with interrupted No. 1 absorbable sutures. The skin and subcutaneous tissues are repaired in layers.

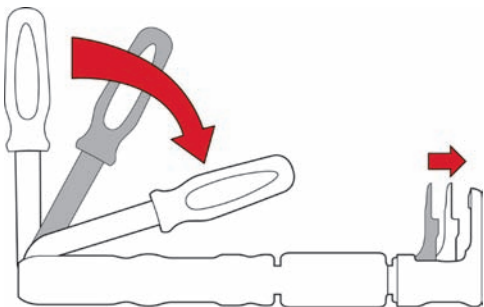


FIGURE 14

**EVOLVE®**  
 modular RADIAL HEAD     **ALTERNATE O.R. BACK TABLE ASSEMBLY**

---

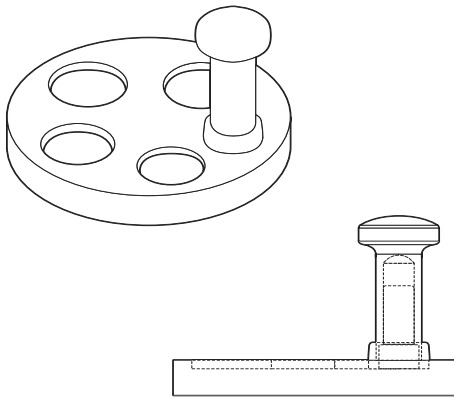


FIGURE 12

**STEP 8A**

Implant assembly on the operating room back table provides the surgeon with the flexibility to assemble anatomically mated components prior to implant placement if desired. This method is useful in patients with associated soft tissue injuries to the elbow where monoblock insertion of the implant can be easily performed, such as an acute fracture-dislocation. Disruption of the lateral collateral ligament complex, such as commonly occurs in an elbow dislocation, allows rotation of the radial neck posterior to the capitellum, facilitating implant insertion. The radial head implant is placed in the appropriate size slot of the table assembly fixture | FIGURE 15.

**STEP 9A**

The Morse-taper of the implant stem is inserted into the implant head taper and the stem impactor cap is placed over the stem. Stem impactor adapters are placed between the stem implant and the stem impactor cap for the 5.5, 6.5, and 7.5mm implant stem sizes. The implant taper is seated by firm impaction with a mallet.

**REFERENCES**

1. Davidson PA, Moseley JB, Tullos HS. Radial head fracture: A potentially complex injury. *Clinical Orthopaedics and Related Research*. 297:224-230, 1993.
2. King GJ, Zarzour ZD, Rath DA, Dunning CE, Patterson SD, Johnson JA. Metallic radial head arthroplasty improves valgus stability of the elbow. *Clinical Orthopaedics and Related Research* 368:114-25, 1999.





**Wright Medical Technology, Inc.**

5677 Airline Road  
Arlington, TN 38002  
901.867.9971 phone  
800.238.7188 toll-free  
[www.wmt.com](http://www.wmt.com)

**Wright Medical Europe SA**

Commerce Parc  
Gebouw B, 6th Floor Krijgsman II  
1186 DM Amsterdam  
The Netherlands  
Tel +31(0) 205450100

\*Registered marks of Wright Medical Technology, Inc.  
©2006 Wright Medical Technology, Inc. All Rights Reserved.

SO 992-1299  
Rev.2.06