
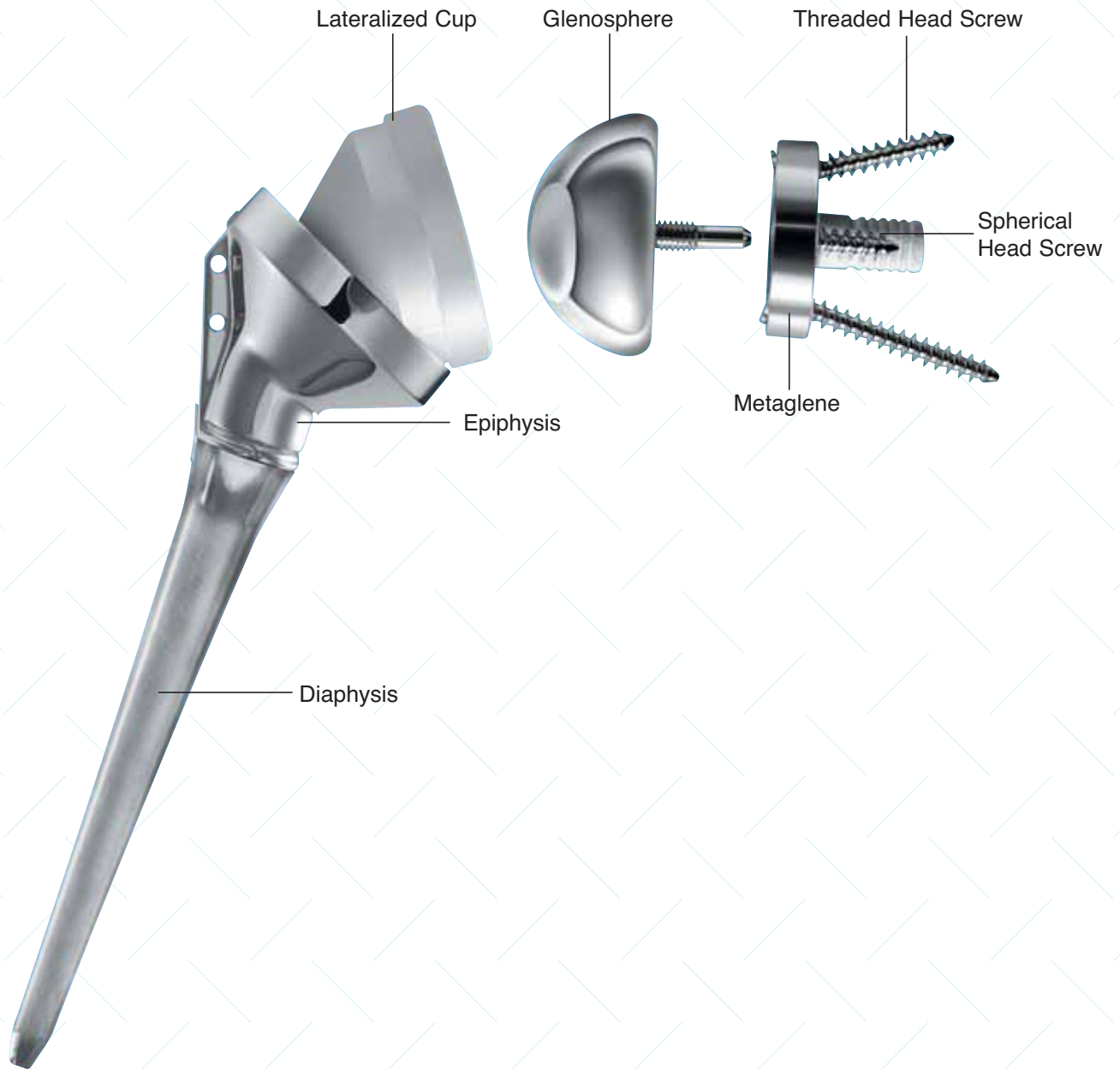


**DELTA**  
CTA  
REVERSE SHOULDER SYSTEM



SURGICAL TECHNIQUE  
**REHABILITATING FUNCTION**

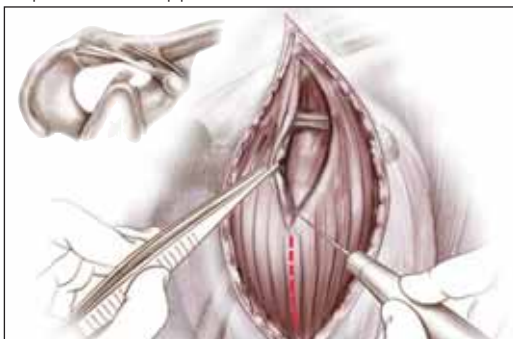

# Contents

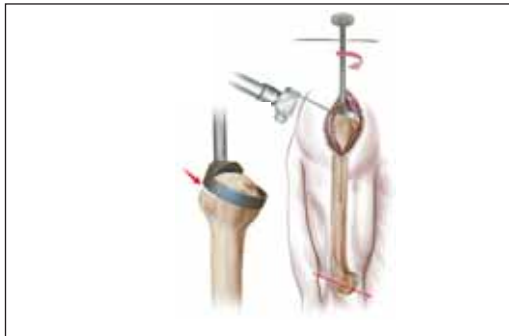
Surgical Steps – At a Glance .....	2
Introduction .....	3
Preoperative Planning .....	4
Surgical Approach and Patient Positioning .....	4
Superior Lateral Approach .....	5
Humeral Head Resection .....	6
Humeral Reaming .....	7
Distal Humeral Reaming (Revision Surgery) .....	8
Proximal Reamer Guide Assembly .....	8
Proximal Humeral Reaming .....	9
Trial Humeral Implantation .....	10
Glenoid Exposure .....	10
Glenoid Preparation .....	11
Metaglène Insertion .....	15
Trial Reduction .....	18
Glenosphere Placement .....	19
Humeral Implant Insertion .....	20
Closure .....	22
Postoperative Management .....	22
Ordering Information .....	23

# Surgical Steps - At a Glance

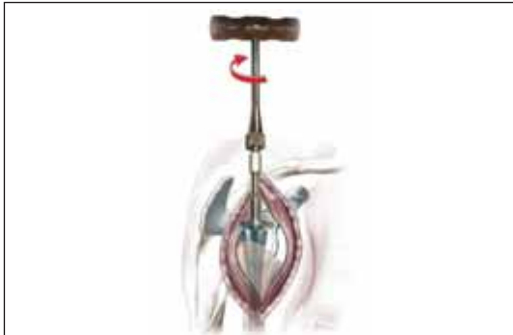Superior lateral approach



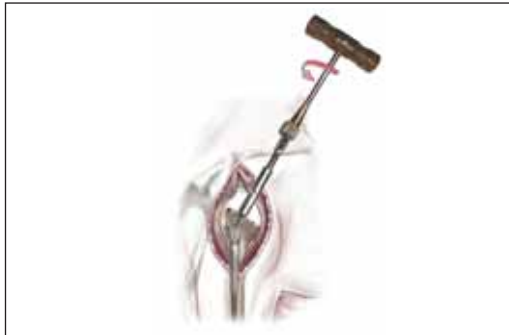Resection of the humeral head



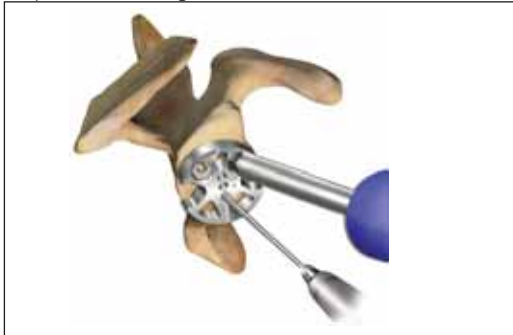
Diaphyseal preparation



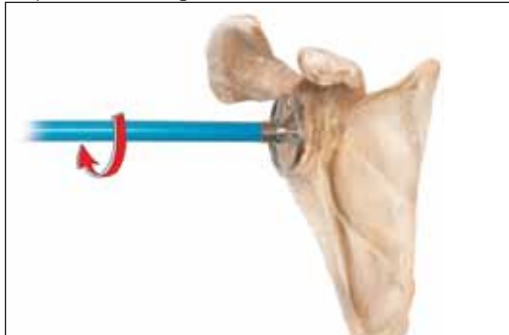
Proximal reaming of the humerus



Preparation of the glenoid



Preparation of the glenoid



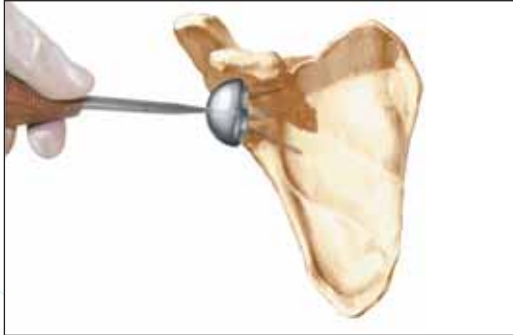
Preparation of the glenoid



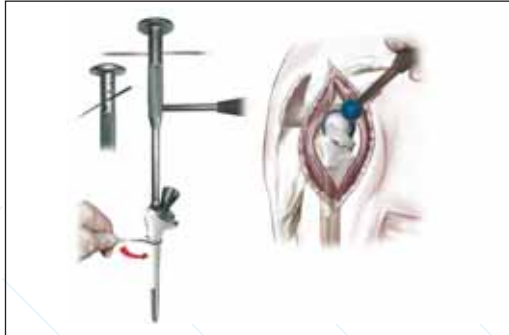
Insertion of the metaglene



Glenosphere placement



Insertion of the humeral implant



## Introduction

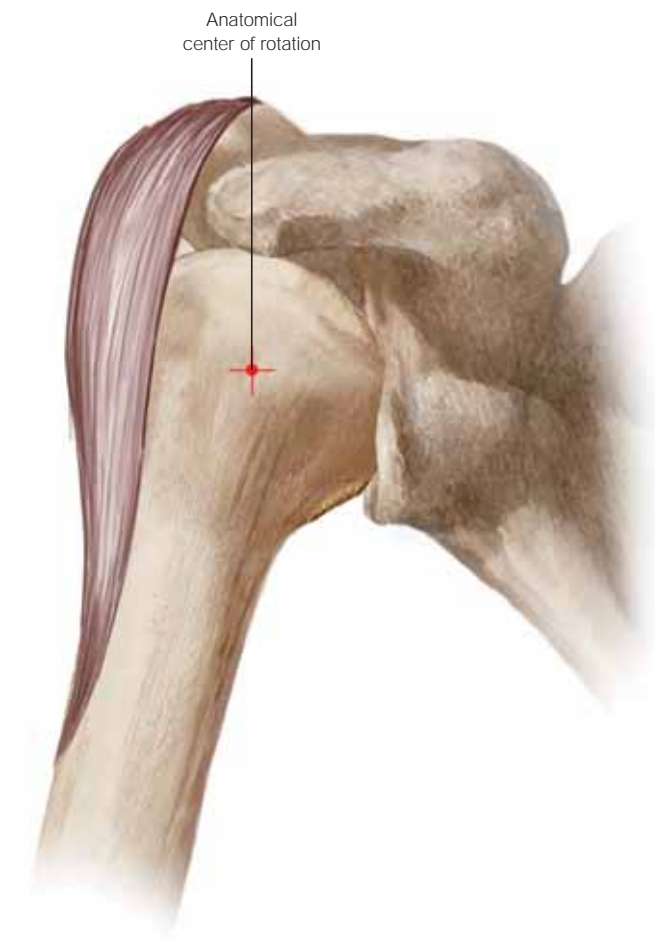


Figure 1

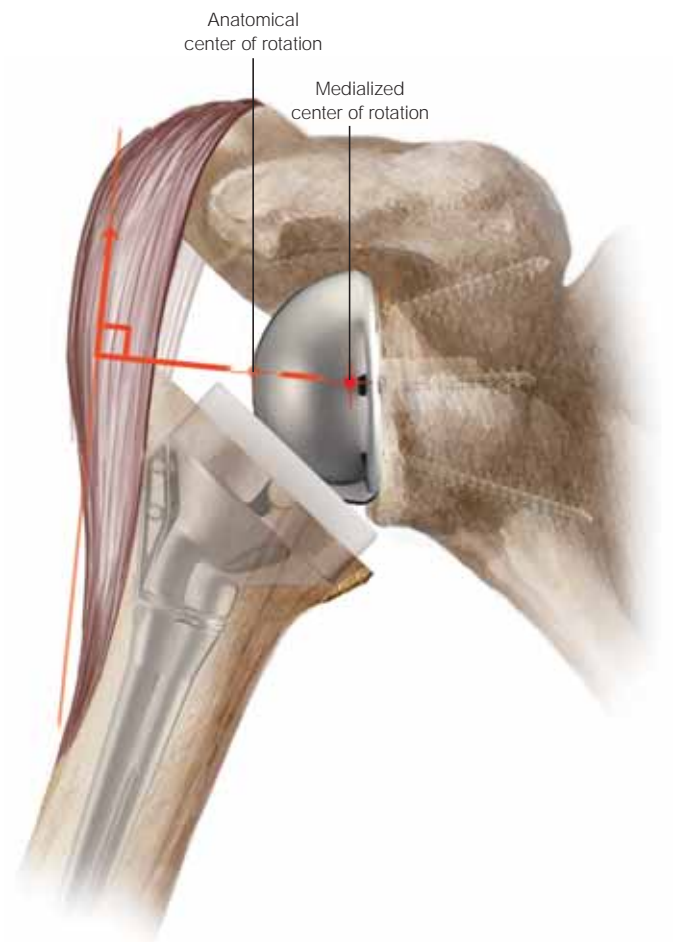


Figure 2

### Introduction

The Delta CTA® Reverse Shoulder System is indicated for the treatment of glenohumeral arthritis when it is associated with irreparable rotator cuff damage and where conventional total shoulder arthroplasty may not be fully effective in restoring joint stability with an adequate range of movement. The design avoids high shear forces associated with unstable conventional or hemiarthroplasty that can cause the implant to wear and loosen.

The Delta CTA prosthetic geometry reverses the normal relationship between scapular and humeral components, moving the center of rotation medially and distally to increase the lever arm length of the deltoid muscle (*Figures 1 and 2*).

This allows the three muscles in the deltoid group to compensate for rotator cuff deficiency, drawing the articulating surfaces together to stabilize the joint to allow as near normal function as possible.

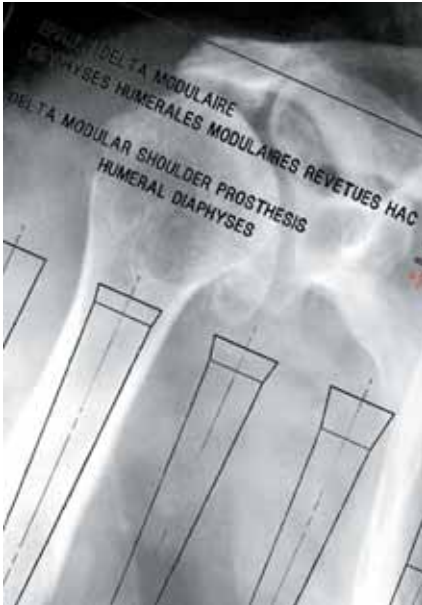

Figure 3  
Preoperative Planning

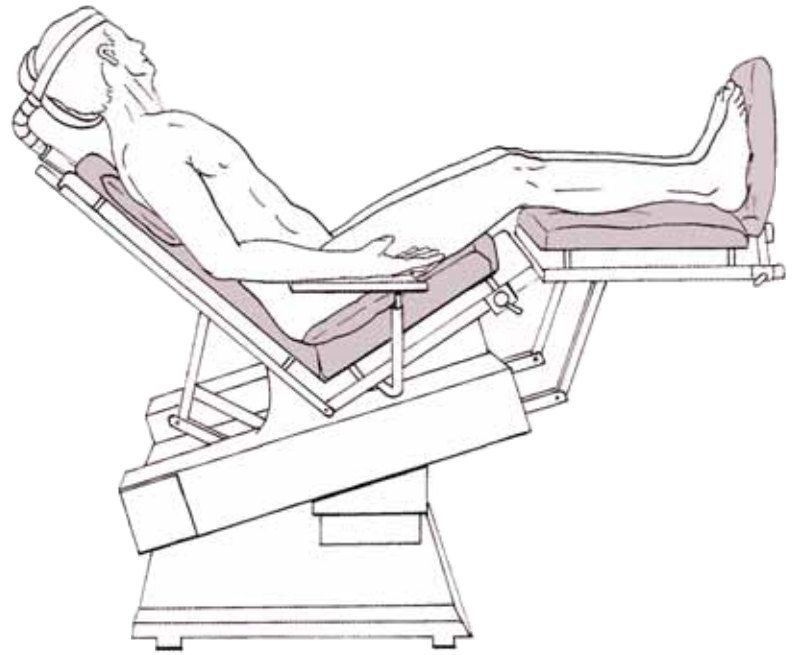


Figure 4  
Patient Positioning

### Preoperative Planning: Surgical Approach and Patient Positioning

Make an initial assessment of the bone in the superior and inferior aspects of the glenoid, using radiographic and CT imaging in order to determine the suitability of the patient for treatment. And, if appropriate, establish the location of the four metaglene screws for optimum implant stability. Carry out preoperative planning using AP and lateral shoulder radiographs of known magnification and the template to confirm the size and alignment of the implant (Figure 3).

The Delta CTA Reverse Shoulder System may be implanted using either a transacromial or transdeltoid approach. Preoperative planning should take into account the quality of the acromion.

If the acromion is small or has been weakened by previous acromioplasties, or in cases of severe osteoarthritis where there may be erosion on the inferior aspect, the transacromial approach will not be suitable.

A lateral deltoid splitting approach provides excellent visualization of the glenoid cavity during implantation.

Place the patient in the deck chair position, with the affected arm completely free and resting on a support (Figure 4).

## Superior Lateral Approach

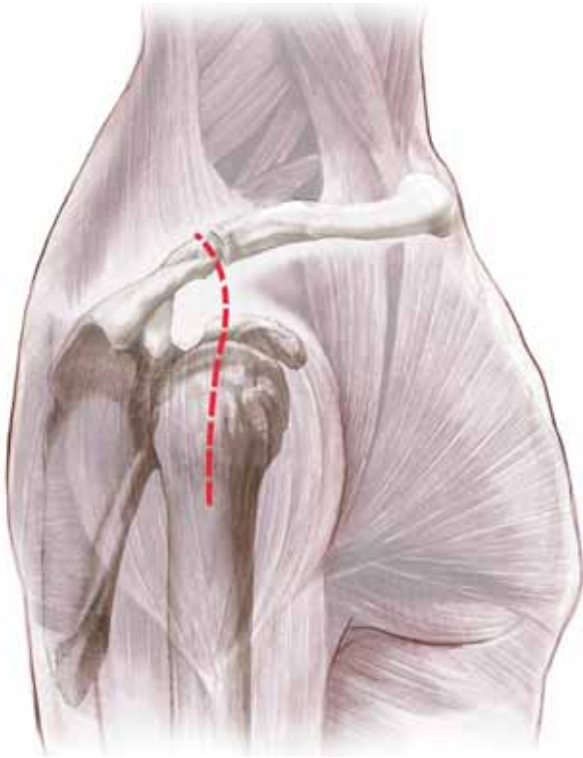


Figure 5  
Superior Lateral Approach

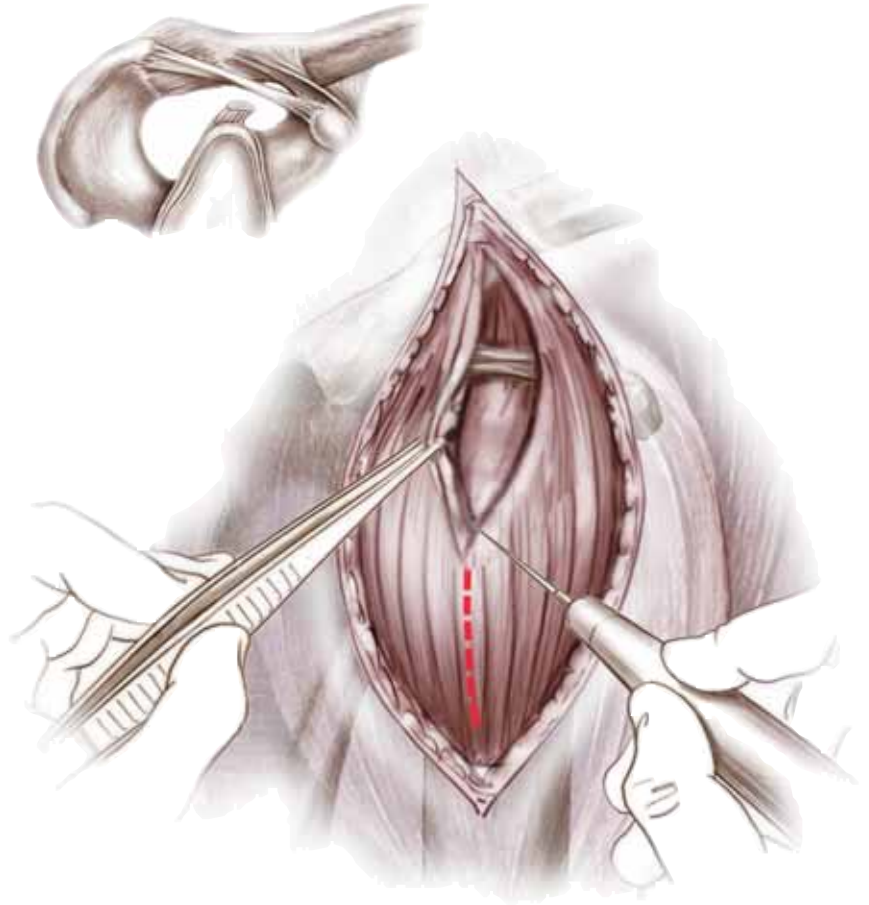


Figure 6  
Superior Lateral Incision

The surgical approach – superior lateral (*Figure 5*) or delto-pectoral – depends mainly on surgeon preference and clinical parameters. Revision surgery, for instance, usually dictates a delto-pectoral approach as it allows for a longer humeral incision when faced with a difficult removal of the humeral stem.

### Superior Lateral Approach

Start the incision at the level of the acromioclavicular (AC) joint. Follow the anterior aspect of the acromion and finish vertically downwards for 4 cm (*Figure 6*). Following subcutaneous dissection, separate the anterior and middle deltoid muscle bundles opposite the lateral margin of the acromion, using blunt dissection.

**The dissection should not extend beyond 4 cm from the external aspect of the acromion in order to preserve the axillary nerve.**

When the subacromial bursa is visible, gentle longitudinal traction in line with the limb will allow a retractor to be placed in the subacromial space.

Release the anterior deltoid subperiosteally from its acromial insertion up to the AC joint. The humeral head is then visible at the anterior edge of the acromion. Remove the subacromial bursa. If necessary, exposure may be improved by dividing the AC ligament and performing acromioplasty. Then, externally rotate the limb and dislocate the head anterosuperiorly to facilitate positioning of the resection guide. If the biceps is still present, tenodesis in the bicipital groove. Retain the teres minor and infraspinatus when present.

# Humeral Head Resection

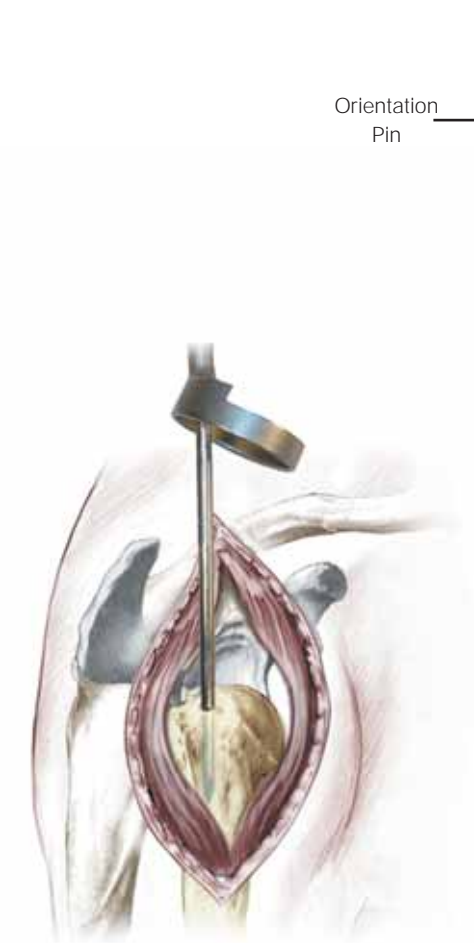


Figure 7  
Awl Insertion

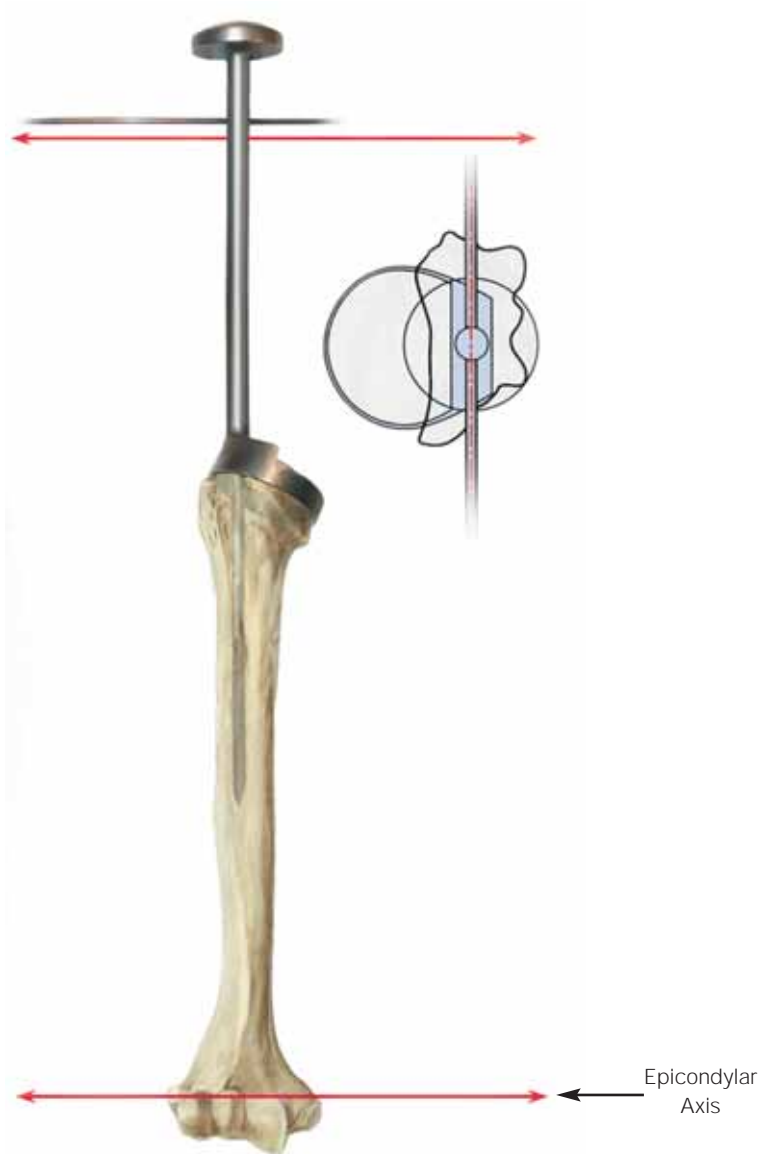


Figure 8  
Resection Guide Orientation

## Humeral Head Resection

Remove any osteophytes, then make an initial entry hole in the proximal humerus using an awl. Center the awl tip over and in line with the long axis of the humerus, at the junction of the intratubercular groove and the articulating surface of the humeral head (Figure 7).

Pass the orientation pin through the hole in the resection guide corresponding to the desired retroversion (Figure 8). Zero degrees of retroversion is preferred since excessive retroversion will restrict joint rotation, especially in external rotation. Retroversion is calculated with reference to the axis of the humeral epicondyles (Figure 8).

Locate the tip of the resection guide in the entry hole and pass the guide down the humeral canal until it rests on the humeral head. With the humeral resection guide rim located on the humeral head, align the orientation pin with the transcondylar axis (Figures 8 and 9).



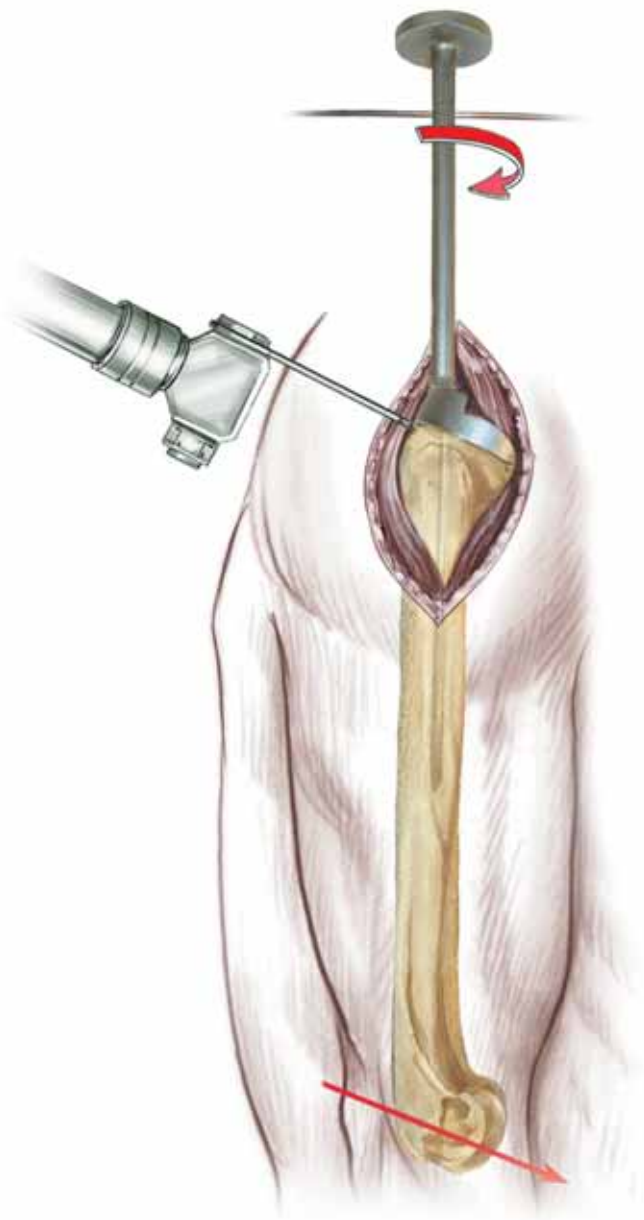


Figure 9  
Head Resection

Initiate humeral head resection in line with the inferior aspect of the humeral resection guide. Remove the humeral resection guide and complete the resection (*Figure 9*). The initial resection removes a minimal amount of bone. More bone may be removed if necessary.

Pass a forked retractor under the scapula to lower the humerus. If this provides clear visualization of the glenoid surface, the resection level is correct. If not, further resection may be carried out.

## Humeral Reaming

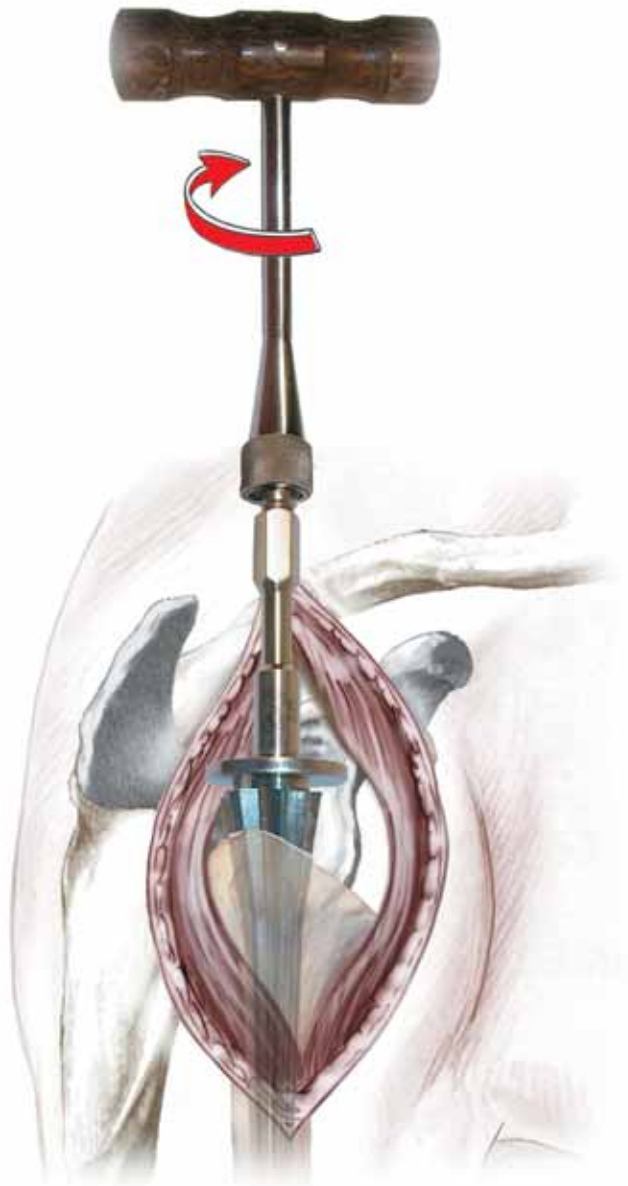


Figure 10  
Humeral Reaming

Note: Some surgeons may prefer to next proceed to glenoid preparation before completing humeral preparation.

### Humeral Reaming

Starting with the smallest diameter distal reamer attached to the T-handle, ream the distal humeral canal in line with the long axis of the humerus (*Figure 10*). The final reamer should not exceed the templated proximal diameter (up to size 4). Stop reaming when the flange of the reamer is level with the lateral resection. **Power reaming should not be used to ream the humerus.**

## Distal Humeral Reaming (Revision Surgery)

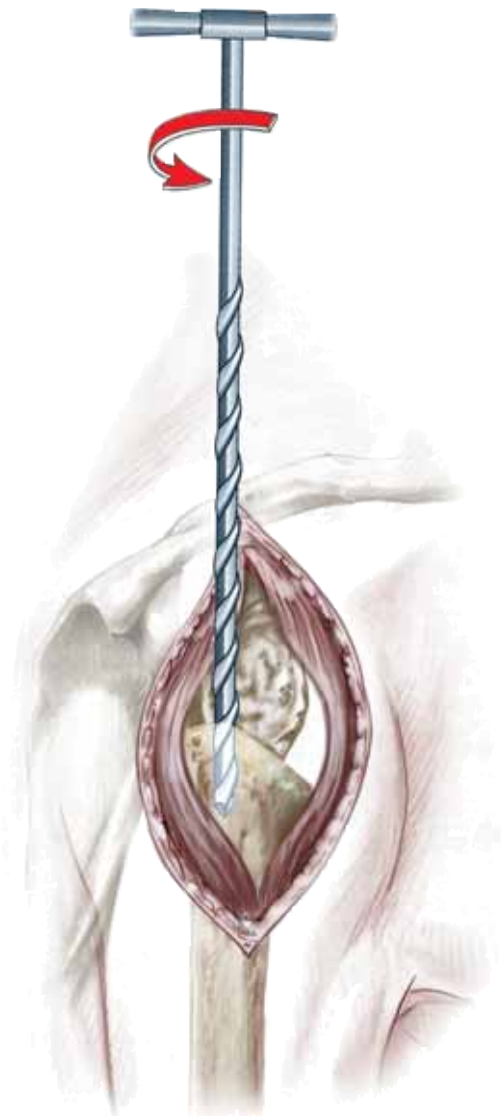

Figure 11  
Reaming – Revision Surgery

### Distal Humeral Reaming (Revision Surgery)

If a long stem is to be implanted, 150 mm and 180 mm diaphyseal revision reamers should be used in conjunction with the rigid reamers that are included within the Delta CTA revision instrumentation (Figure 11).

In addition to the reamers in the accompanying table, 5 mm and 6 mm diameter reamers are provided as start-up reamers.

Diaphyseal references	Reamer references
Size 1, length 150 mm (ref. DHC115B) Size 1, length 180 mm (ref. DHC118B)	7.5 mm diameter (ref. ALR 075)
Size 2, length 150 mm (ref. DHC215B) Size 2, length 180 mm (ref. DHC218B)	8 mm diameter (ref. ALR 008)
Size 3, length 150 mm (ref. DHR315B) Size 3, length 180 mm (ref. DHR318B)	9 mm diameter (ref. ALR 009)

## Proximal Reamer Guide Assembly



Figure 12  
Guide Assembly

### Proximal Reamer Guide Assembly

Referring to the templated epiphysis size, screw the 36 mm or 42 mm proximal reaming guide to the trial diaphyseal stem that matches the distal reamer diameter. Mount the assembly on the humeral stem impactor and introduce in line with the long axis of the humerus (Figure 12).

## Proximal Humeral Reaming

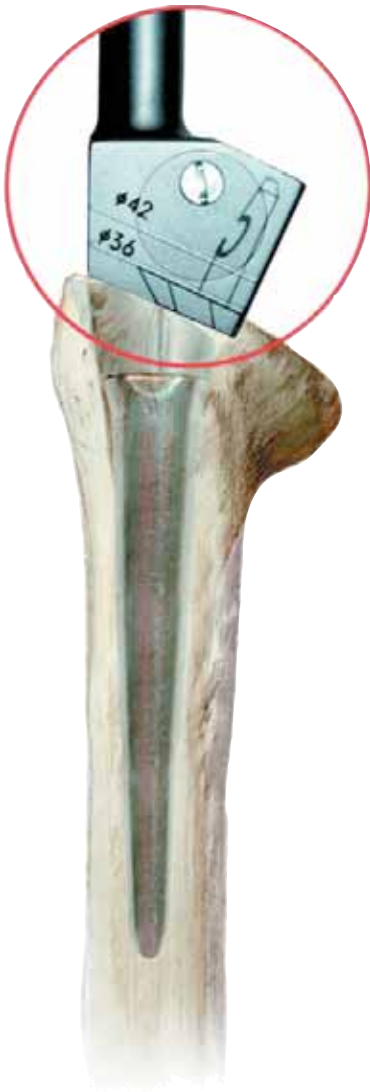

Figure 13  
Determining Depth

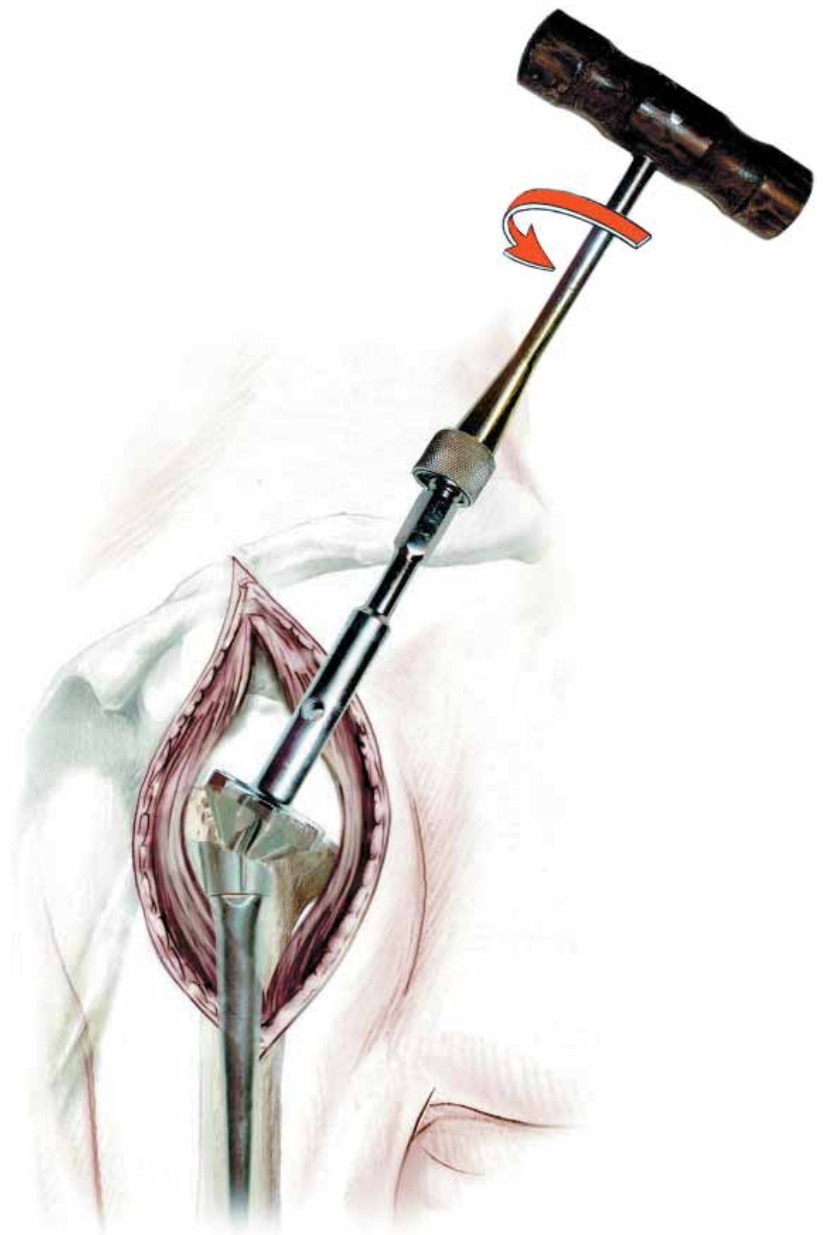

Figure 14  
Proximal Reaming

### Proximal Humeral Reaming

Pass the orientation pin through the hole in the impactor handle and check the previously selected version angle. Impact the assembly into the humeral canal until the appropriate mark (36 mm or 42 mm) on the impactor reaches the level of the resection (*Figure 13*).

Check retroversion again and remove the impactor, leaving the reaming guide in place. Mount the appropriate size proximal humeral reamer, (36.1, 36.2 or 42.2) on the T-handle. The 36 size 1 reamer removes less bone than the 36 size 2 reamer, as shown in the Delta templates. Ream the humerus until the flange of the reamer is level with the osteotomy and contact is made with cortical bone (*Figure 14*).

If necessary, insert the reaming guide more deeply to ensure that the proximal reamer reaches the level of osteotomy. Reaming is now complete. Extract the reamer, reamer guide and trial stem from the humerus.



Figure 15  
Implant Trial Assembly

### Trial Humeral Implantation

Attach the trial epiphyseal component to the trial diaphyseal stem, and mount the assembly onto the humeral stem impactor (Figure 15). It may be necessary to remove a wedge of cortical bone to accommodate the lateral fin on the epiphyseal component. Impact the assembly into the humeral canal, ensuring the diaphyseal fin does not impinge upon the lateral cortex of the humerus. Remove the humeral stem impactor and verify humeral version.

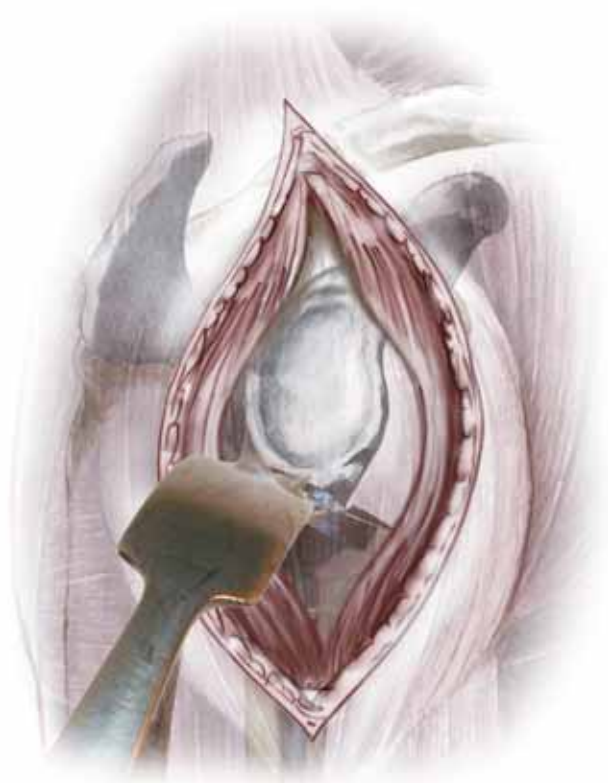

Figure 16  
Glenoid Exposure

### Glenoid Exposure

Position an anterior glenoid neck retractor (Cat. Nos. 2810-16-000 and 2810-17-000) on the axillary margin of the scapula, under the inferior glenoid labrum, to reflect the humerus down or backward, depending on the approach taken. Excise the labrum and perform an extensive periglenoid capsulotomy. Any peripheral osteophytes should be removed to restore the natural anatomic shape of the glenoid (Figure 16).

## Glenoid Preparation

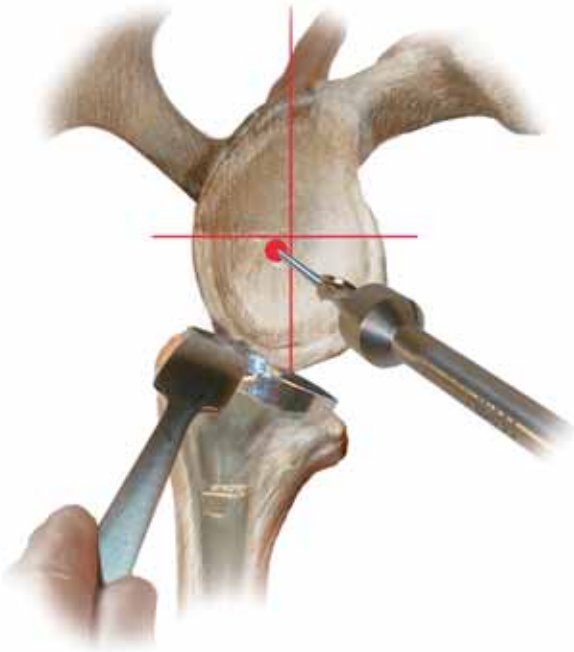


Figure 17a




Figure 17b

Positioning of the metaglene is important to achieve a good, stable range of motion. However, the position must allow the locked superior and inferior screws to be secured in bone.

The metaglene positioner allows the metaglene plate position to be trialed and screw angle checked by passing a K-wire.

The standard position for the metaglene central peg is posterior and inferior to the intersection of the glenoid axes (*Figure 17a*).

However, Radiograph and CT images, combined with X-rays templates can lead to choosing a different position according to the glenoid osseous state.

When the bone stock is sufficient, it is recommended to place the

metaglene as inferior as possible on the glenoid bone in order to limit impingement.

In order to define the optimal metaglene position, the metaglene positioner will be used as described below.

Assemble the positioner by inserting the internal rod into the positioner handle (*Figure 17b*).

## Glenoid Preparation Cont'd



Figure 18

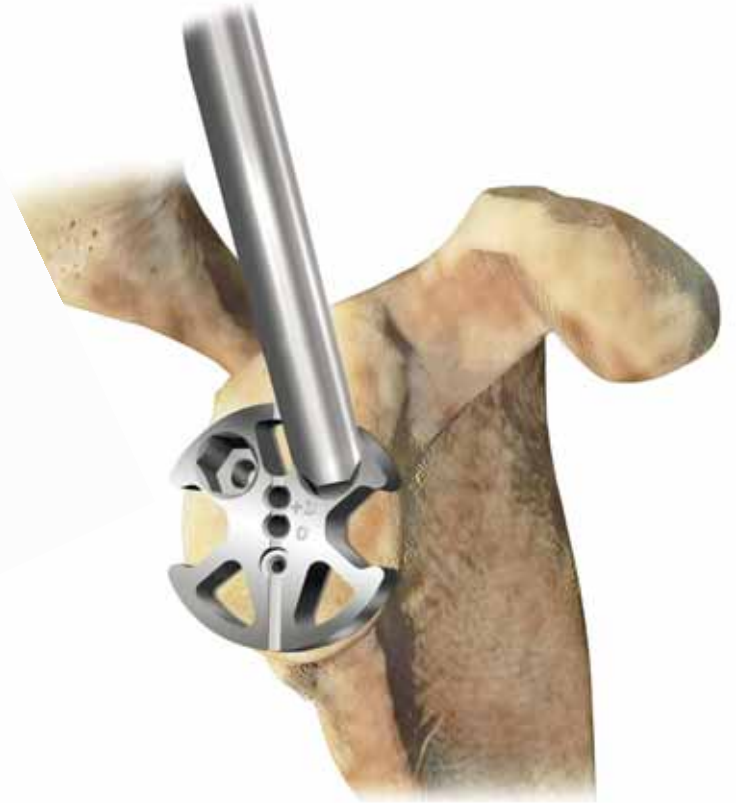

Figure 19

Then insert the hex head tip of the handle into the plate corresponding hole (right or left according to the operated shoulder) and lock the assembly by screwing tightly the internal rod (*Figure 18*).

**Note: The handle is angulated by 20° relative to the plate, for optimal visibility.**

Position the plate as low as possible on the glenoid bone. Align the vertical mark with the scapular neck (*Figure 19*).

## Glenoid Preparation Cont'd

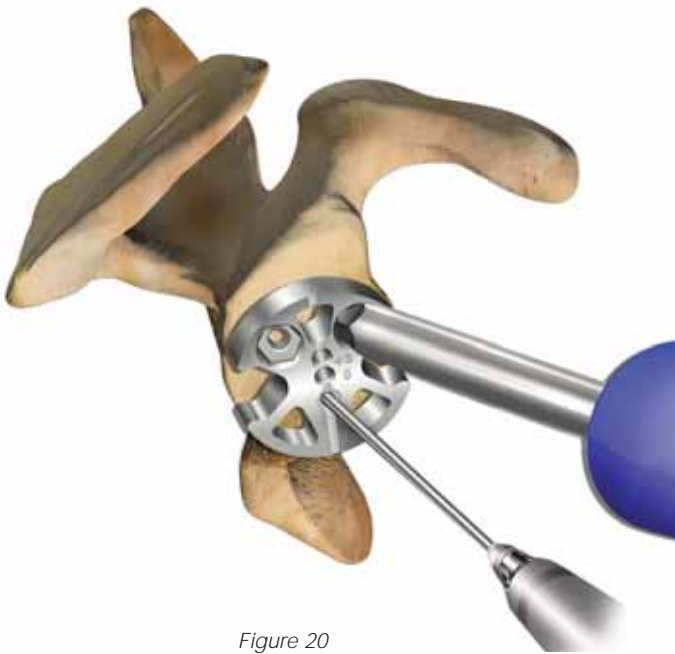


Figure 20

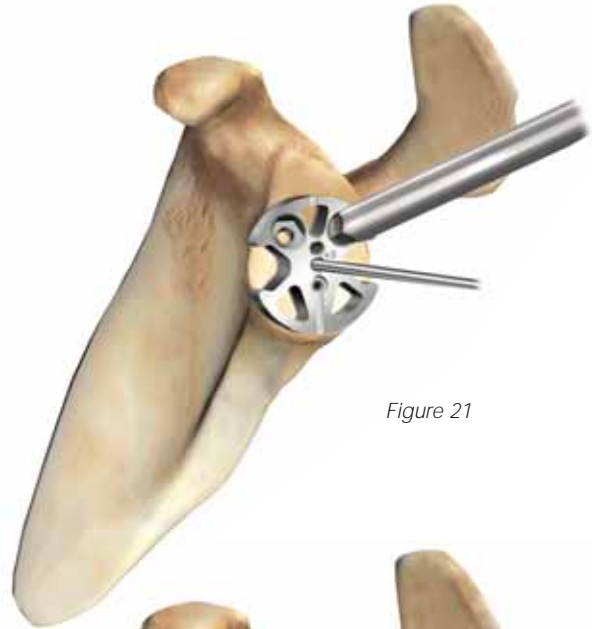


Figure 21

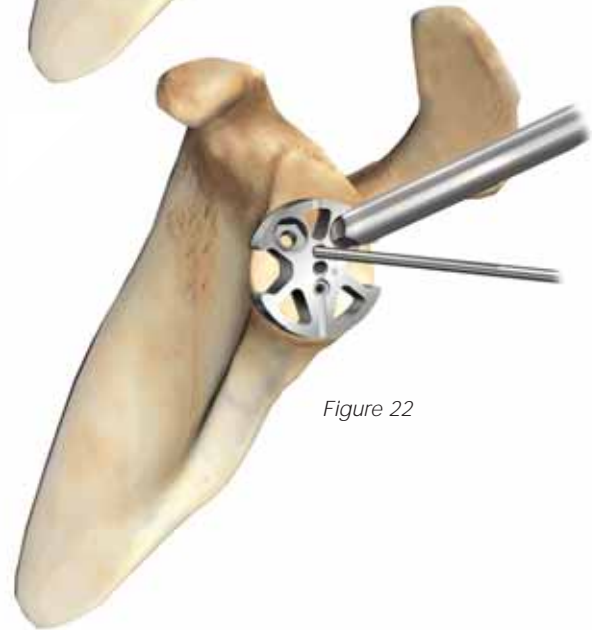


Figure 22

To ensure that the inferior metaglene screw will be fixed in good cancellous bone, introduce the 1.5 mm K-wire (Cat. No. 9375-15-150) into the plate inferior hole, using a power tool. The K-wire is directed at 17° angulation such as the inferior metaglene screw (Figure 20).

If the K-wire stays within bone all along its way, remove it and place the 2.5 mm guide pin into the plate central hole etched +0, using power tool (Figure 21).

If the K-wire emerges from the scapular pillar, place the 2.5 mm guide pin into the upper hole etched +3 (Figure 22). This will move the inferior screw superiorly to keep it within bone.

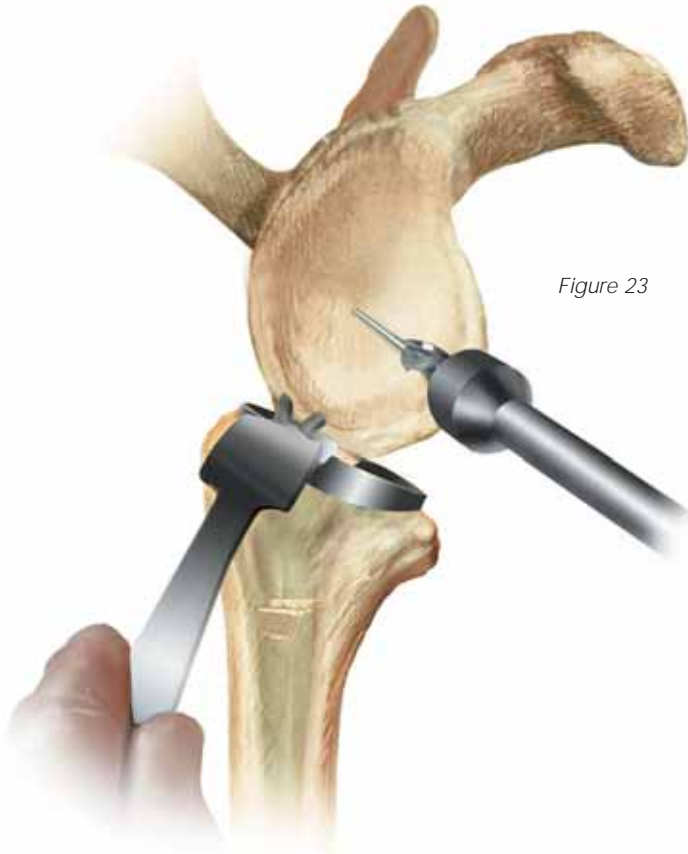

Figure 23

Leave the guide pin in place and remove the metaglene positioner. Attach the cannulated stop drill to the power tool and drill the glenoid central hole over the guide pin (Figure 23).

The glenoid reamer is attached to the power tool and the reamer pilot shaft is introduced into the glenoid centering hole. In cases of osteoporotic bone, hand reaming should be used.

Ensure that the reamer is not in contact with the bone before applying power since this may damage the glenoid.

The glenoid is then reamed until a smooth platform devoid of cartilage is created for the metaglene and

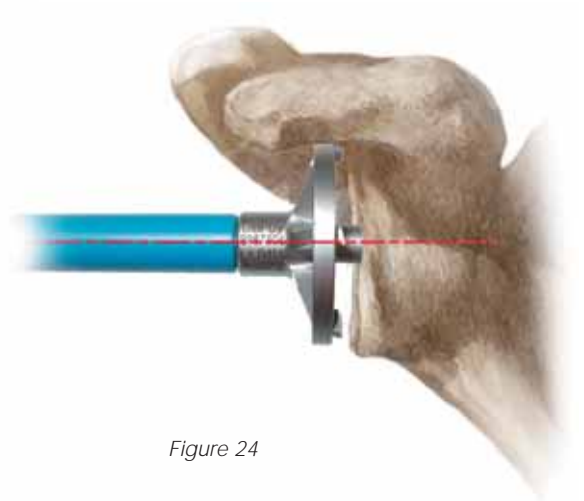


Figure 24

glenosphere, with sufficient depth to accommodate its peripheral rim (Figure 24). The depth should be checked before implantation of the prosthesis. If sufficient peripheral depth is not achieved, the glenosphere will not fully engage with the taper on the metaglene, and further reaming should be carried out until the tray is fully seated.



## Metaglene Insertion

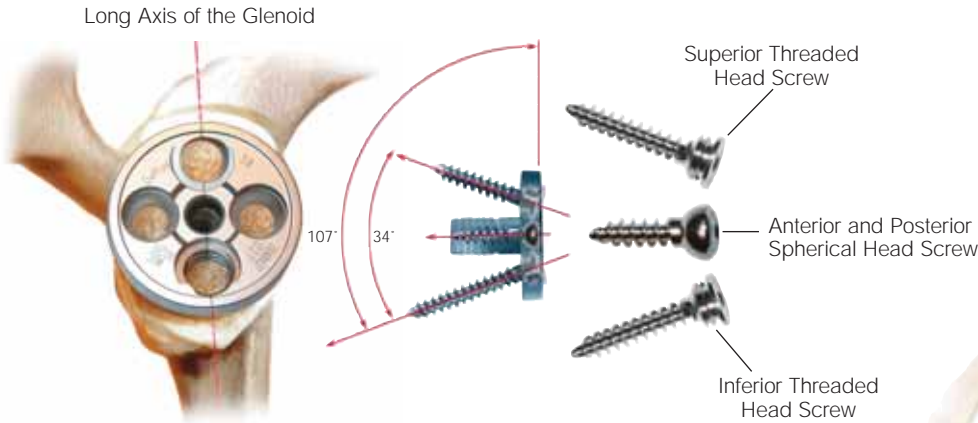


Figure 25

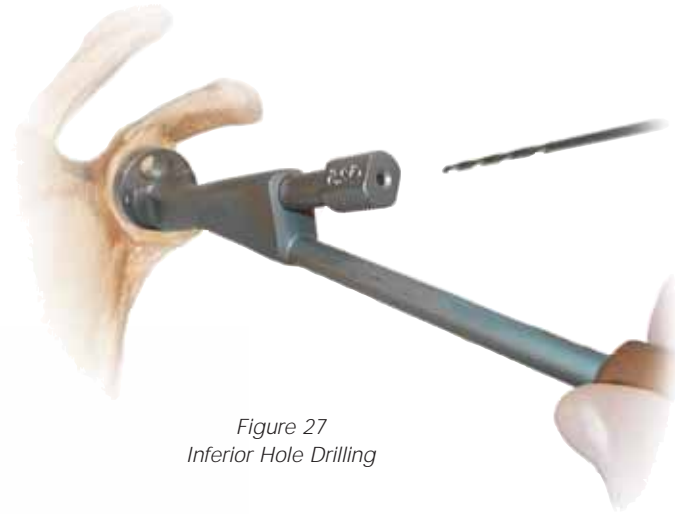

Figure 27  
Inferior Hole Drilling

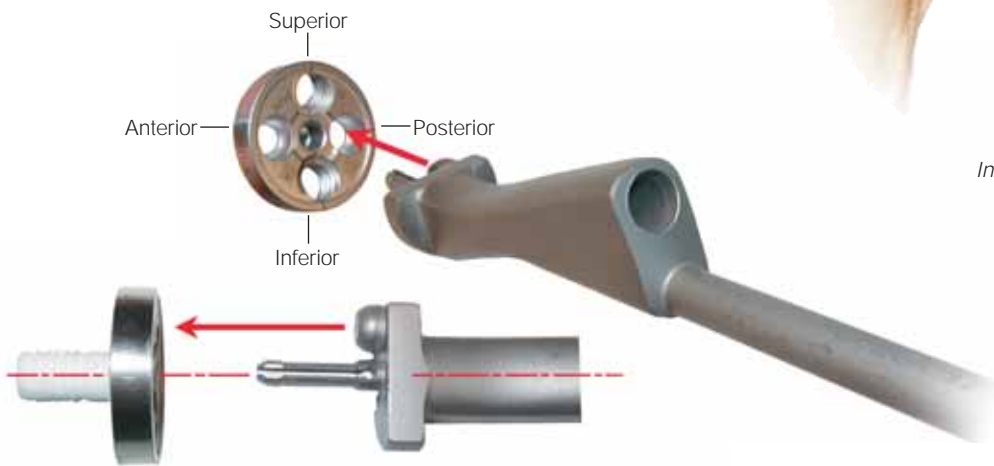


Figure 26  
Drill Guide Orientation

### Metaglene Insertion

The metaglene is available in one size for both 36 mm and 42 mm glenospheres and is implanted without cement. Initial, primary mechanical stability is provided by the 4.5 mm diameter screws. When correctly positioned, the angled, threaded screw holes in the metaglene should be aligned superiorly and inferiorly on the glenoid (Figure 25). After determining there is sufficient bone to support the metaglene and provide screw fixation, attach the definitive metaglene to the holder,

with the drill guide covering the inferior threaded screw hole on the implant (Figure 26). Insert the assembly into the prepared glenoid with the superior and inferior holes aligned with the long axis of the glenoid.

**Caution: It is imperative to use the metaglene holder to insert the inferior and superior screws. The 34-degree angle between these two screws is fixed and cannot be altered.**

Once the metaglene has been manually aligned, tap the holder firmly so that the tray is impacted flat onto the prepared surface of the glenoid. **It is important to ensure that the metaglene is fully seated, flat on the prepared glenoid, before it is screwed into position.**

Then, insert a drill bush 2 or 2.5 mm in diameter, depending on the quality of bone, into the drill guide. Select the corresponding drill, pass through the bush, and drill the inferior fixation hole (Figure 27).

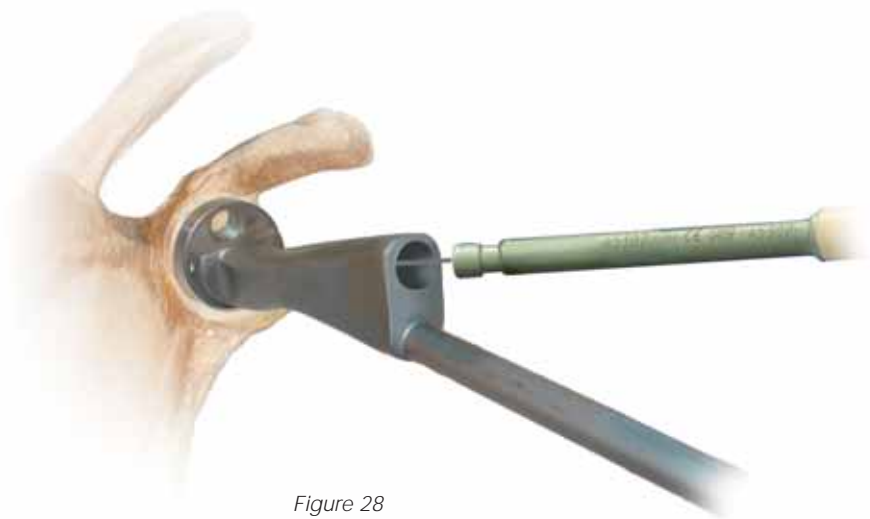


Figure 28  
Depth Measurement

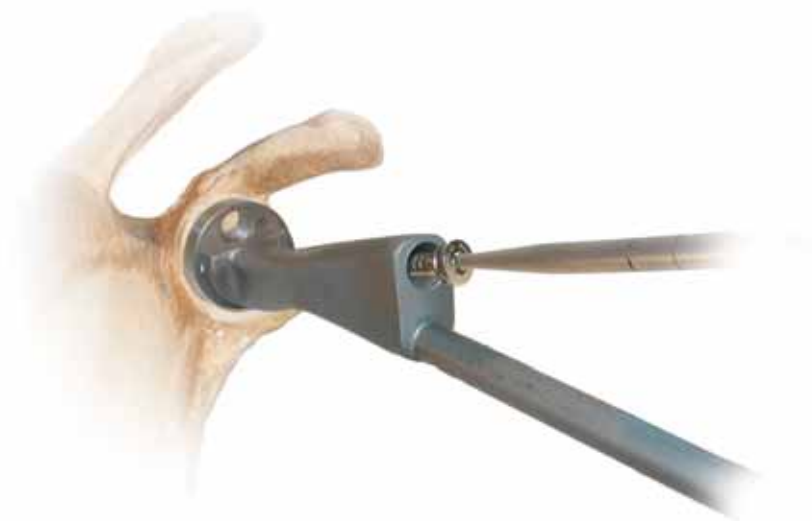

Figure 29  
Screw Placement

Remove the drill bush and check the depth of the screw hole by using the depth gauge provided (*Figure 28*). Threaded head screws must be used for the inferior and superior holes. The spherical head screws are designed for use only with anterior and posterior holes.

A threaded head screw of corresponding length to the measured depth is passed through the drill guide and screwed into the inferior fixation hole. **The screw should be fully tightened at this stage (*Figure 29*).**



Figure 30  
Superior Hole Drilling

Gently detach the metaglene holder from the bearing tray and turn 180 degrees to prepare the superior fixation hole in the same way as the inferior hole.

Measure its depth and screw the appropriate threaded head screw into position (*Figure 30*). Again ensure it is fully tightened.

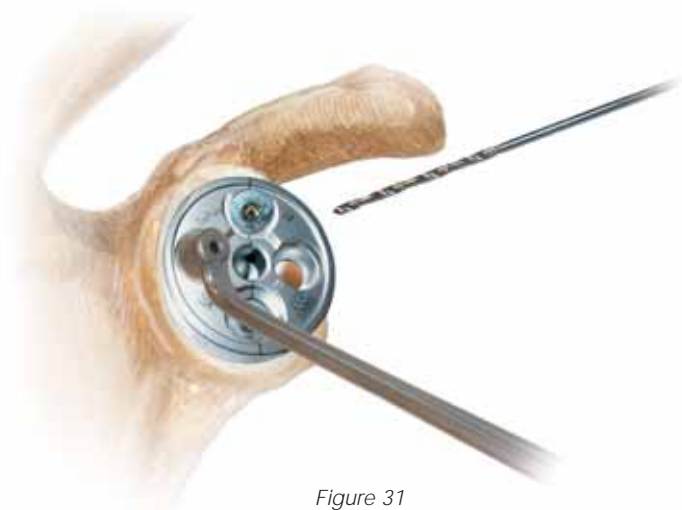


Figure 31  
Anterior Hole Drilling

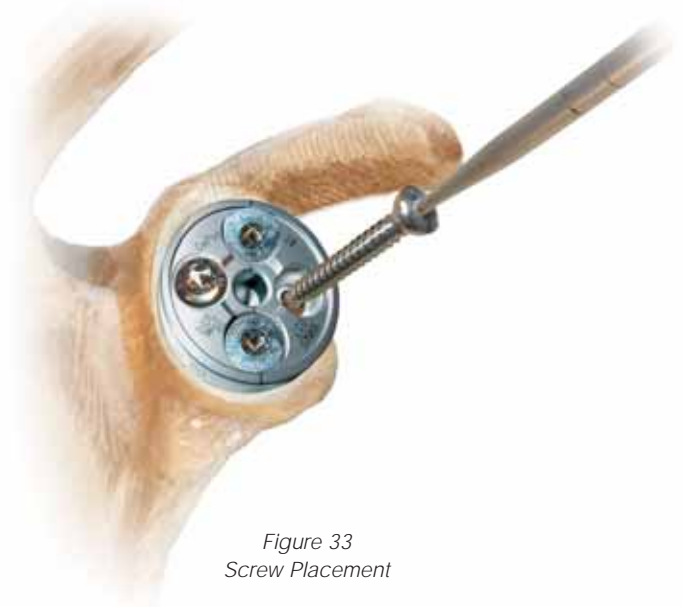


Figure 33  
Screw Placement

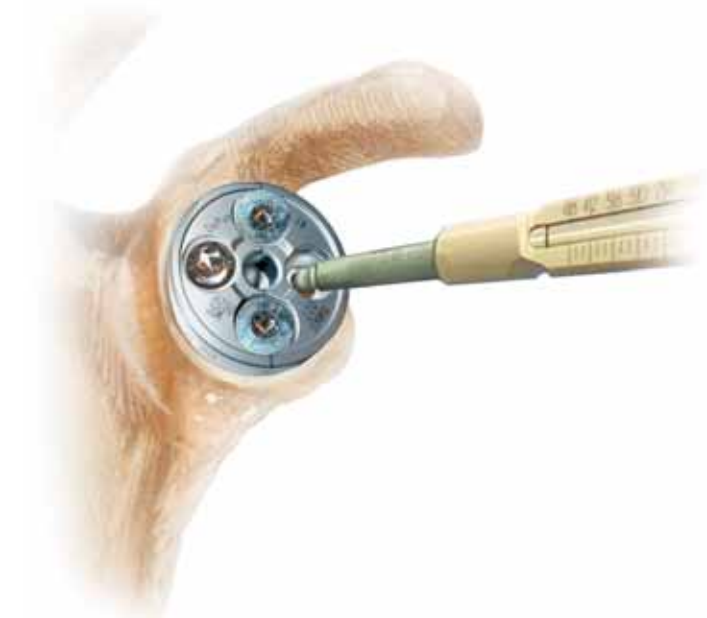

Figure 32  
Depth Measurement

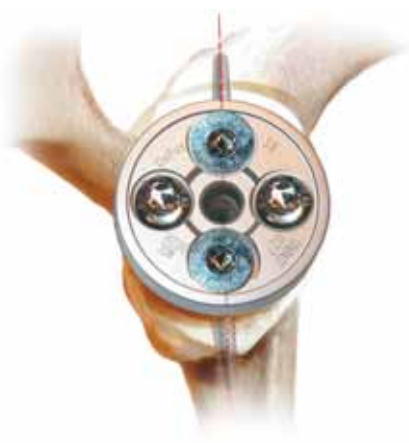


Figure 34  
Final Screw Tightening

Remove the metaglene holder and locate the free hand drill guide of appropriate size, 2.0 or 2.5 mm, in the anterior fixation hole. Both anterior and posterior screw positions allow angulation of  $\pm 20$  degrees. Use the drill guide to set the most appropriate angle to ensure that each screw is located in reliable bone stock (Figure 31).

Preferential position is usually chosen by palpating the anterior and posterior aspects of the scapula as well as examining the X-rays and CT scans.

Drill the anterior hole, remove the drill guide and measure the hole depth using the depth gauge (Figure 32).

Introduce a spherical head screw and partially tighten (Figure 33). Follow the same procedure for the posterior screw. Alternately tighten both screws until fully tightened (Figure 34).

## Trial Reduction

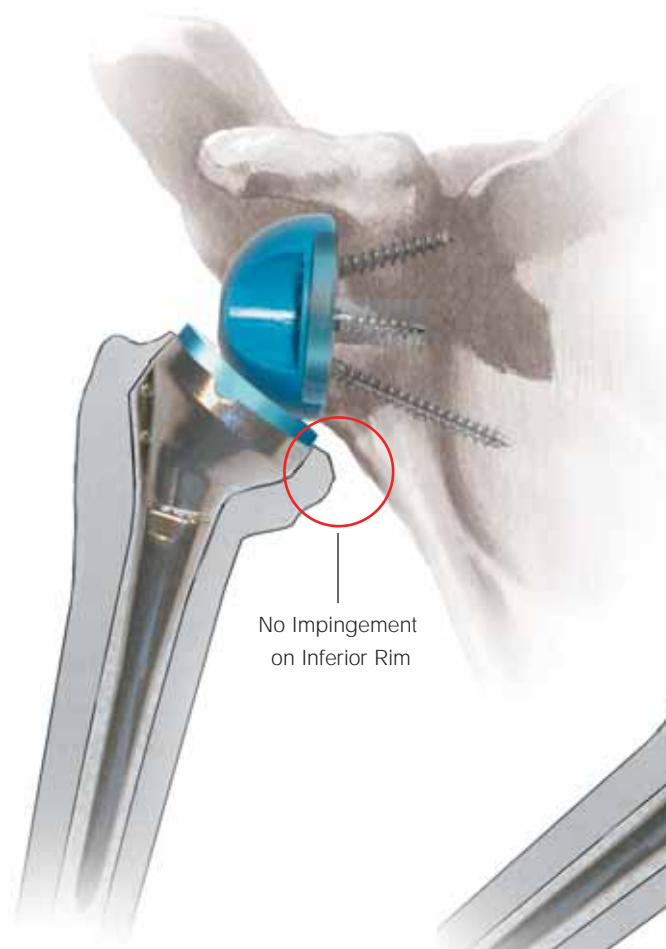


Figure 35

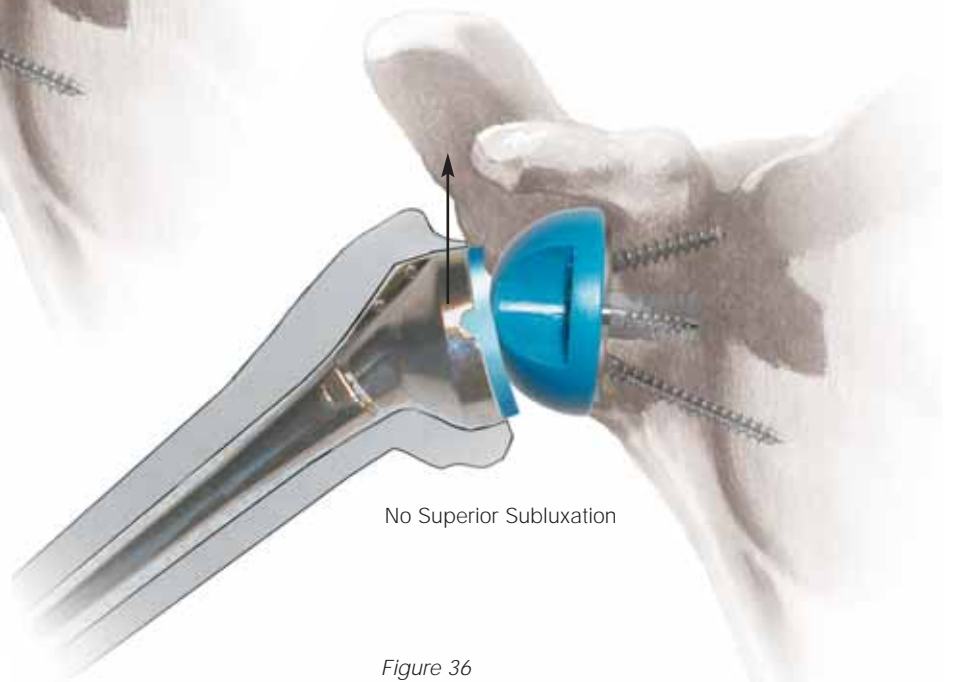


Figure 36

### Trial Reduction

Attach the appropriate trial glenosphere (36 mm or 42 mm) to the metaglene. Insert the corresponding lateralized humeral cup trial (36+6 or 42+6) into the humeral trial assembly. Reduce the shoulder and assess for a full range of movement. If soft tissue tension is correct, the glenoid bearing will not impinge on the inferior rim of the resected humeral head (*Figure 35*). When the arm is pulled down and outward, approximately 5 mm of humeral-glenoid component separation may be expected.

The joint should remain stable when the arm is abducted, with no indication of superior subluxation (*Figure 36*). Additional joint stability may be achieved by introducing a retentive, more constrained cup. If less or more soft tissue tension is required a +3 mm or +9 mm cup can be inserted. If even further tensioning is required, a +9 mm metal humeral spacer with any combination of +3, +6 or +9 polyethylene cup can be used.

A +9 mm humeral spacer may be attached to the trial epiphyseal component, using the hexagonal head screwdriver.

**A retentive cup should only be used in revision cases or to correct extreme instability. If the humeral cut is adequate, a lateralized cup +3, +6 or +9 mm will be sufficient in the majority of cases.**

## Glenosphere Placement

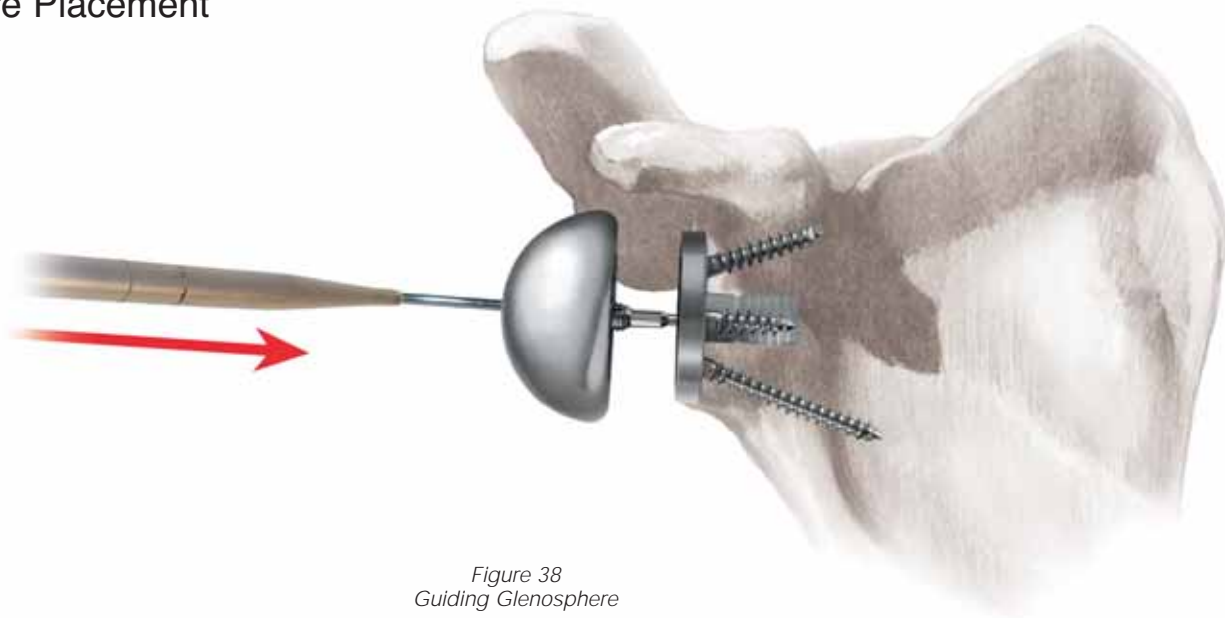


Figure 38  
Guiding Glenosphere

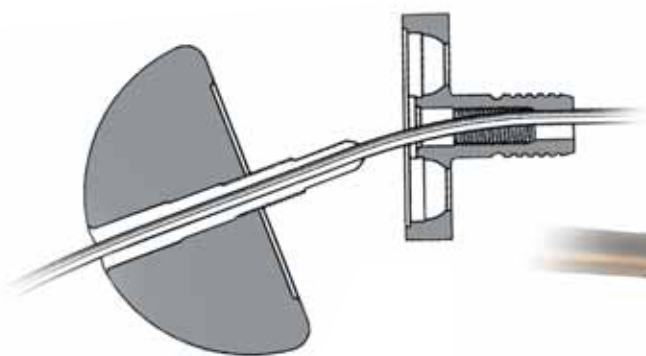


Figure 37  
Inserting Guide Pin

### Glenosphere Placement

Insert a 1.5 mm guide wire through the central hole of the metaglene (*Figures 37 and 38*). Engage the 3.5 mm cannulated screwdriver in the definitive glenosphere and guide over the 1.5 mm guide wire.

After two or three turns, disengage the cannulated screwdriver and check the glenoid bearing to ensure proper alignment. Then re-engage the cannulated screwdriver and tighten the captive screw until the glenoid bearing closes on the taper of the bearing tray (*Figure 39*). Ensure that the glenoid bearing is fully locked onto the bearing tray (*Figure 36*). **It is critical that you use the guidepin in this step or the glenosphere may not screw down correctly.**

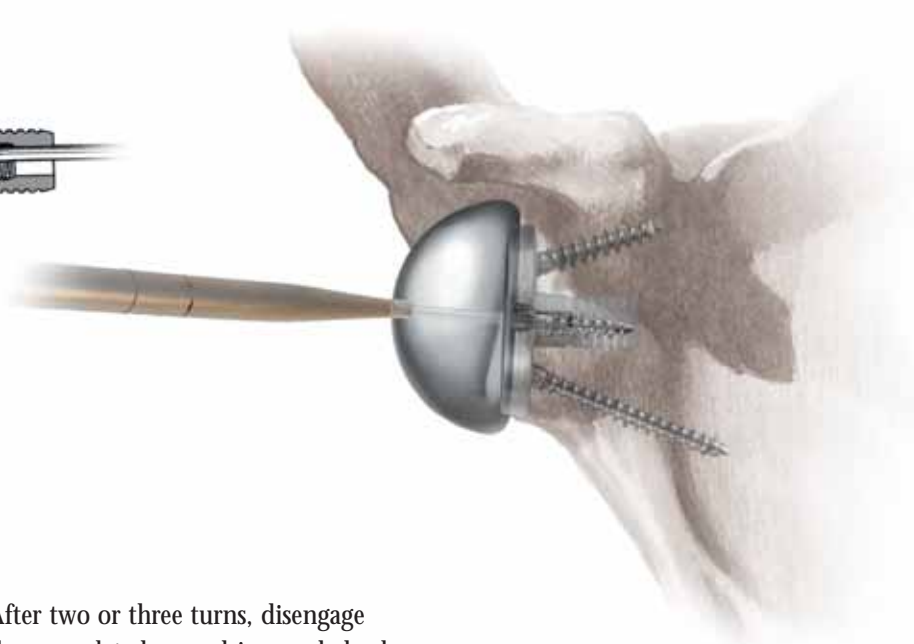


Figure 39  
Engaging Glenosphere

## Humeral Implant Insertion



Figure 40  
Attaching Epiphyseal Component

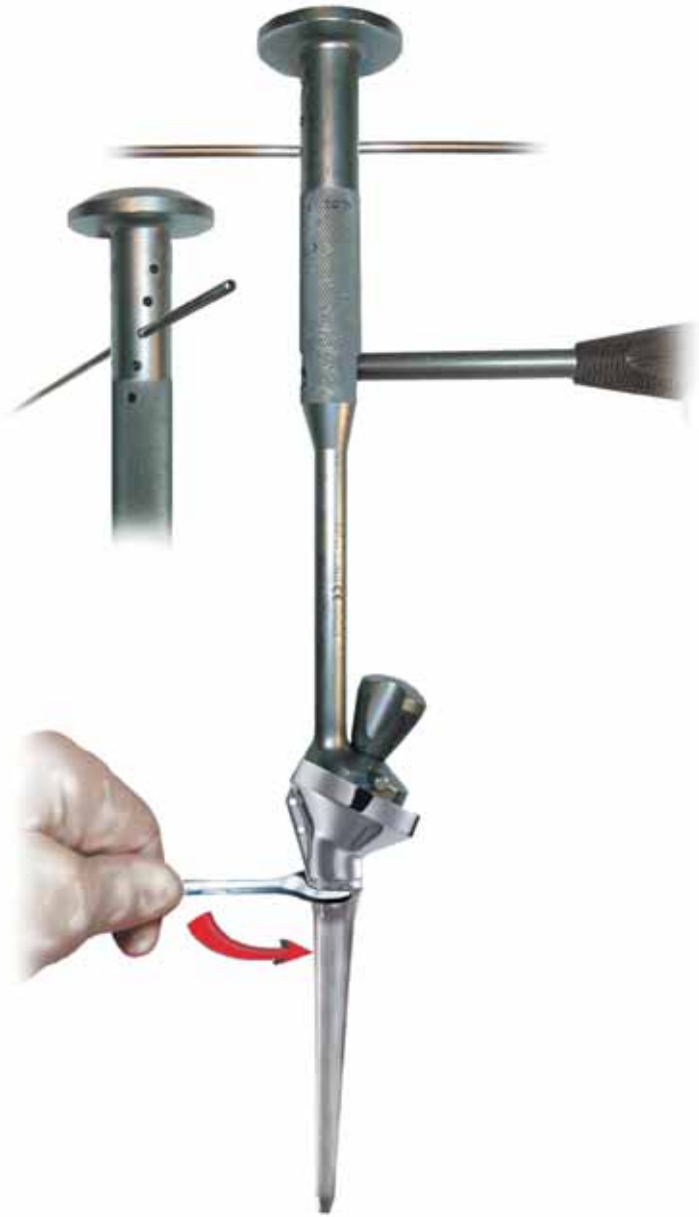

Figure 41  
Attaching Diaphyseal Component

### Humeral Implant Insertion

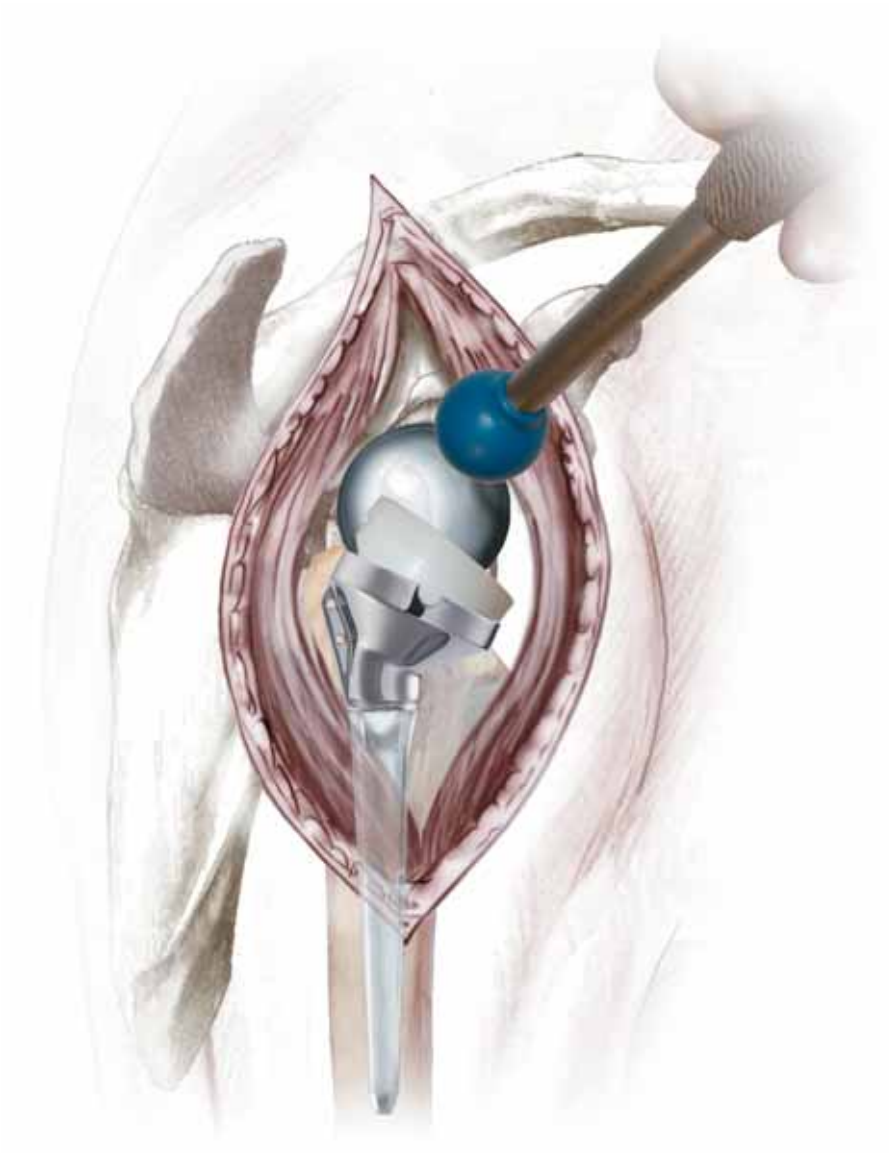
Extract the trial humeral assembly from the humerus. Attach the corresponding definitive humeral epiphyseal component to the impactor (Figure 40). Screw the definitive diaphyseal component to the epiphyseal component. **Lock the two components using the wrench and driver (Figure 41).**

If it was determined during trial reduction that a humeral spacer is needed, attach the humeral spacer to the epiphyseal component using the hex driver and wrench. **Fully tighten the humeral spacer.**

Introduce a cement restrictor, such as BIOSTOP® G or a bone plug, into the distal humeral canal to restrict the passage of cement. Introduce cement, such as SmartSet® HV or

DePuy 1 (high viscosity bone cements) or SmartSet® MV (medium viscosity bone cement), into the humeral canal and, when the cement is at its appropriate viscosity, introduce the implant assembly in line with the long axis of the humerus and in the chosen version angle. Maintain pressure on the introducer until the cement is fully polymerized.

## Humeral Implant Insertion



*Figure 42*  
*Impacting Humeral Cup*

After the implant is fully seated, trial for soft tissue tensioning again before selecting the final humeral component. Using the cup impactor, impact the definitive humeral cup. Ensure it is fully seated and secure into the snap fit (*Figure 42*). Reduce the joint and make a final assessment of joint stability and range of motion.

## Closure

Once the joint space is irrigated and cleared of debris, firmly suture the anterior deltoid at the fibrous acromial perimeter or use transosseous stitches. A drain may be left in place. Layered closure of the soft tissues normally leads to an adequate range of motion, without instability.

## Postoperative Management

Appropriate postoperative physiotherapy is an important factor in the outcome of this procedure, since stability and mobility now depend on the deltoid alone. The physiotherapy program, which should be planned to suit the individual patient, consists of two phases: early (6 weeks) and late. Two days after the operation the patient can be mobile. This early phase is dedicated to gentle and gradual recovery of the passive range of shoulder motion: abduction of the scapula, anterior elevation and medial and lateral rotation. An abduction cushion may be used to relieve pressure on the deltoid.

Physiotherapy is mainly performed with the patient supine, passive and with both hands holding a bar that is manipulated by the contralateral hand, as described by Neer.

The patient is encouraged to use the affected arm to eat and write but should not raise the arm. In conjunction with these exercises for scapulohumeral recovery, it is important to strengthen muscle connection with the scapula in order to facilitate muscle and implant function. Passive exercise in the swimming pool is recommended as soon as scars begin to form. After the sixth or seventh week, active strengthening movements may be gradually added to the program. These exercises, which closely follow everyday activities, are performed in a sitting or standing position, using conventional methods, with isometric exercises and resistance movements becoming increasingly important.

A series of exercises for rhythmic stabilization of the upper arm as well as eccentric working on lowering the arms complete the strengthening of the muscles. Physiotherapy should be performed over a period of at least six months.

















## Ordering Information

### Implant

<b>Cat. No.</b>	<b>Description</b>
EHC361B	Cemented Humeral Epiphysis, 36.1 mm
EHC362B	Cemented Humeral Epiphysis, 36.2 mm
EHC422B	Cemented Humeral Epiphysis, 42.2 mm
DHC010B	Cemented Humeral Diaphysis, Size 0, 85 mm
DHC110B	Cemented Humeral Diaphysis, Size 1, 86 mm
DHC210B	Cemented Humeral Diaphysis, Size 2, 88 mm
DHC310B	Cemented Humeral Diaphysis, Size 3, 89 mm
DHC410B	Cemented Humeral Diaphysis, Size 4, 94 mm
DHC115B	Revision Cemented Humeral Diaphysis Size 1 (150 mm)
DHC215B	Revision Cemented Humeral Diaphysis Size 2 (150 mm)
DHC315B	Revision Cemented Humeral Diaphysis Size 3 (150 mm)
DHC118B	Revision Cemented Humeral Diaphysis Size 1 (180 mm)
DHC218B	Revision Cemented Humeral Diaphysis Size 2 (180 mm)
DHC318B	Revision Cemented Humeral Diaphysis Size 3 (180 mm)
4CHS036R	Medialized Retentive Humeral Cup, 36 mm diameter + 0 mm
4CHS042R	Medialized Retentive Humeral Cup, 42 mm diameter + 0 mm
4CHL336	Lateralized Humeral Cup, 36 mm diameter + 3 mm
4CHL342	Lateralized Humeral Cup, 42 mm diameter + 3 mm
4CHL636	Lateralized Humeral Cup, 36 mm diameter + 6 mm
4CHL636R	Lateralized Retentive Humeral Cup, 36 mm diameter + 6 mm
4CHL642	Lateralized Humeral Cup, 42 mm diameter + 6 mm
4CHL642R	Lateralized Retentive Humeral Cup, 42 mm diameter + 6 mm
4CHL936	Lateralized Humeral Cup, 36 mm diameter + 9 mm
4CHL942	Lateralized Humeral Cup, 42 mm diameter + 9 mm
RTH236	Humeral Spacer, 36 mm + 9
RTH242	Humeral Spacer, 42 mm + 9
MGC002H	Standard Metaglène
GSC236	Glenosphere 36 mm
GSC242	Glenosphere 42 mm
VFM4524	Metaglène Screws, Dia. 4.5 x 24 mm (Threaded Head)
VFM4530	Metaglène Screws, Dia. 4.5 x 30 mm (Threaded Head)
VFM4536	Metaglène Screws, Dia. 4.5 x 36 mm (Threaded Head)
VFM4542	Metaglène Screws, Dia. 4.5 x 42 mm (Threaded Head)
VFM4548	Metaglène Screws, Dia. 4.5 x 48 mm (Threaded Head)
VSM4518	Metaglène Screws, Dia. 4.5 x 18 mm (Spherical Head)
VSM4524	Metaglène Screws, Dia. 4.5 x 24 mm (Spherical Head)
VSM4530	Metaglène Screws, Dia. 4.5 x 30 mm (Spherical Head)
VSM4536	Metaglène Screws, Dia. 4.5 x 36 mm (Spherical Head)
VSM4542	Metaglène Screws, Dia. 4.5 x 42 mm (Spherical Head)

# Humeral Preparation Instruments

Cat. No.	Description	
GSH002	Humeral Resection Guide	
ARR001	Orientation Pin	
FPH361	Proximal Humeral Reamer, 36.1	
FPH362	Proximal Humeral Reamer, 36.2	
FPH422	Proximal Humeral Reamer, 42.2	
FDH036N	Distal Humeral Reamer, Size 0, Dia. 36 mm	
FDH136	Distal Humeral Reamer, Size 1, Dia. 36 mm	
FDH236	Distal Humeral Reamer, Size 2, Dia. 36 mm	
FDH336	Distal Humeral Reamer, Size 3, Dia. 36 mm	
FDH436	Distal Humeral Reamer, Size 4, Dia. 36 mm	
FDH142	Distal Humeral Reamer, Size 1, Dia. 42 mm	
FDH242	Distal Humeral Reamer, Size 2, Dia. 42 mm	
FDH342	Distal Humeral Reamer, Size 3, Dia. 42 mm	
FDH442	Distal Humeral Reamer, Size 4, Dia. 42 mm	
ITH003	Humeral Stem Impactor/Extractor	
EHF001	Forked Retractor	
EHF002	U-forked Retractor	
GFP136	Proximal Reamer Guide, Dia. 36	
GFP142	Proximal Reamer Guide, Dia. 42	
IGF004	Reamer Guide Impactor/Extractor	
CLE014	Diaphyseal Stem Locking Wrench	
DHF010N	Humeral Diaphysis Trial, Size 0	
DHF110	Humeral Diaphysis Trial, Size 1	
DHF210	Humeral Diaphysis Trial, Size 2	
DHF310	Humeral Diaphysis Trial, Size 3	
DHF410	Humeral Diaphysis Trial, Size 4	
EHF361	Humeral Epiphysis Trial, 36.1	
EHF362	Humeral Epiphysis Trial, 36.2	
EHF422	Humeral Epiphysis Trial, 42.2	
REH236	Humeral Spacer Trial, Dia. 36	 
REH242	Humeral Spacer Trial, Dia. 42	
A5265	Medialized Retentive Humeral Cup Trial, Dia. 36 mm	
A5264	Lateralized Humeral Cup Trial, Dia. 36 mm	
A5263	Lateralized Retentive Humeral Cup Trial, Dia. 36 mm	
A5262	Medialized Retentive Humeral Cup Trial, Dia. 42 mm	
A5261	Lateralized Humeral Cup Trial, Dia. 42 mm	
A5260	Lateralized Retentive Humeral Cup Trial, Dia. 42 mm	
TEH036	Humeral Head Trial Dia. 36 mm	 
TEH042	Humeral Head Trial Dia. 42 mm	
TEH436	Humeral Head Trial Dia. 36 mm + 4	
TEH442	Humeral Head Trial Dia. 42 mm + 4	

## Glenoid Preparation Instruments

Cat. No.	Description
A5267	Cannulated Stop Drill
A5075	Glenoid Surfacing Rasp, Dia. 36
A5076	Glenoid Surfacing Rasp, Dia. 42
PAM001	T-handle
A5271	Drill Bush, Dia. 2.0
A5272	Drill Bush, Dia. 2.5
GPM020	Drill Guide, Dia. 2.0
GPM025	Drill Guide, Dia. 2.5
A5326	S/I Drill Bit, Dia. 2.0 (170 mm Length)
A5327	S/I Drill Bit, Dia. 2.5 (170 mm Length)
MPG020	A/P Drill Bit, Dia. 2.0 (100 mm Length)
MPG025	A/P Drill Bit, Dia. 2.5 (100 mm Length)
A5273	Glenosphere Trial, Dia. 36
A5274	Glenosphere Trial, Dia. 42
9E03011	3.5 mm Hex. Head Screwdriver, Cannulated
A5307	Screw Depth Gauge
PRT001	Standard Impactor Holder
EPT001	Humeral Head Impactor
EPC032	Humeral Cup Impactor
A5268	Metaglène Holder
A5470	Delta Metaglène Positioner Plate
A5471	Delta Metaglène Positioner Handle
A5472	Delta Pin for Metaglène Positioner



### Guide Pins and Guide Wires

Cat. No.	Description
A5266	Guide Pin
A5074	1.5 mm Guide Wire
9375-15-150	Kirschner K-Wire Dia. 1.5 mm Lg. 150 mm



### Trays

Cat. No.	Description
A5807	Glenoid Tray Base
A5831	Upper Glenoid Tray
A5812	Glenoid Tray Lid
A5815	Glenoid Tray Screw Rack
A5809	Humeral Tray 1 Base
A5808	Humeral Tray 1 Insert
A5813	Humeral Tray 1 Lid
A5811	Humeral Tray 2 Base
A5810	Humeral Tray 2 Insert
A5814	Humeral Tray 2 Lid
A5819	Tray insert for Cups

## Delta Revision

### Instruments

<b>Cat. No.</b>	<b>Description</b>
ETH001	Standard Humeral Prosthesis Extractor
MDE001	Extraction Rod
MAI001	Slap Hammer
TEP035	3.5 mm Hex. Head Screwdriver
TEP025	2.5 mm Hex. Head Screwdriver
ALR005	Diaphyseal Reamer, Dia. 5 mm
ALR006	Diaphyseal Reamer, Dia. 6 mm
ALR075	Diaphyseal Reamer, Dia. 7.5 mm
ALR008	Diaphyseal Reamer, Dia. 8 mm
ALR009	Diaphyseal Reamer, Dia. 9 mm
DHF115	150 mm Long Humeral Diaphysis Trial, Size 1
DHF215	150 mm Long Humeral Diaphysis Trial, Size 2
DHF315	150 mm Long Humeral Diaphysis Trial, Size 3
DHF118	180 mm Long Humeral Diaphysis Trial, Size 1
DHF218	180 mm Long Humeral Diaphysis Trial, Size 2
DHF318	180 mm Long Humeral Diaphysis Trial, Size 3
A5288	Metaglène Extractor

### Trays

<b>Cat. No.</b>	<b>Description</b>
A5280	Tray Base
A5281	Tray Insert
A5279	Lid



## REFERENCES

1. Baulot, E., E. Garron and P. Grammont. "La Prothèse de Grammont dans les cas d'Ostéonécrose de la tête Humérale." *Acta Orthopaedica Belgica* 65 (Supplement 1), 1999.
2. Bouttens, D. and C. Nérot. "G.E.E.D. La Prothèse Delta dans l'Omarthrose Excentrée Résultats à Moyen et Long Terme (1991-1994)." Communication Présentée au Congrès de la Prothèse d'Épaule. Paris, January 2000.
3. Bradley, T., A. Boulahia, G. Walch and R. Baratta. "Early Results of a Reverse Design Prosthesis in the Treatment of Arthritis of the Shoulder in Elderly Patients with a Large Rotator Cuff Tear." Presented at AAOS, Dallas, February, 2002.
4. Cazeneuve, J.F. and I. Saltanove. "Reverse Total Shoulder Arthroplasty (Grammont's Arthroplasty) for Acute Complex Fractures of Proximal Humerus. Five Years Experience." Presented at SECEC. June, 1998.
5. Cazeneuve, J.F. and F. Kermad. "Grammont's Arthroplasty for Acute Complex Fractures of Proximal Humerus in Elderly Population: Six Years Experience." SECEC – abstract. The Hague, Netherlands, 1999.
6. Cazeneuve, J.F., V.B. Dang and T. Zanfonhouede. "A Six Year Experience of Reverse Total Shoulder Arthroplasty (Grammont's Arthroplasty) in Elderly Population for Four-part Fractures of the Proximal Humerus." European Federation of the National Association of Orthopaedics and Traumatology Congress. Brussels, Belgium, June 1999.
7. Constant, C.R. and A.H.G. Murley. "A Clinical Method of Functional Assessment of the Shoulder." *Clinical Orthopaedics and Related Research* 214, 1987: 160-164.
8. De Buttet, M., Y. Bouchon, D. Capon and J. Delfosse. "Grammont Shoulder Arthroplasty for Osteoarthritis with Massive Rotator Cuff Tears – Report of 71 Cases." *Journal of Shoulder and Elbow Surgery* 6, 1997: 197 (abstract 14).
9. Delloye, C., D. Joris, A. Colette, A. Eudier and J.E. Dubuc. "Mechanical Complications of Total Shoulder Inverted Prosthesis." *Rev Chir Orthop Reparatrice Appar Mot* 88, 2002: 410-414.
10. De Wilde, L., M. Mombert, R. Van Petegem and R. Verdonk. "Revision of Shoulder Replacement with a Reversed Shoulder Prosthesis (Delta III): Report of Five Cases." *Acta Orthopaedica Belgica* 67, 2001.
11. De Wilde, L. and E. Audenaert. "A Comparative Biomechanical Analysis of Ten Different Prosthesis for Rotator Cuff Tear Arthroplasty." SECEC – abstract. Heidelberg, Germany, September 24-27, 2003.
12. De Wilde, L., E. Van Ovost, D. Uyttendaele and R. Verdonk. "Results of an Inverted Shoulder Prosthesis After Resection for a Tumor of the Proximal Humerus." *Rev Chir Orthop Reparatrice Appar Mot* 88, 2002: 373-378.
13. Ekelund, A., L. De Wilde, L. Seebauer, C. Nerot, D. Capon and P. Valenti. "Clinical Results of the Reversed Delta Shoulder Arthroplasty: A Multicentre Study with Minimum 5 Years Follow-up." 17th Congress of the European Society for Surgery of the Shoulder and the Elbow (ESSSE/SECEC) – poster. Heidelberg, Germany, September 24-27, 2003.
14. Gerber, A., P. Roache and C. Gerber. "The Delta III Reversed Prosthesis: Weapon of the Devil or an Acceptable Salvage Procedure." Presented at the 8th ICSS. Cape Town, April, 2001.
15. Gilbert, M.K., C. Pirkel and C. Gerber. "Complications Associated with the Delta III Reverse Ball-and-socket Shoulder Prosthesis." SECEC – abstract. Heidelberg, Germany, September 24-27, 2003.
16. Grammont, P., P. Trouilloud, J.P. Laffay and X. Deries. "Etude et Réalisation d'Une Nouvelle Prothèse d'Épaule." *Rhumatologie* 39, 1987: 407-418.
17. Grammont, P. "Shoulder Prosthesis for Rotator Cuff Rupture." *Ed. The Shoulder*. Groningen, 1991.
18. Grammont, P. and E. Baulot. "Delta Shoulder Prosthesis for Rotator Cuff Rupture." *Orthopaedics* 16(1), 1993: 65-68.
19. Grammont, P., E. Baulot and D. Chabernaud. "Résultats de la Prothèse Inversée de Grammont pour des Omarthroses Associées à de Grandes Destructures de la Coiffe." *Acta Orthopaedica Belgica* 61(Supplement 1), 1995: 112-119.
20. Habermeyer, P. "Open Treatment of Rotator Cuff Lesions." *Orthopade* 24, 1995: 512-528.
21. Handelberg, F.W.J. "Treatment Options in Full Thickness Rotator Cuff Tears." *Acta Orthopaedica Belgica* 67, 2001: 110-115.
22. Jacobs, R., De Smet and L. Debeet. "Treatment of Rotator Cuff Arthroplasty with a Delta Shoulder Prosthesis." *Acta Orthopaedica Belgica* 67, 2001.
23. Julien, Y., I. Gondrand, C. Charpenay, L. Devilliers, E. Baulot and P. Trouilloud. "Shoulder Reconstruction Using Grammont (Delta III) Total Arthroplasty After Resection for Malignant Bony Tumors of Proximal Humerus." *European Journal of Orthopaedic Surgery and Traumatology* 13, 2003: 77-79.
24. Kralinger, F., K. Golsner and V. Smekal. "First Experiences with the Delta III Inversoprosthesis." Presented at the 8th ICSS. Cape Town, April 2001.
25. Lee, D. "Bipolar Shoulder Arthroplasty." *Clinical Orthopaedics and Related Research* 304, 1994.
26. Meskens, M. and P. Broos. "Massive Rotator Cuff Tears with Pseudoparalysis and Rotator Cuff Arthropathy Treated by the Reversed Delta Prosthesis." *Tijdschrift Voor Geneeskunde* 58, 2002: 331-337.
27. Postacchini, F., S. Gumina, and P. De Santis et al. "Cuff Tear Arthropathy: Mid-term Outcomes with Reverse Prosthesis." SECEC– abstract. Heidelberg, Germany, September 24-27, 2003.
28. Renaud, P., H. Wahab, L. Bontoux, M. Dauty, I. Richard and C. Bregeon. "Total Inverted Shoulder Prosthesis and Rotator Cuff Insufficiency: Evaluation and Determination of Anatomical Parameters Predictive of Good Functional Outcome in 21 Shoulders." *Ann Readapt Med Phys* 44, 2001: 273-280.
29. Rittmeister, M. and F. Kerschbaumer. "Grammont Reverse Total Shoulder Arthroplasty in Patients with Rheumatoid Arthritis and Nonreconstructible Rotator Cuff Lesions." *Journal of Shoulder and Elbow Surgery* 10, 2001: 17-22.
30. Seebauer, L. "Biomechanical Classification of Cuff Tear Arthropathy." Global Shoulder Society Meeting (abstract). Salt Lake City, Utah. July 17-19, 2003.
31. Seebauer, L. and W. Keyl. "Treatment of Cuff Tear Arthropathy with an Inverted Shoulder Prosthesis (Delta III – Grammont)." Presented at the 8th International Conference on Surgery of the Shoulder. Cape Town, South Africa, April 2001.
32. Sirveaux, F., L. Favard, D. Oudet, D. Huguet and S. Lautman. "Grammont Inverted Total Shoulder Arthroplasty in the Treatment of Glenohumeral Osteoarthritis with Massive and Non-repairable Cuff Rupture." Presented at the Congress 2000 Shoulder Prostheses. Two to ten year follow-up. Nice, September, 2001.
33. Sirveaux, F., O. Roche, A. Raphoz, O. Gosselin, M. De Gasperi and D. Mole. "Hemiarthroplasty versus Inversed Prosthesis in the Treatment of Proximal Humerus Fractures: a Prospective Randomized Study in the Elderly." SECEC – abstract. Heidelberg, Germany, September 24-27, 2003.
34. Slimani, S., H. Coudane, D. Marcon and E. Lesur. "Evaluation des Reprises Chirurgicales des Prothèses Totales d'Épaule: Étude Longitudinale Prospective." Communication Présentée à la 76<sup>ème</sup> Réunion Annuelle de la SOFCOT. November, 2001.
35. Sperner, G., F. Kralinger, K. Golsner and V. Smekal. "First Experiences with the Delta III Inversoprosthesis." Presented at the 8th International Conference on Surgery of the Shoulder. Cape Town, South Africa, April 2001.
36. Valenti, P., D. Bouttens and C. Nérot. "GED: Delta III Reversed Prosthesis for Osteoarthritis with Massive Rotator Cuff Tear: Long Term Results (>5 years)." Presented at the Congress 2000 Shoulder Prostheses. Two to ten year follow-up. Nice, September, 2001.
37. Valenti, P. and R. El-Abiad. "Repair of Rotator Cuff Tears in Patients Older than 65 Years: Report of 46 Cases." Presented at the 8th ICSS. Cape Town, April 2001.
38. Valenti, P. and A. Sbihi. "Inverted Delta III Prosthesis in Non Reconstructable Rotator Cuff Lésions: Report of 25 Cases." Presented at the 8th ICSS. Cape Town, April, 2001.
39. Valenti, P., P. Sauzières, D. Bouttens and C. Nérot. "Résultats de 19 Prothèses Inversées 'Grammont' Implantées Après Échec d'Hémarthoplasties ou d'Arthroplastie Totale de l'Épaule." Communication Présentée à la 76<sup>ème</sup> Réunion Annuelle de la SOFCOT. November, 2001.
40. Woodruff, M.J., A.P. Cohen and J.G. Bradley. "Arthroplasty of the Shoulder in Rheumatoid Arthritis with Rotator Cuff Dysfunction." *International Orthopaedics* 27, 2003: 7-10.



**IMPORTANT**

This essential product information does not include all of the information necessary for selection and use of a device. Please see full labeling for all necessary information.

**INDICATIONS**

Delta shoulder replacement is indicated for use in grossly rotator cuff deficient joints with severe arthropathy, or for use when a previous joint replacement has failed with a grossly rotator cuff deficient joint. A functional deltoid muscle is needed for use of this device. Also, the patient's joint must be anatomically and structurally suited to receive the device.

The metaglens component is for cementless use only. All other components are intended for cemented use only.

**CONTRAINDICATIONS**

The following are contraindications for shoulder arthroplasty:

1. Active local or systemic infection;
2. Poor bone quality and/or inadequate bone stock to appropriately support the prosthesis;
3. Severe deformity;
4. Muscle, nerve or vascular disease;
5. Obesity, drug abuse, over activity or mental incapacity.

**WARNINGS AND PRECAUTIONS**

The following conditions tend to adversely affect the fixation of the shoulder replacement implants:

1. Marked osteoporosis or poor bone stock;
2. Metabolic disorders or systemic pharmacological treatments leading to progressive deterioration of solid bone support for the implant (e.g., diabetes mellitus, steroid therapies, immunosuppressive therapies, etc.);
3. History of general or local infections;
4. Severe deformities leading to impaired fixation or improper positioning of the implant;
5. Tumors of the supporting bone structures;
6. Allergic reactions to implant materials (e.g. bone cement, metal, polyethylene);
7. Tissue reactions to implant corrosion or implant wear debris;
8. Disabilities of other joints.

**ADVERSE EVENTS**

The following are the most frequent adverse events encountered after total or hemi-shoulder arthroplasty:

1. Change in position of the prosthesis, often related to factors listed in WARNINGS AND PRECAUTIONS.
2. Early or late infection;
3. Early or late loosening of the prosthetic component(s), often related to factors listed in WARNING AND PRECAUTIONS;
4. Temporary inferior subluxation. Condition generally disappears as muscle tone is regained;
5. Cardiovascular disorders including venous thrombosis, pulmonary embolism and myocardial infarction;
6. Hematoma and/or delayed wound healing;
7. Pneumonia and/or atelectasis;
8. Subluxation or dislocation of the replaced joint.

For more information about DePuy products, visit our web site at [www.jnjgateway.com](http://www.jnjgateway.com).

**DePuy Orthopaedics, Inc.**

700 Orthopaedic Drive  
Warsaw, IN 46581-0988  
USA  
Tel: +1 (800) 366 8143  
Fax: +1 (574) 267 7196

**DePuy International Ltd**

St Anthony's Road  
Leeds LS11 8DT  
England  
Tel: +44 (113) 387 7800  
Fax: +44 (113) 387 7890