



Foundation<sup>®</sup>  
Shoulder Fracture  
System

DJO Surgical  
9800 Metric Blvd.  
Austin, Texas 78758  
512-832-9500  
[www.djosurgical.com](http://www.djosurgical.com)

© 2009  
Cat. # 0030305-001 rev. B June 2009

Foundation is a registered trademark of  
DJO Surgical or its affiliates.

CAUTION: Federal Law (USA) restricts  
this device to sale by or on the order  
of a physician.

See package insert for a complete listing  
of indications, contraindications, warnings,  
and precautions.



# Foundation® Shoulder Fracture System

## Design Surgeon

Mark A. Frankle, MD

Associate Clinical Professor  
University of South Florida  
Tampa, FL

Chief of Orthopedics  
Department of Orthopedic Surgery  
University Community Hospital  
Tampa, FL

Chief of Shoulder & Elbow Surgery  
Florida Orthopaedic Institute  
Tampa, FL

**DJO Surgical**  
**9800 Metric Boulevard**  
**Austin, TX 78758**  
**(800) 456-8696**  
**[www.djosurgical.com](http://www.djosurgical.com)**

## Table of Contents

<b>Design Rationale</b>	<b>2</b>
<b>Indications/Contraindications</b>	<b>2</b>
<b>Templating the Humeral and Glenoid</b>	<b>3</b>
<b>Patient Positioning</b>	<b>3</b>
DeltoPectoral Surgical Approach	4
Humeral Exposure	4
Humeral Head Osteotomy	5
Humeral Canal Reaming	6
Modular Trial System	6
Establishing Height of Humeral Prosthesis	7
Establishing Version of Humeral Prosthesis	8
Humeral Implantation	9
Humeral Stem Cementation	9
Humeral Head Insertion	10
Reconstruction of Proximal Humerus	11
<b>Final Reduction and Closure</b>	<b>12</b>
<b>Rehabilitation</b>	<b>12</b>

This brochure is presented to demonstrate a surgical technique. DJO Surgical, as the manufacturer of this device, does not practice medicine and cannot recommend this or any other surgical technique for use on a specific patient. The choice of the appropriate surgical technique is the responsibility of the surgeon performing the operation.

# Surgical Technique

## Foundation<sup>®</sup> Shoulder Fracture System

### Design Rationale

Establishing proper head height in relation to the glenoid is critical to the outcome of arthroplasty for fractures of the proximal humerus. A prosthesis placed too high or too low will cause excessive forces on the glenoid and rotator cuff. The challenge has been how to determine the proper height when the final implant is cemented. The Foundation Shoulder Fracture system provides an easy answer for this challenge.

The Encore Foundation Shoulder Fracture System has been specifically designed for the treatment of fractures of the shoulder requiring arthroplasty, most commonly four-part proximal humerus fractures. The system has been designed with biomechanical principals to aid in optimal shoulder reconstruction for these fractures.

The Foundation Shoulder Fracture system's modular trials establish a stable trial reduction without the use of an external jig simultaneously determining the canal size, stem height, and stem version all in one simple step.

The features of this system includes:

- 1) Modular trials to establish a stable trial reduction while determining canal size, stem height, and stem version all in one step.
- 2) Prosthesis holes for suture attachment which are available anterior, posterior, medial and lateral.
- 3) An anterior fin which allows for anatomical reconstruction of the tuberosities.

### Indications

This total shoulder prosthesis is intended for treatment of patients who are candidates for total shoulder arthroplasty because the natural humeral head and/or glenoid has been affected by osteoarthritis, inflammatory arthritis, traumatic arthritis, rheumatoid arthritis, avascular necrosis or proximal humeral fracture, and revision arthroplasty where bone loss is minimal. This system includes a humeral stem and head and is to be used with bone cement. These devices are intended to aid the surgeon in relieving the patient of shoulder pain and restoring shoulder motion.

## Templating the Humerus and Glenoid

AP, Lateral and Axillary views of the shoulder are necessary to be able to identify the proper fracture pattern and dislocation of the humeral head relative to the glenoid. Measurements with a radiographic ruler of the fractured shoulder and the unaffected side will aid in restoration of proper prosthetic height at the time of surgery.

## Patient Positioning

The patient is positioned semi-sitting with a customized special shoulder positioning device or a neurosurgical head rest. The patient should be positioned so that the adducted arm at the side can be fully extended without hitting the table. The entire extremity is prepared free, making ample space for the proximal portion of the upper thorax up to the neck and to the lateral aspect of the clavicle (Figure 1).

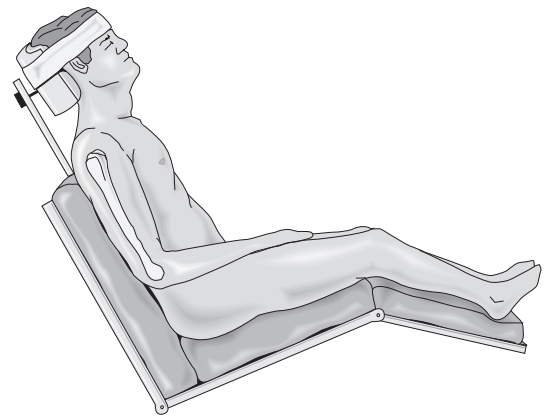


Figure 1

# Humeral Preparation

## Foundation® Shoulder Fracture System

### DeltoPectoral Surgical Approach

#### Humeral Exposure

A typical skin incision goes from the mid portion of the clavicle down to the anterior aspect of the humerus and measures about 10 cm (Figure 2). The cephalic vein is left with the intact pectoralis major and typically one-half to two-thirds of pectoralis is released off the shaft for further exposure of the distal segment (Figures 3a,b,c).

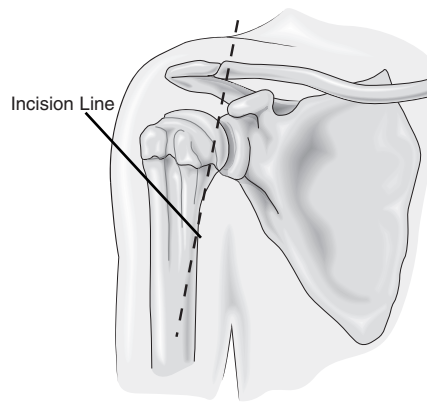


Figure 2

At this point, the subdeltoid, subcoracoid and subacromial spaces are bluntly developed. A deltoid retractor is placed, and the long head of the biceps tendon is then identified distally on the shaft where the pectoralis major tendon was released. This is followed all the way through the interval between the subscapularis and supraspinatus which is split all the way to the coracoid.

The lesser tuberosity fragment is identified, split and osteotomized at the biceps groove (Figure 4a,b).

The lesser tuberosity is then tacked with two #5 nonabsorbable sutures at the bone-tendon junction (Figure 5).




Figure 3a

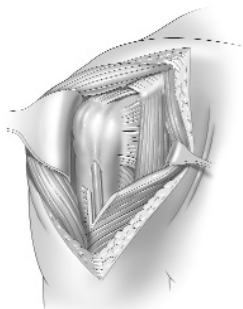


Figure 3b

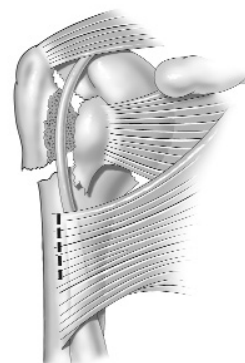


Figure 3c

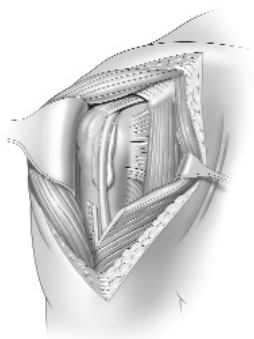


Figure 4a

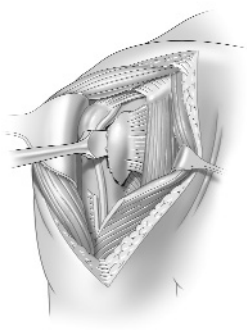


Figure 4b

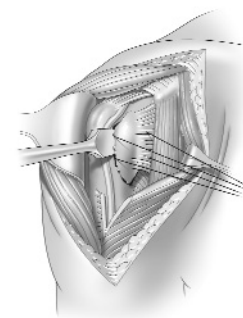


Figure 5

## Humeral Head Osteotomy

The articular head segment is removed from the glenoid vault (Figure 6). Often times, there may be a small portion of inferior capsule which needs to be resected prior to removing the head.

Measuring the resected humeral head segment will help determine the proper size and diameter of the humeral head prosthesis and can also be used for bone graft.

The greater tuberosity fragment is then mobilized by placing two #5 nonabsorbable sutures at the bone tendon junction. These are evenly spaced to allow even traction of this fragment (Figure 7).

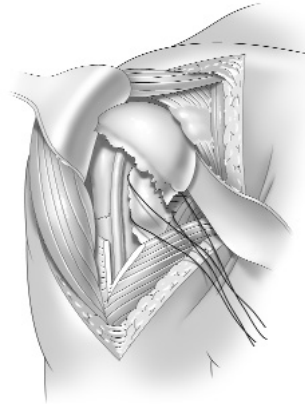


Figure 6

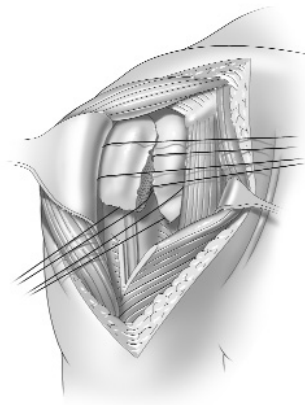


Figure 7

# Surgical Technique

## Foundation<sup>®</sup> Shoulder Fracture System

The glenoid vault is inspected, and a glenoid sizer is used to verify the radius of curvature and to allow for the appropriate mismatch between the glenoid and the humeral head (Figure 8).

Any loose fragments within the joint should be extracted at this point.

The shaft is then presented by extending the elbow and adducting the arm to the side. Two Hohmann retractors can be placed subperiosteally around the segment to help present the segment in clear view for the surgeon (Figure 9).

### Humeral Canal Reaming

The humeral shaft is gently hand reamed to determine the canal size. Care should be taken, as often times the bone can be very porotic.

### Modular Trial System

The modular trial is then assembled (Figure 10). The distal stem should match the canal size. The proximal body selected does not need to correlate with the distal stem size. The only requirement of the proximal body size is that it does not impinge on the shaft segment preventing seating to the proper height.

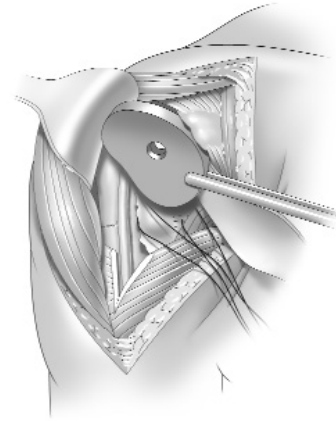


Figure 8

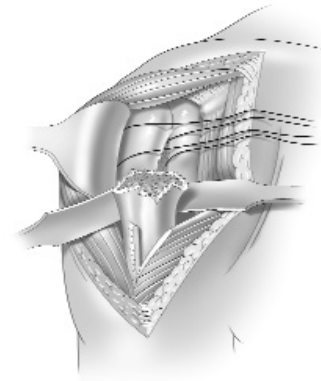


Figure 9

---

### Instrumentation

Glenoid Sizers

[804-01-062/066]

6mm Starter Reamer (Canal Finder)

[804-00-002]

Detachable Reamer T-Handle

[803-00-047]

Humeral Reamers

[804-00-029/039]

Proximal Fracture Trials

[804-00-141/146]

Distal Fracture Trials

[804-00-064/073]

Humeral Stem Wrench

[804-00-075]



Figure 10



## Establishing Height of Humeral Prosthesis

Proper height placement of the humeral prosthesis is crucial to the outcome of fracture fixation. A prosthesis placed too low will cause increased tension of the rotator cuff resulting in eccentric glenoid wear (Figure 11). The other extreme, a prosthesis placed too high, will cause excessive joint reactive forces and excessive glenoid and cuff wear (Figure 12).

The proper height can be selected by two methods. One method is to use preoperative templating with the radiographic rulers placed on the patient's affected side. For example, if the fractured humerus measured 46.5 cm from the most proximal portion of the fracture of the distal humerus and the intact humerus measured 50 cm from the top of the greater tuberosity, then the trial would need to be 3.5 cm proud on the lateral side of the fracture to reconstitute proper height.

A second method would be using the height guides simply as a trial to reproduce the proper height. In this fashion, with the arm in neutral position without any traction, the lower portion of the trial collar should be at the lower portion of the glenoid. With the arm in neutral, this should face the glenoid (Figure 13). Notice that the anterior fin of the trial falls over the biceps groove on the distal segment.

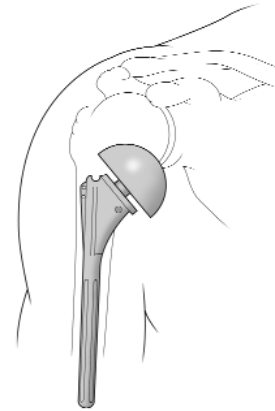


Figure 11

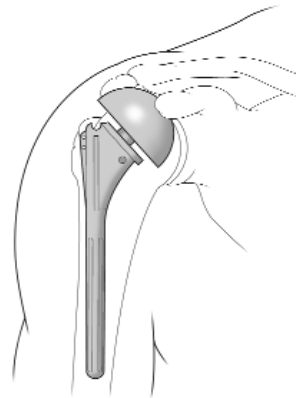


Figure 12

---

### Instrumentation

FS X-ray Templates  
[available upon request]

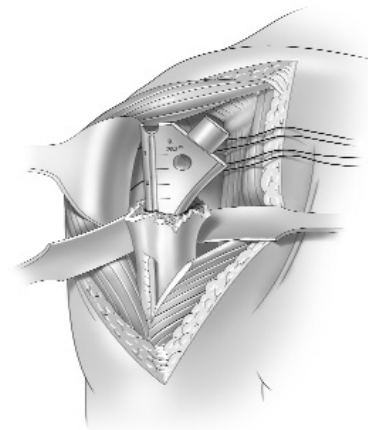


Figure 13

# Surgical Technique

## Foundation<sup>®</sup> Shoulder Fracture System

### Establishing Version of Humeral Prosthesis

At this point, the version can be checked by placing the alignment rod into the trial and aligning with the axis of the forearm giving a fixed 30° retroversion angle (Figure 14 ).

The appropriate head trial is selected, and the trial reduction can be easily performed because of the stability provided by the modular stem trials. The tuberosities are pulled in a temporary position of repair to check that:

- a) humeral head faces the glenoid with the arm in neutral,
- b) tuberosities easily stretch around the prosthesis to the anterior fin,
- c) the position of the trial is relative to the glenoid in terms of its height, and
- d) full passive motion of the shoulder can be performed with the trial in place and the tuberosities temporarily reduced (Figure 15).

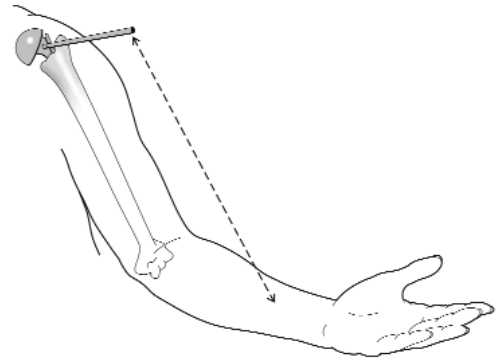


Figure 14

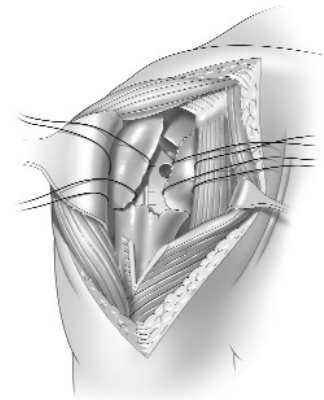


Figure 15

---

### Instrumentation

FS Head Trials  
[804-00-100/114]

Offset Head Trial  
[804-00-116/129]

Alignment Rod  
[803-01-057]

## Humeral Implantation

Adequate height and version are reconfirmed prior to removal of the trial components. Two shaft suture holes are drilled about 1 cm inferior from the fracture site on either side of the biceps groove. Place a #5 nonabsorbable suture outside-in and then inside-out so that both of the sutures exit through the distal segment. This will allow a tension band fixation of the distal segment to the tuberosity fragment (Figure 16).

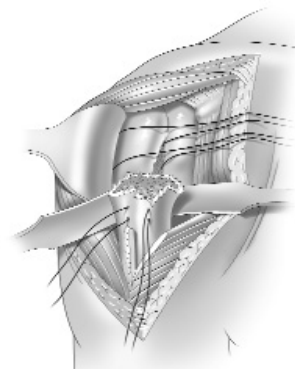


Figure 16

## Humeral Stem Cementation

In cement preparation, a Bio-Absorbable plug is placed 1.5 cm distal to the stem. To lessen the risk of cement extravasation through undetected fracture sites in the distal shaft, do not make an effort for severe impaction of the cement.

A 3mm Cottony Dacron suture is placed through the medial hole of the prosthesis prior to insertion. With the version rod threaded into the implant impactor handle, the version can be verified while the final implant is seated.

**The prosthesis corresponding to the trial body segment is implanted to the appropriate height as determined in trial reduction** (Figure 17a,b).

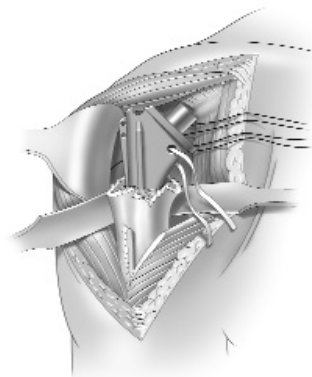


Figure 17a

---

## Instrumentation

Stem/Broach Handle  
[804-00-140]

Alignment Rod  
[803-01-057]

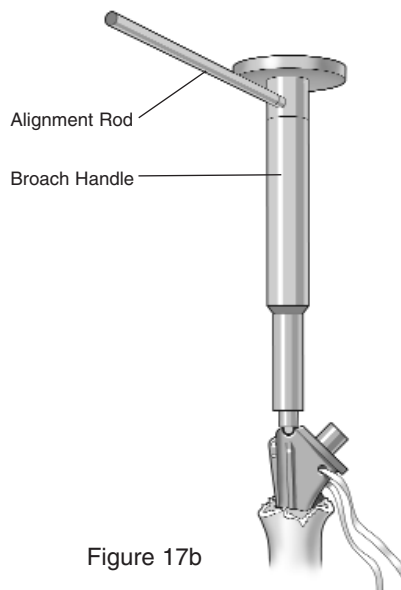


Figure 17b

# Surgical Technique

## Foundation<sup>®</sup> Shoulder Fracture System

### Humeral Head Insertion

After the prosthesis has been cemented in its proper version and height, a trial is selected for optimal head height. Again, this is best determined primarily by the deltoid tension.

The arm should be brought to a full range of motion with the tuberosity temporarily reduced. Full range of motion must be achieved at this point. With the arm in neutral, proper head height should allow about 50% translation anteriorly and posteriorly and 25% displacement inferiorly in relation to the glenoid.

The shoulder is then gently dislocated again and the selected head is then placed after careful cleaning of the reverse Morse taper (Figure 18).




Figure 18

---

### Instrumentation

Head Impactor  
[800-01-018/804-00-010]

Head Trials  
[804-00-100/114]

Offset Head Trials  
[804-00-116/129]

Humeral Fracture Gauge  
[804-00-135]

## Reconstruction of Proximal Humerus

Bone graft is packed between the shaft and the prostheses so that no bone cement is visible. This allows for good bony contact of the tuberosities.

At this point, the shoulder is reduced and reconstruction of the tuberosity is performed. This is begun initially by pulling the tuberosity fragments around so that they meet at the biceps groove. The 3mm Cottony Dacron should be passed through the tendon bone junction of the greater and lesser tuberosities between the previous placed traction sutures (Figure 19a).

The previous traction sutures which were placed in the greater tuberosity are then utilized and pulled through the anterior fin holes of the prosthesis (Figure 19b) and then placed through the subscapularis at the junction of the tendon and the lesser tuberosity fragment (Figure 219c). This horizontal fixation is done at least twice through both holes of the anterior fin.

Bone graft is then taken from the resected humeral head and placed on the outside of the shaft of the tuberosity fragments.

The 3mm Cottony Dacron suture, which was placed through both the greater and lesser tuberosities and the medial hole of the prosthesis, is then used to pull the tuberosities into the irregular metaphyseal portion of the prosthesis improving fracture stability (Figure 19d).

With the arm slightly abducted to take tension off the shoulder, the previously placed sutures in the shaft are placed in a figure-of-eight fashion going between the tendon of the supraspinatus at the tendon- bone junction (Figure 20). Avoid over reduction of the greater tuberosity to the shaft.

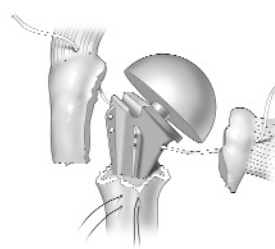


Figure 19a

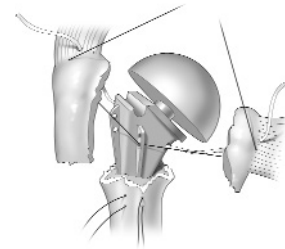


Figure 19b

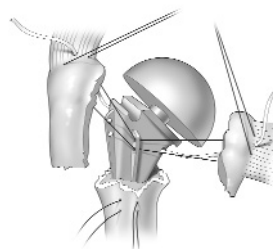


Figure 19c

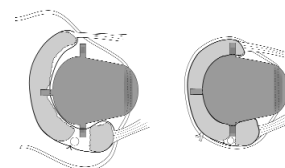


Figure 19d

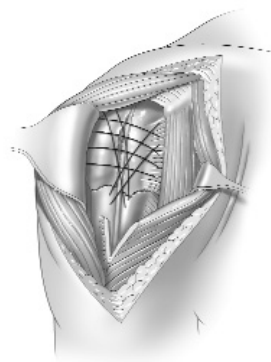


Figure 20

# Closure

## Foundation<sup>®</sup> Shoulder Fracture System

### Final Reduction and Closure

At this point, the interval is closed between the subscapularis and supraspinatus, and the shoulder is examined.

The shoulder should be able to be brought through a full range of motion and there should be no motion between either the tuberosities and the shaft, or the tuberosities and each other. If motion exists, then additional suture fixation between the tuberosities and each other should be incorporated, or likewise through the shaft, although this is rarely necessary.

Finally, the axillary nerve is checked both under the subscapularis and the deltoid to make sure it passes through the axilla freely. The deltopectoral interval is then closed and subcutaneous tissue is closed in layers. The patient should then have subcuticular suturing of his skin and placed in a shoulder immobilizer (Figure 21).

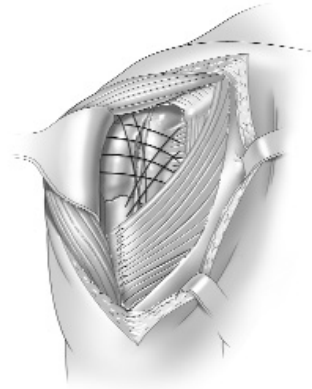


Figure 21

### Rehabilitation

Rehabilitation begins with passive motion the day of surgery or the following day, generally from 20° of external rotation at the side to 120° of elevation in the scapular plane.

The patient is kept in a shoulder immobilizer for three weeks with this passive motion protocol. Elbow and hand motion begin right away to avoid stiffness. During the second three weeks, the patient goes into a sling and active assisted range of motion begins, increasing the motion using pulleys and canes to achieve 40° of external rotation and 140° of elevation.

At six weeks, gentle thera-band strengthening can generally begin with avoidance of elevation of the arm and continued to nine weeks.

Once tuberosity fixation is shown to be secured, overhead strengthening can then begin at three months.

Follow-up occurs at 10 days, three weeks, six weeks and three months. Radiographs are obtained at each time to ensure stable fixation of the tuberosities to make sure they have not displaced.

## Glenoid

Glenoid Size	Trial Color
38mm	Dark Orange
42mm	Green
46mm	Blue
50mm	Grey
54mm	Black

## Humeral Head

Head Size	Height	Trial Color
38mm	17, 22, 27	Dark Orange
42mm	17, 22, 27	Green
46mm	17, 22, 27	Blue
50mm	17, 22, 27	Grey
54mm	17, 22, 27	Black

## Offset Humeral Head

Head Size	Height	Trial Color
38mm	22, 27	Dark Orange
42mm	22, 27	Green
46mm	22, 27	Blue
50mm	22, 27	Grey
54mm	22, 27	Black

## Humeral Stem

Stem Size	Stem Length	Neck Angle
6mm	103mm	45°
8mm	109mm	45°
10mm	118mm	45°
12mm	125mm	45°
14mm	134mm	45°
16mm	143mm	45°