

Comprehensive[™]
FRACTURE STEM



BIOMET
ORTHOPEDICS, INC.



Approximately 60% of all shoulder replacements are the result of a proximal humeral fracture.¹ The surgeon is challenged to restore proper biomechanics, achieve adequate ROM and provide pain relief for the patient. The Comprehensive™ fracture stem was designed with these challenges in mind and to help the surgeon achieve the ultimate goal...patient satisfaction.

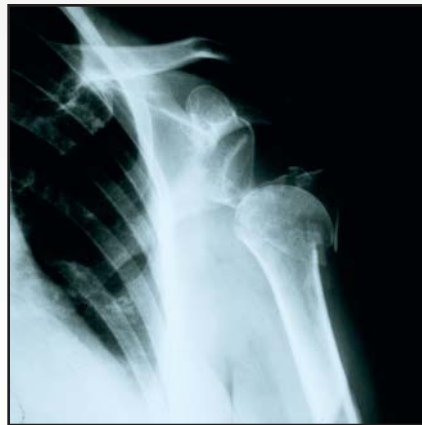

1. David Dines, M.D., Orthopedic Surgeon, Long Island Jewish Hospital/Hospital for Special Surgery, personal interview, June 11, 2003.

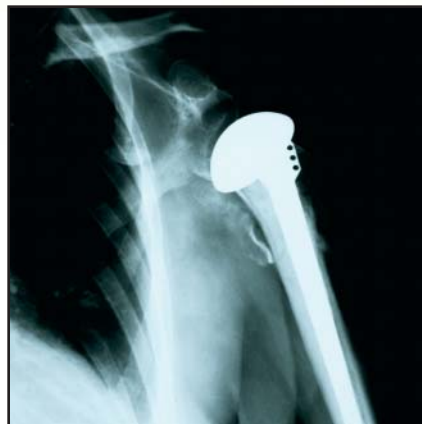- Compact proximal body for improved tuberosity reconstruction.
- Two lateral fins and one medial fin for superior tuberosity fixation.
- Suture holes processed with Biomet's unique "Engineered Contour" which provides a statistically significant reduction in suture wear.*
- Hashmarks on stems and trials to aid in recreating the precise humeral length.
- Proximal MacroBond[®] coating for enhanced fixation.

Case History

Patient is a 50+ year-old female who sustained a four part fracture of her proximal humerus. She underwent hemiarthroplasty with tuberosity reconstruction using the Comprehensive[™] fracture stem. At three months the tuberosities were completely healed. At four months she had regained 120° of full abduction and 75° of external rotation with power. At six months she had 130° of forward elevation and 75° of external rotation with good power. She is delighted with her result.



Preoperative



Postoperative

* Data on file at Biomet.

All trademarks are property of Biomet, Inc.

This brochure is presented to demonstrate the surgical technique utilized by David Dines, M.D.; Russell Warren, M.D.; and Edward Craig, M.D. Biomet, as a manufacturer of this device, does not practice medicine and does not recommend this device or technique. Each surgeon is responsible for determining the appropriate device and technique to utilize on each individual patient.

Stem Options

Cobalt Chrome
Proximal MacroBond® Coating
Diameters: 4, 6, 8, 10, 12, 14mm
Length: 140mm



Head Options

Standard Head

Diameters: 40, 44, 48, 54mm
Head Heights: 15, 17, 19, 20, 22, 24, 27mm

Offset Head

Diameters: 44, 48, 54mm
Head Heights: 17, 19, 22, 24, 27mm

Extended Articular Surface (EAS) Head

Diameters: 40, 44, 48, 54mm
Head Heights: 15, 17, 19, 20, 22, 24, 27mm

Patient Positioning

Place the patient in a modified beach chair position at 30° after general or regional anesthetic has been induced and a prophylactic dose of a broad-spectrum antibiotic has been administered. Lateralize the patient on the edge of the table so that the arm can be extended off the side (**figure 1**).

Approach

Mark the skin incision for an extended deltopectoral approach (**figure 2**). Begin the incision over the clavicle, directly superior to the coracoid process, and pass over the coracoid, sweeping laterally and distally to end at the insertion of the deltoid onto the humerus (**figure 3**). This approach allows for detachment of part of the distal deltoid insertion if further mobilization of the deltoid is required.

As dissection proceeds identify the cephalic vein, a landmark of the deltopectoral interval. This vein is usually identified by its surrounding fatty tissue (**figure 4**).

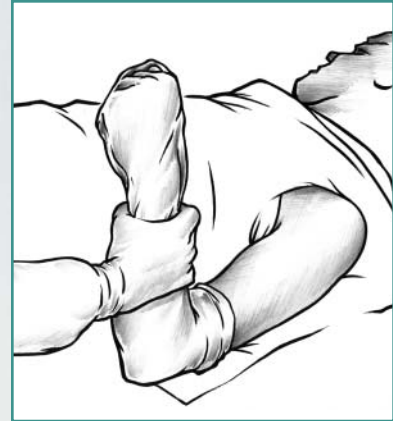

figure 1

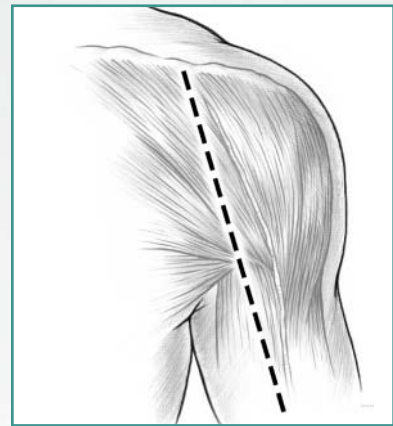


figure 2

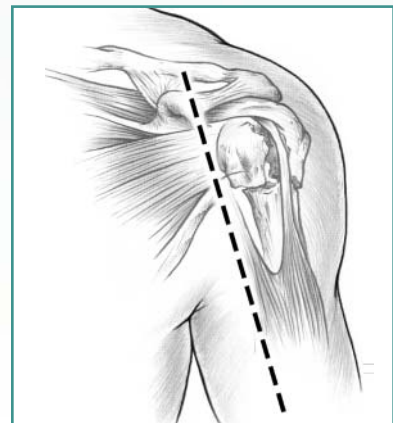


figure 3

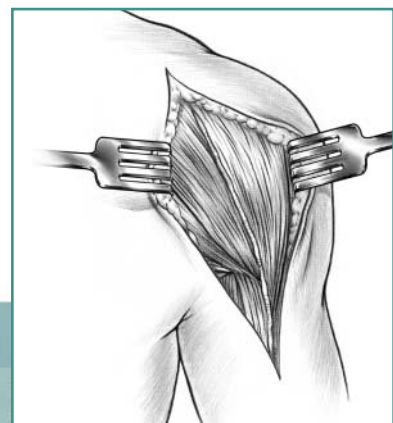


figure 4

Dissection of Soft Tissue

The cephalic vein is usually firmly embedded in the deltoid, with many feeders from the deltoid to the cephalic vein. The vein may either be sacrificed or reflected. The distal deltoid may be partially released from its humeral insertion, but the proximal origin should not be violated. In fracture cases, it is especially important to identify and protect the musculocutaneous and axillary nerves. Palpate the musculocutaneous nerve as it comes from the plexus into the posteromedial aspect of the conjoined tendon (**figure 5**). With further dissection the medial branches of the cephalic vein that cross the incision are identified, divided, and cauterized. Next, divide the clavipectoral fascia and retract the conjoined tendon, avoiding traction on the musculocutaneous nerve, which lies distal to the coracoid process (**figure 6**). The nerve usually penetrates the muscle one to two inches inferior to the tip of the coracoid process, but in some instances the nerve has a higher penetration into the conjoined muscle tendon unit. It is important to remember the location of this nerve when retracting the conjoined tendon. A partial tenotomy may be considered to reduce the tension on the nerve during exposure.

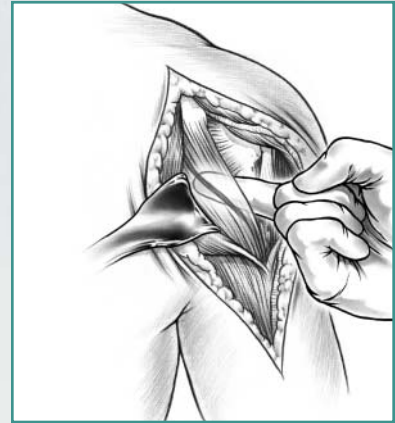


figure 5

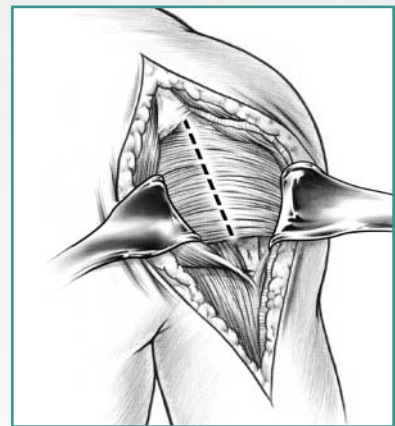


figure 6

Identifying the Lesser and Greater Tuberosity Fragments Using the Biceps Tendon

The biceps tendon and bicipital groove afford the most useful anatomic landmark for identification of the fractured tuberosity fragments. Place a pair of scissors into the sheath of the biceps tendon and use them to divide the transverse ligament (**figure 7**). Continuing proximally with the scissors, open the interval between the subscapularis and the supraspinatus tendons all the way up to the insertion of the biceps tendon into the supraglenoid tubercle. Even if the biceps tendon is ruptured, place the scissors into the bicipital groove and use them to open the interval between the subscapularis and the supraspinatus tendon. Free up the lesser tuberosity from the underlying humeral head and soft tissue (**figure 8**). The fracture may need to be completed with an osteotome or elevator. Protect the axillary nerve during mobilization of both the lesser and greater tuberosities and the attached rotator cuff muscle tendon unit. Once the tuberosities have been identified, place three nonabsorbable #5 sutures through the attached tendon. The greater and lesser tuberosity fragments must be sufficiently freed, so they can be easily repaired around the prosthesis and to each other at the time of closure (**figure 9**). By retracting the greater and lesser tuberosities access is provided to the shoulder joint and both the humeral head and glenoid are better visualized.

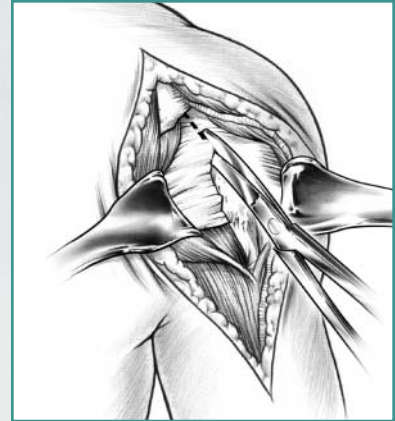


figure 7

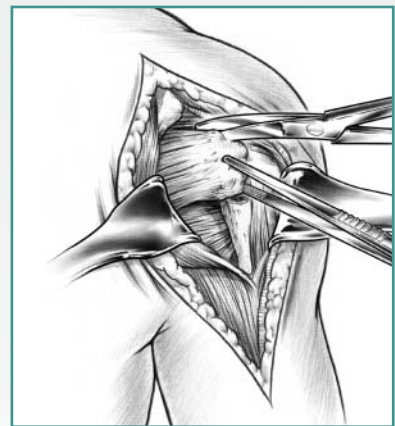


figure 8

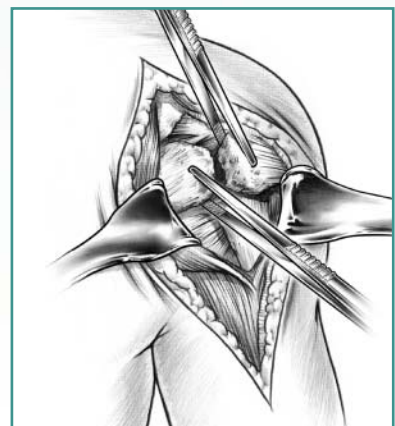


figure 9

Humeral Head Retrieval

Identify and remove the articular segment of the humeral head using the tuberosity clamps. Size the head with calipers or by direct comparison to the modular head trials (**figure 10**). Assess the proximal humerus for shortening due to proximal metaphyseal comminution. This must be considered in placement of the prosthesis if comminution is present. Evaluate the glenoid surface. If it is damaged significantly, or if chronic cartilage loss is present, glenoid replacement may be performed.

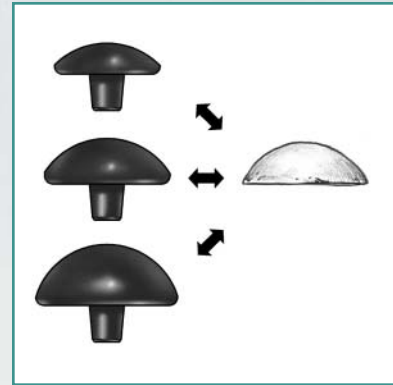


figure 10

Shaft Preparation of the Humerus

Humeral shaft preparation is facilitated by extension, adduction and external rotation of the humerus. Using the 4mm reamer, sequentially ream in one-millimeter increments until good cortical contact has been achieved, allowing the shaft to accept the correct size stem in approximately 30–35° of retroversion (**figure 11**). If a chronic fixed posterior dislocation with associated humeral head fracture of greater than 50% is being treated, less retroversion will be necessary. Often the medial calcar has been comminuted, leaving only a diaphyseal portion of the humerus intact. This bone loss must be recognized so that the prosthesis can be placed in the appropriate anatomic position to recreate appropriate humeral length.

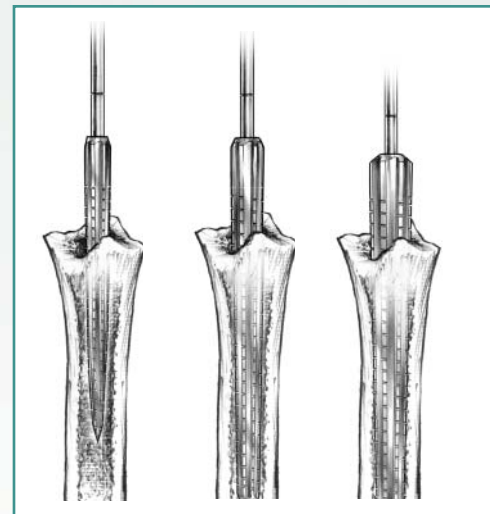


figure 11

Humeral Stem Insertion

Select the trial stem that corresponds to the size of the final reamer used in canal preparation. Attach the trial prosthesis to the inserter and insert to check for correct sizing, version, and humeral length (**figure 12**).

The version rod may be attached to the inserter and aligned parallel to the long axis of the forearm. This will place the trial in the desired amount of retroversion. With the forearm at neutral, or zero degrees rotation, the head should point at the glenoid (**figure 13**).

Select the humeral head trial that most closely replicates the original articular segment. Determine humeral length intraoperatively by attempting to sublux the humerus inferiorly (**figure 14**). Normally, the humeral component should travel only 25% to 50% of the length of the glenoid with inferior traction. If more than that is possible the prosthesis is seated too low. In this case the deltoid function will be poor due to inadequate length and tension. If there is no inferior play, the humerus is too high and should be sunk deeper into the shaft or it will be prone to impingement and place undue stress on the glenoid. Another means of establishing proper tension is to utilize the biceps tendon, the only intact tendon unit. Proper implant tension is achieved when the biceps tendon travels over the top of the implant between the tuberosities and is neither lax nor overly taut.

The proper humeral length can also be assessed preoperatively by using a scanogram or full-length radiograph of the contralateral humerus in difficult cases.

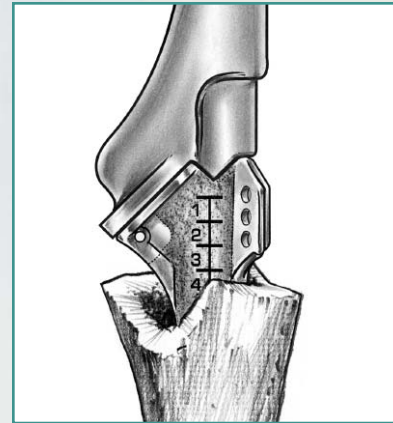


figure 12

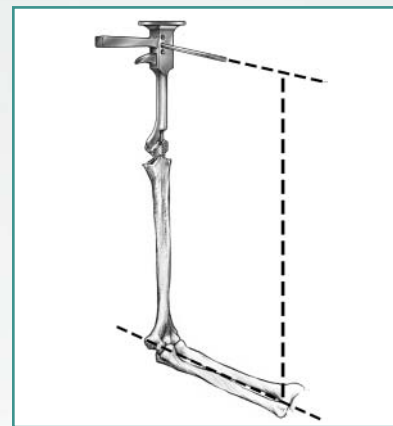


figure 13

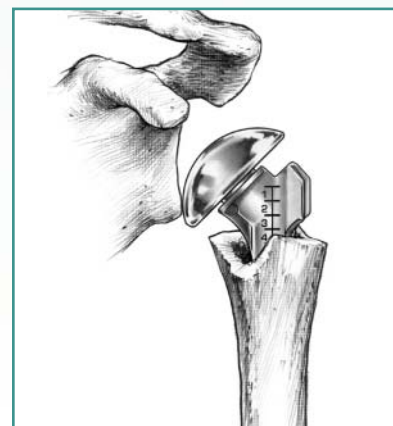


figure 14

The hashmarks on the trial and stem are in two and a half millimeter increments. When the humerus is properly tensioned, note the appropriate hashmark at some fixed and reproducible landmark in the proximal humeral metaphysis. The final implant is then placed with the landmark at the identical hashmark to precisely reproduce the appropriate tension (**figure 15**). The anterolateral fin is immediately lateral to the bicipital groove. Therefore, the lateral edge of the bicipital groove may be directly lined up with the leading fin.

Before cementing the appropriate stem, drill two holes in the humeral shaft, medial and lateral to the bicipital groove. Pass one #5 nonabsorbable suture front to back through these holes to be used later as a figure-of-eight tension band. Pass a second #5 nonabsorbable suture through the lateral hole for longitudinal fixation of the greater tuberosity (**figure 16**). After final check of the stem fit with the trial implant, prepare and dry the canal. Cement the stem in the appropriate amount of retroversion (30–35°). There will be less retroversion in cases of fixed posterior dislocation.

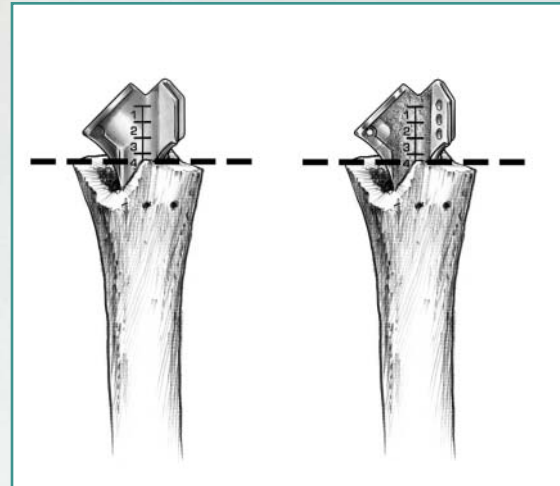


figure 15

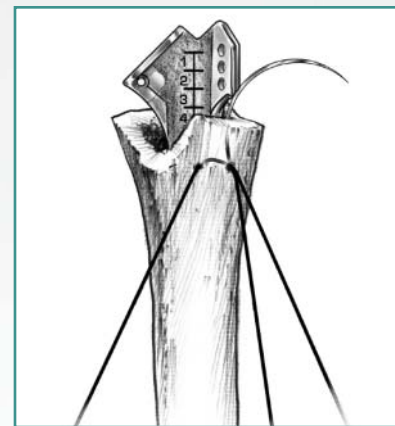


figure 16

Cementing the Humeral Component

When using the Comprehensive™ fracture stem and cement, it is recommended to use an implant that is two millimeters smaller than the last reamer utilized. For example, if the humeral shaft is reamed to ten millimeters then an eight-millimeter stem is cemented. The humeral shaft need not be pressurized during cement insertion with a distal plugging device. Humeral shaft bone stock may be extremely thin and pressurization can result in either fractures of the proximal shaft during cementing or cement extruding from the humeral shaft and endangering the radial nerve.

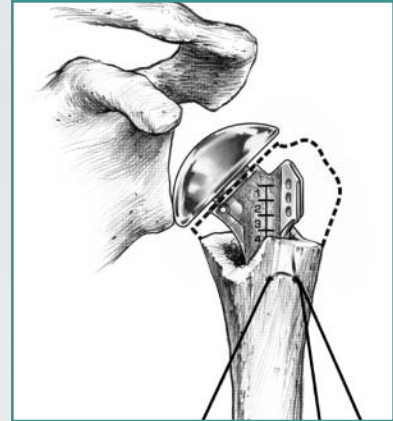


figure 17

Trialing the Humeral Head

Once the stem has been cemented, place the selected head trial on the stem and reduce the joint. With tension maintained in the tuberosities, assess anterior stability, posterior stability and range of motion. Attempt to recreate a 50% translation relative to the glenoid, anteriorly, posteriorly, and inferiorly (**figure 17**). In addition, a full range of forward flexion and abduction should be possible without tuberosity impingement. Continue to trial until all of the criteria are fulfilled. Remove the trial and adequately clean and dry the reverse morse taper with the enclosed swab. Impact the humeral head implant.

Tuberosity Reattachment

This is the most critical part of the procedure.

There are many variations acceptable. However, the goal is to securely fix the greater and lesser tuberosities to the shaft and to each other. The following technique is recommended by the authors. The tuberosity clamps can be used to secure tuberosities during reconstruction.

Place three #5 nonabsorbable sutures through the bone tendon interface of the greater tuberosity. Place the middle greater tuberosity suture through the suture hole on the medial neck of the prosthesis (**figure 18**). Next, place the superior and inferior greater tuberosity sutures through the superior and inferior holes in the prosthesis fin. Continue with these sutures through the lesser tuberosity at corresponding levels (**figure 19**). Next, pass the longitudinal suture, previously placed through the lateral hole in the humeral shaft, inside out through the superior portion of the supraspinatus tendon above the greater tuberosity. Continue with this suture underneath the greater tuberosity sutures (**figure 20**).

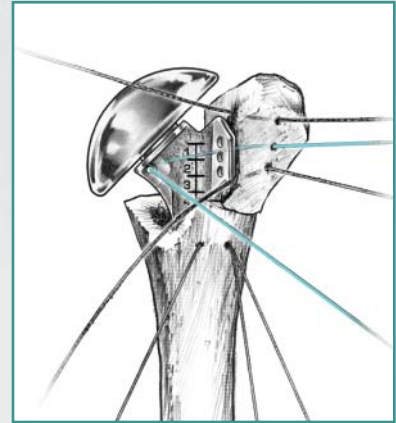


figure 18

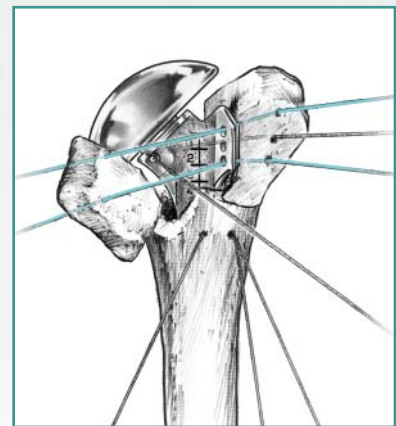


figure 19

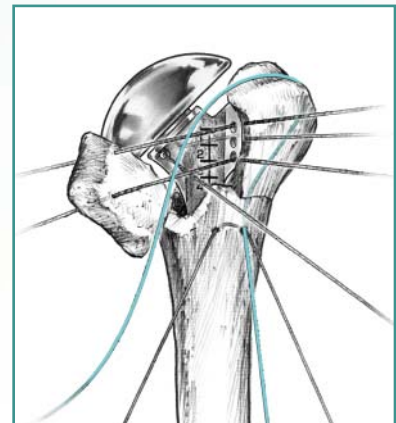


figure 20

Tie these sutures in the appropriate order to first secure the greater tuberosity to the humeral shaft and to the prosthesis (**figure 21**) and then to secure the lesser tuberosity to the humeral shaft and to the greater tuberosity (**figure 22**).

Place the “figure of 8” suture that was placed prior to stem insertion from back to front through the rotator cuff and close above the tuberosities, fixing the tuberosities to the humeral shaft (**figure 23**). Insert bone graft from the humeral head below the tuberosities for improved healing.

The tuberosities should be positioned a few millimeters below the top of the humeral head component. Improper positioning will cause abnormal tensioning on the rotator cuff system and could lead to impingement.

Place the shoulder through a range of motion noting stability of the tuberosities. This will allow guidance for the postoperative rehabilitation program.

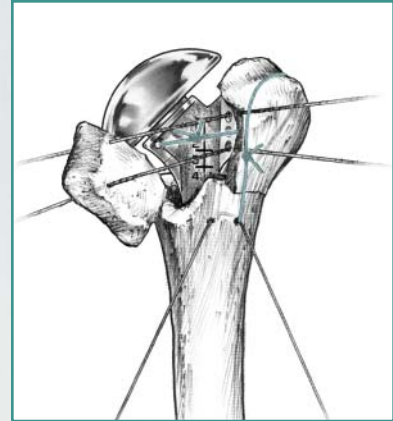


figure 21

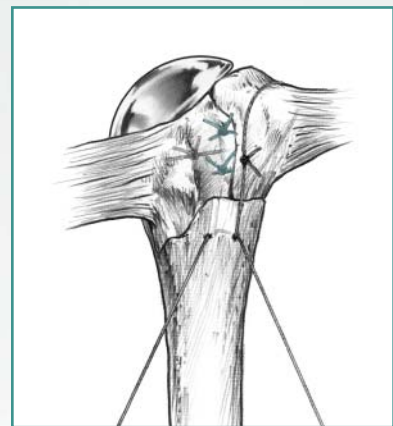


figure 22

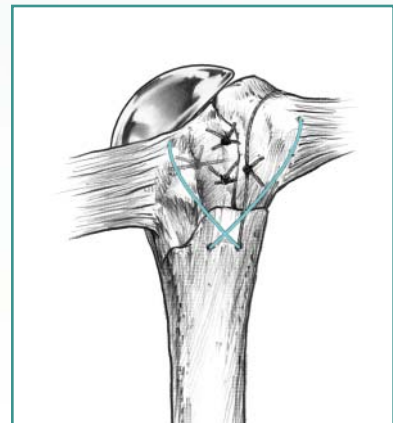


figure 23

Closing

Close the wounds over a suction drain system. Place the arm in a sling and swathe. Institute physical therapy on the first postoperative day.

Rehabilitation

The initial phase is aimed at achieving full, passive ROM. The precise exercises, safe ranges of motion, and the timing of initiation and progression of exercises should be individualized. This is typically based on intraoperative testing of tension on the tuberosities, tuberosity repair and security of tuberosity fixation.

Initial phases of rehabilitation may include therapist assisted passive flexion. The patient may also perform passive flexion of the arm using the other arm as the power source or by use of a pulley and rope system. Each passive exercise should include five repetitions and be performed four to six times per day. The patient should perform pendulum exercises four to six times per day when out of bed. External rotation stretching exercises using a three-foot stick may also be utilized.

If, after several weeks of rehabilitation, the patient does not have sufficient passive motion, additional stretching exercises may be instituted, such as wall climbing, additional overhead stretching with a pulley, posterior capsule stretching, etc. Nonisometric resistance exercises using rubber tubing may be started at approximately six weeks when there is earlier X-ray evidence of tuberosity healing.

During all phases of rehabilitation the patient should be instructed on appropriate shoulder-stretching exercises and activities of daily living. Strengthening exercises of the deltoid and rotator cuff are gradually begun with Therabands. Exercise with light hand weights is introduced when appropriate.

The goal of rehabilitation should be gradual rather than rapid improvement in ROM. Attempt to gain 150° of passive ROM in forward elevation within the first four weeks. A major goal should be 90° active forward flexion achieved by the 2nd month. Rehabilitation should continue for up to a year and improvement can be expected throughout this time.

Conclusion

The reproduction of normal humeral length, appropriate retroversion of the humerus, tuberosity fixation, and ultimate union are mandatory for a successful result in hemiarthroplasty for acute fractures of the proximal humerus. Successful results can only be achieved if the patient agrees to undergo extensive rehabilitation after surgery.

Ordering Information

Implants and Trials

Comprehensive™ Fracture Stem		
Part No.	Trials	Description
113554	406904	4mm
113556	406906	6mm
113558	406908	8mm
113560	406910	10mm
113562	406912	12mm
113564	406914	14mm

Standard Humeral Heads		
Part No.	Trials	Description
113760	406530	40 x 15mm
113762	406532	40 x 20mm
113757	406528	40 x 22mm
113763	406533	44 x 15mm
113764	406534	44 x 17mm
113766	406536	44 x 22mm
113768	406538	44 x 27mm
113769	406529	48 x 19mm
113770	406540	48 x 24mm
113771	406531	48 x 27mm
113772	406537	54 x 22mm
113775	406535	54 x 24mm
113774	406539	54 x 27mm

Offset Humeral Heads		
Part No.	Trials	Description
113921	406721	44 x 17mm
113922	406722	44 x 22mm
113923	406723	44 x 27mm
113924	406724	48 x 19mm
113925	406725	48 x 24mm
113926	406726	48 x 27mm
113927	406727	54 x 22mm
113928	406728	54 x 24mm
113929	406729	54 x 27mm

Extended Articular Surface Heads		
Part No.	Trials	Description
113880	406680	40 x 15mm
113882	406682	40 x 20mm
113884	406684	44 x 17mm
113886	406686	44 x 22mm
113888	406688	44 x 27mm
113890	406690	48 x 19mm
113892	406692	48 x 24mm
113894	406694	54 x 22mm
113896	406696	54 x 24mm

Ordering Information

Instrumentation

Outer Case

595190

Humeral Resection/Reamer Tray

595168

Humeral Trial/Inserter Tray

595191

Extramedullary Resection Guide

406998

Intramedullary Resection Guide Boom

406625

Intramedullary Resection Guide Block

406999

Threaded Steinmann Pins (Sterile)

406669

T-Handle Ratcheting

406801

Humeral Reamer

406804	4mm
406805	5mm
406806	6mm
406807	7mm
406808	8mm
406809	9mm
406810	10mm
406811	11mm
406812	12mm
406813	13mm
406814	14mm
406815	15mm
406816	16mm

Fracture Stem Inserter

406901

Fracture Stem Extractor

406997

Tuberosity Clamps

406994

X-Ray Templates

406996

Inserter Taper Replacement Kit

406995



BIOMET

ORTHOPEDICS, INC.

THE MOST RESPONSIVE COMPANY IN ORTHOPEDICS™

P.O. Box 587, Warsaw, IN 46581-0587 • 574.267.6639 • ©2003 Biomet Orthopedics, Inc. All Rights Reserved
web site: www.biomet.com • eMail: biomet@biomet.com

Form No. Y-BMT-828/103103/M