

Copeland™

Humeral Resurfacing Head



BIOMET
ORTHOPEDICS, INC.

Copeland™

Humeral Resurfacing Head

Anatomical Alignment^{1,2}

- Exact retroversion
- Exact angle of inclination
- Exact posterior offset

Minimal Bone Removal

- Surface-only replacement
- No penetration of intramedullary canal

Proven Clinical Results^{3,4}

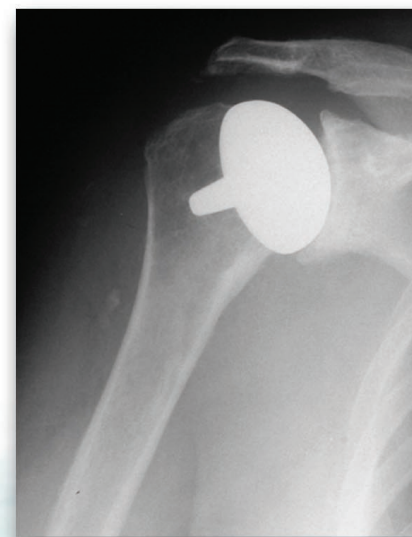
- Cementless Surface Replacement Arthroplasty of the Shoulder: 11 Years Experience
- Cementless Surface Replacement Arthroplasty of the Shoulder: 5–10 Year Results with the Copeland, Mark-2 Prostheses

Uncomplicated Revisions


- Removal of resurfacing component only and replace; or
- Resect the humeral head and component together and continue with a stemmed component

3-Step Bone Preparation

1. Find head center
2. Drill for central peg
3. Ream to define head shape



Cobalt Chrome humeral head for biocompatibility and superior wear characteristics



Tapered edges to provide a seamless blend into the humerus

Titanium plasma sprayed MacroBond® inner coating to maximize bony adhesion and enhance cement fixation

Fluted stem to provide for cement mantle

Tapered post with blasted finish for immediate mechanical press-fit

Undersurface is dome-shaped to allow for maximum bone preservation

Surgical Technique

General Considerations

The prosthesis is suitable for insertion via either technique:

- A. The standard anterior deltopectoral approach
- B. The antero-superior "Mackenzie"⁵ approach

The advantages of the antero-superior technique are:

- Smaller and more cosmetic scar
- Quicker post-operative recovery
- Easier access via rotator interval
- Easier access for glenoid resurfacing
- Better access to reconstruct the posterior and superior rotator cuff
- Easy access for acromioplasty and excision arthroplasty of the acromioclavicular (AC) joint, if indicated

If the rotator cuff is intact or a repairable rotator cuff defect is seen, then an anterior acromioplasty can be made with partial resection of the coracoacromial ligament. (The coracoacromial arch is left undisturbed if there is complete loss of rotator cuff.) If preoperative X-rays have indicated an arthritic change at the acromioclavicular joint and symptoms suggest this is a site of pain, then an excision arthroplasty can be done at this stage. (Excision of the AC joint improves exposure.)

Patient Positioning

Preoperative Preparation and Patient Position

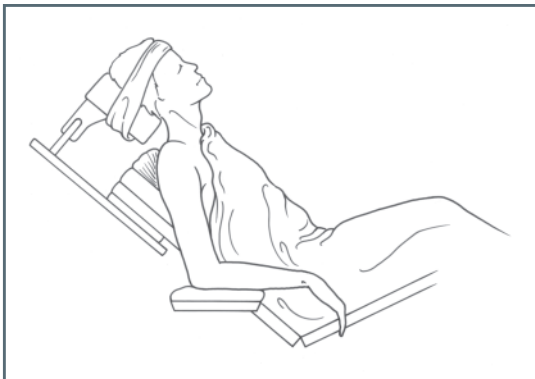

Fig. 1

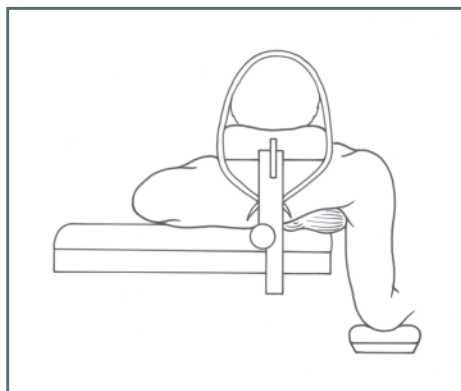


Fig. 2

Preoperative prophylactic antibiotics should be given intravenously either one hour prior to surgery or at the time of anaesthetic induction. In patients who are not sensitive to iodine, a skin pre-preparation using povidone iodine is performed in the ward prior to surgery.

A soaked surgical dressing is placed into the axilla, which may be clipped no more than 6 hours before the operation.

The patient should be placed in a semi-sitting or beach chair position at about 45° of head-up tilt with the head on a neurosurgical headpiece and the arm on a short arm board attached to the side of the operating table [Fig. 1]. It is important to have the patient close to the edge of the table and the short arm board to permit hyperextension of the arm during surgery to allow delivery of the humeral head into the anterior wound and to facilitate insertion of the humeral component [Fig. 2]. The shoulder blade is best stabilized by placing a small (500ml) plastic infusion bag or a sandbag under the medial border of the scapula.

Routine antiseptic preparation of the skin of the whole of the arm is carried out. The preparation is continued as far proximally as the ear and as far distally as the breast, as far medially as the midline anteriorly and as far as the infusion bag or sandbag posteriorly. The forearm and arm should be covered with a sterile stockinette and either an upper limb isolation drape or a "U" drape should be used to provide a safe sterile field. An adhesive plastic sterile drape is then applied to ensure the drapes do not "migrate" during the operation.

Surgical Incision

Option A Deltopectoral Approach

Access

This approach provides an exposure of the front of the gleno-humeral joint, the upper humeral shaft and the humeral head.

Incision

A 15cm incision is made from the clavicle down across the tip of the coracoid and continued in a straight line to the anterior border of the insertion of the deltoid [Fig. 3].

Approach

The cephalic vein is mobilized lateral in the deltopectoral groove. The vein is retracted laterally with the deltoid. The arm is abducted 40° to 60°. The clavipectoral fascia is incised. The subacromial space is cleared and a broad elevator is placed beneath the acromion as a retractor. At this stage improved exposure will be obtained by dividing the proximal 2cm of the insertion of pectoralis major [Fig. 4].

The shoulder is flexed and externally rotated to facilitate coagulation of the anterior circumflex humeral vessels. It is very important at this stage to insert stay sutures into the subscapularis muscle to control retraction [Fig. 5]. The tendon is divided 2cm medial to the bicipital groove. If the subscapularis appears tight it should be divided in an oblique or "Z" manner to allow repair with lengthening of the tendon.

The joint capsule is then released anteriorly and inferiorly while taking care to protect the axillary nerve with a blunt elevator where it passes through the quadrilateral space. The glenohumeral joint may now be dislocated anteriorly by external rotation and extension, allowing a full exposure of the humeral head and neck.

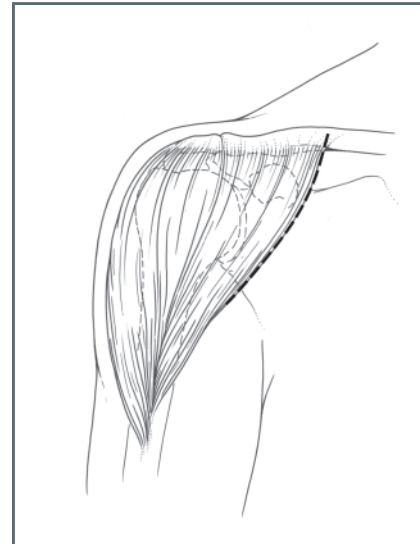

Fig. 3

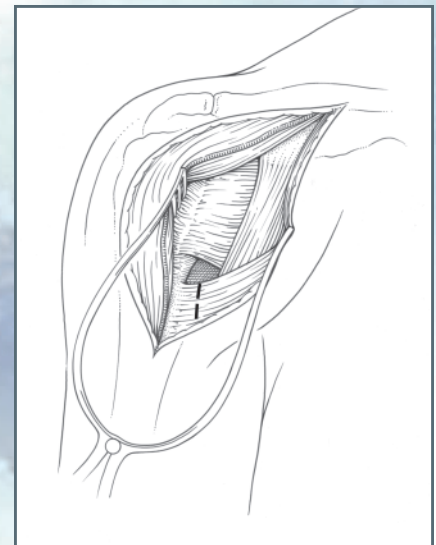
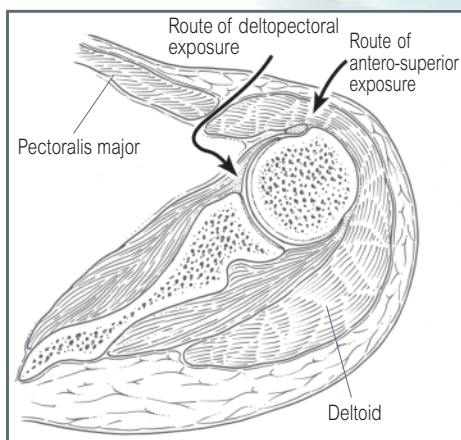


Fig. 4



Approach Comparisons

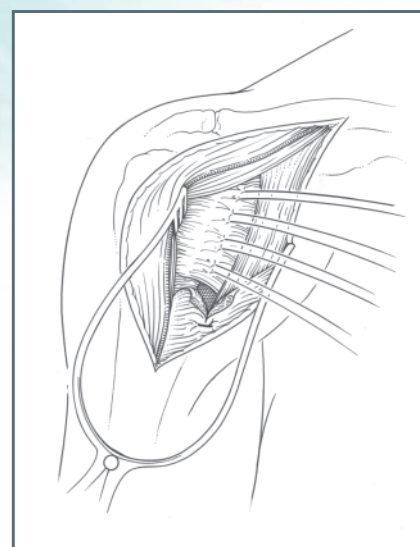


Fig. 5

Surgical Incision

Option B Antero-superior “Mackenzie” Approach

Access

This approach provides an exposure of the glenohumeral joint, the humeral head, and the tuberosities, as well as exposure of the acromion and AC joint.

Incision

The skin incision extends distally in a straight line from just posterior to the acromioclavicular joint for a distance of 9cm [Fig. 6].

Approach

The anterior deltoid fibers are split for a distance of not more than 6cm, and a loose No. 1 stay suture is placed in the distal end of the split to prevent further extension and possible injury to the axillary nerve. The acromial attachment of the deltoid is lifted with an osteo-periosteal flap to expose the anterior acromion and preservation of the superior acromioclavicular ligament [Fig. 7].

An anterior acromioplasty according to the technique of Neer is performed.

If further exposure is needed, then excision of the lateral end of 1cm of clavicle considerably enhances this.

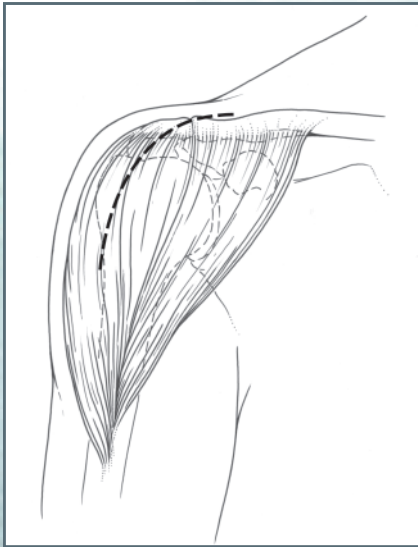

Fig. 6

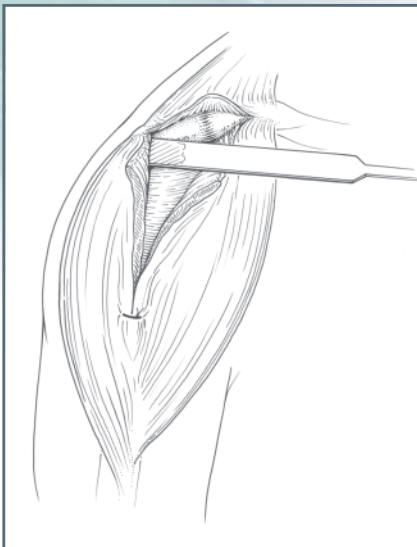


Fig. 7

Both Approaches:

The rotator interval is identified and longitudinally incised along the line of the long head of the biceps to identify the exact insertion of the subscapularis. The subscapularis is held by stay sutures and disinserted [Fig. 8]. The shoulder is dislocated anteriorly and the long head of biceps, if intact, is dislocated posteriorly over the humeral head [Fig. 9].

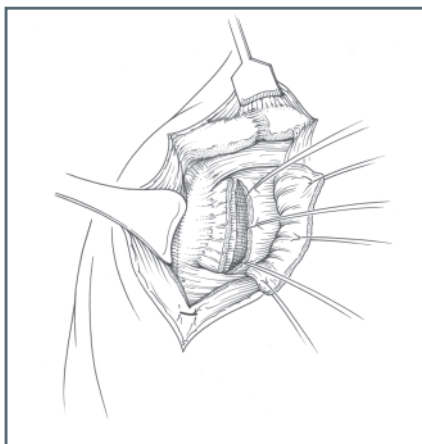


Fig. 8

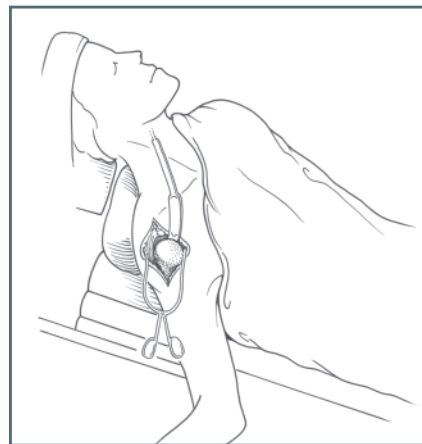


Fig. 9

Preparation of Humeral Head

The anatomical neck of the humerus is defined (the line of insertion of the cuff and capsule) to determine the exact neck shaft angle. Osteophytes are nibbled away from the superior and the anterior aspect of the humeral neck while further external rotation and positioning of the arm allows removal of inferior osteophytes [Fig. 10]. The preoperative radiographs are helpful to assess the extent of these osteophytes. Anterior osteophytes can contribute to loss of external rotation by relatively shortening the subscapularis. Removal of these osteophytes also allows better positioning and rotation of the head to gain access to the posterior and superior osteophytes that also need removal. (Removal of these osteophytes is essential to determine the anatomical neck, not to shape the humeral head. Shaping is done utilizing the humeral surface cutter.)

The humeral drill guide is then placed on top of the humeral head. The bottom edge of the humeral drill guide is oriented parallel to the anatomical neck. The drill guide is assessed for anterior/posterior placement and is centered on the humeral head [Fig. 11]. This position automatically builds in the anatomical degrees of retroversion and inclination. A K-wire or Steinman pin guide wire is then passed down the humeral drill guide into the humeral head [Fig. 12] and through to the lateral cortex to provide stability.

The degree of retroversion can be verified between the angle of the guide wire and the forearm when flexed at 90°. There is no fixed degree of version attempted because our goal is a reproduction of the anatomical version (ranging from 5 to 55° of retroversion). The humeral drill guide is removed and the position of the K-wire checked to ensure that it is both anatomical and centered in the humeral head.

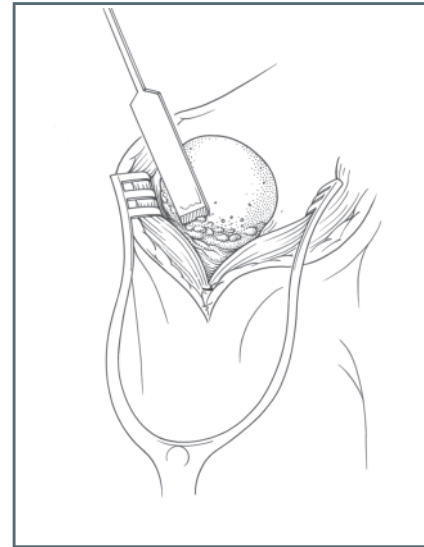


Fig. 10

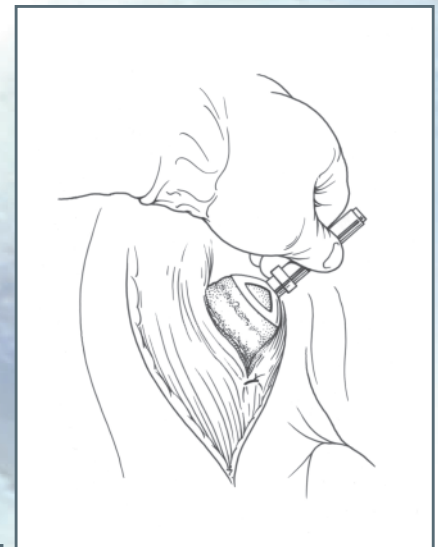


Fig. 11

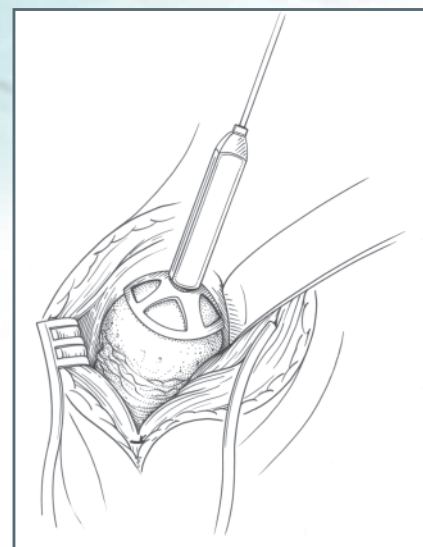


Fig. 12

Preparation of Humeral Head

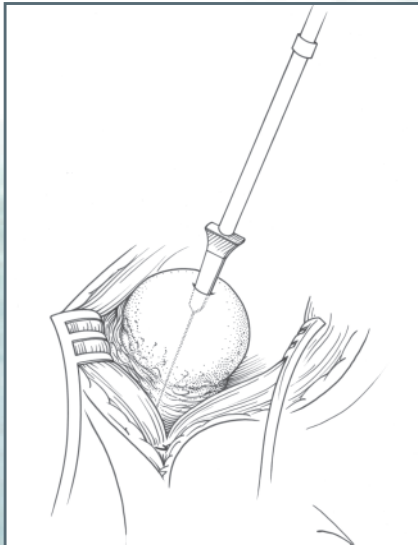


Fig. 13

The cannulated spade bit is passed over the guide wire and, using a cannulated power drill with a 1/4" Jacobs chuck, the central pilot hole is made down to the "stop" of the bit [Fig. 13]. The bit and guide wire are removed. (All morselized bone generated by making this drill hole should be saved and used for later grafting.)

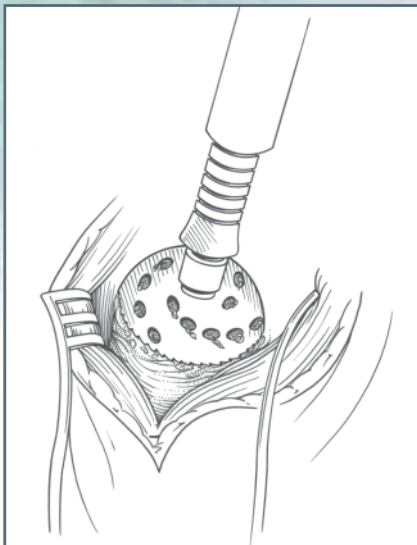


Fig. 14

The humeral surface cutter is then used to shape the humeral head. The central locating peg is directed into the pilot hole and the grater action used to shape the humeral head. The surface cutter is gently pressed down onto the humeral head such that, while it is rotating, bone appears through all the holes in the surface cutter [Fig. 14]. This facilitates complete bony apposition to the undersurface of the prosthesis. The surface cutter also delineates the edge of where the prosthesis will meet the bone. This marks further bone to be removed from the periphery of the head using a small osteotome or bone nibblers. The edge of this cut now appears beneath the normal surface of the bone. Note: The hard osteochondral plate should be left intact, if possible, as this provides good prosthetic support.

It is intended that the depth of the prosthesis will build up this new cut surface back to the normal anatomical surface of the bone. The trial humeral prosthesis is then placed onto the prepared bone and a trial reduction is made [Fig 15]. Stability and range of motion can be tested at this time (i.e. that the hand can easily go to the opposite axilla and at least 30° of external rotation can be achieved before anterior translocation). The prosthesis is also checked for stability in flexion/extension.

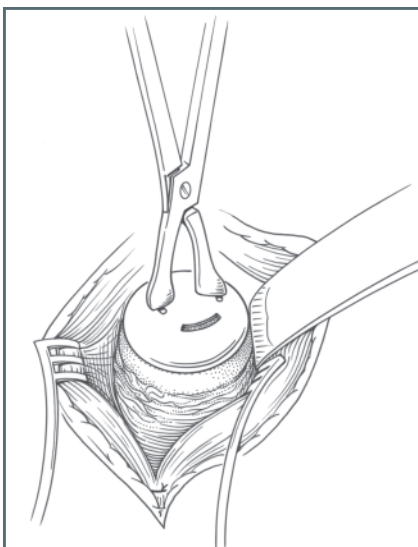


Fig. 15

Insertion of Component

The trial humeral component is now removed and the humeral head viewed. Irregularities in the humeral head are routinely grafted using bone from osteophytes which had previously been removed. Press-fit the component by placing the resurfacing head onto the prepared humeral head and seating the component about two-thirds of the way with finger pressure. (When cementing, fill the peg hole with cement before placing the component.) The humeral prosthesis is then impacted until it is flush against the bone. While applying tension to the subscapularis stay sutures, assess the position of reattachment of the subscapularis. Usually, because of the resultant lateralization of the center of rotation, an attempt is made to gain relative length in the subscapularis. This can be gained in two ways: (1) by performing a Z-plasty on the subscapularis when entering the joint and (2) by medialization of the insertion of the subscapularis to the free edge of the prosthesis [Fig. 16].

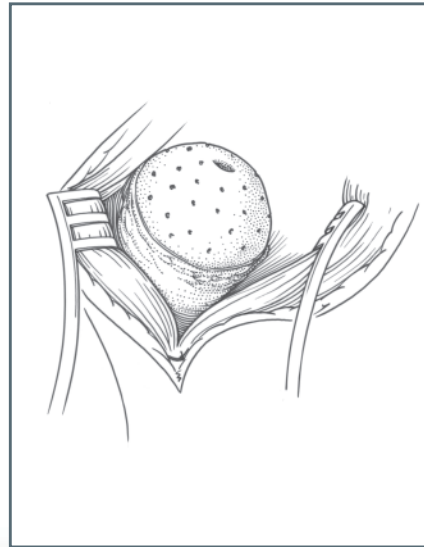


Fig. 16

Closure

Deltopectoral Approach

The subscapularis is repaired using No. 1 suture material (absorbable [PDS] or non-absorbable) without plicating the subscapularis or with through bone sutures. The rotator interval is closed. If there is any rotator cuff deficiency then full rotator cuff repair is made in the normal manner at this stage. Every attempt is made to close the rotator cuff completely.

The delto-pectoral interval is closed using 2 or 3 interrupted absorbable sutures.

Subcutaneous fat is opposed with absorbable sutures and appropriate skin closure undertaken with Intra-dermal continuous absorbable suture (3/0 Monocryl).

Antero-superior “Mackenzie” Approach

The subscapularis is repaired using No. 1 suture material (absorbable [PDS] or non-absorbable) without plicating the subscapularis or with through bone sutures. The rotator interval is closed. If there is any rotator cuff deficiency then full rotator cuff repair is made in the normal manner at this stage. Every attempt is made to close the rotator cuff completely.

The deltoid is reattached to the acromion with No. 1 absorbable sutures (PDS) through bone [Fig. 17].

The deltoid split is approximated with 2/0 absorbable suture.

Subcutaneous fat is opposed with absorbable sutures and appropriate skin closure undertaken with Intra-dermal continuous absorbable suture (3/0 Monocryl).

Postoperative Management

The patient is placed in a sling with bodybelt and brachial block analgesia is used. Passive mobilizing is recommended for the first 48 hours and passive assistance for five days thereafter. Active movements are then started as pain allows and the sling abandoned at three weeks. A stretching and strengthening program is then advised standard for all shoulder replacements.

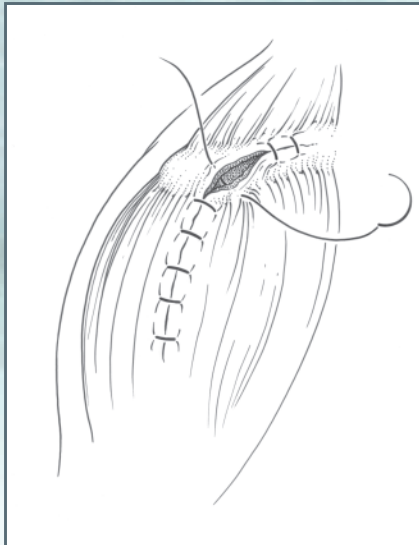


Fig. 17

References

¹Williams GR, Iannotti JP: "Anatomy and biomechanics of the glenohumeral joint related to shoulder arthroplasty." *Seminars in Arthroplasty* 11(1):2-15, 2000.

²Boileau P, Walch G: "Three-dimensional geometry of the proximal humerus: Implications for surgical technique and prosthetic design." *J Bone Joint Surg (B)* 1997; 79-B: 857-65.

³Levy O, Bruguera J, Kelly C, Copeland SA: "Cementless surface replacement arthroplasty of the shoulder — 11 years experience." *ICCS*, Sydney, 1998.

⁴Levy O, Copeland SA: "Cementless surface replacement arthroplasty of the shoulder: 5 to 10 year results with the Copeland, Mark-2 prostheses." *J Bone Joint Surg (B)*, 2000; 83-B: 213-21.

⁵Mackenzie DB: "The antero-superior exposure for total shoulder replacement." *Orthop. Traumatol* 1993; 2:71-7.

This brochure describes the surgical technique used by Steven A. Copeland, F.R.C.S. Biomet, as the manufacturer of this device, does not practice medicine and does not recommend this or any other surgical technique for use on a specific patient. The surgeon who performs any implant procedure is responsible for determining and using the appropriate techniques for implanting the prosthesis in each individual patient. Biomet is not responsible for selection of the appropriate surgical technique to be used for an individual patient.

The Copeland™ Surface Replacement Arthroplasty (CSRA) of the shoulder was developed by Steven A. Copeland, F.R.C.S., Consultant Orthopaedic Surgeon at the Royal Berkshire Hospital, Reading, England, U.K.

This device is intended to be used in the United States as described in the product labeling.

Copeland™ and MacroBond® are trademarks of Biomet, Inc.



CopelandTM
Humeral Resurfacing Head



P.O. Box 587, Warsaw, IN 46581-0587 • 219.267.6639 ©2001 Biomet Orthopedics, Inc. All Rights Reserved
web site: www.biomet.com • eMail: biomet@biomet.com
Form No. Y-BMT-725/093001/M