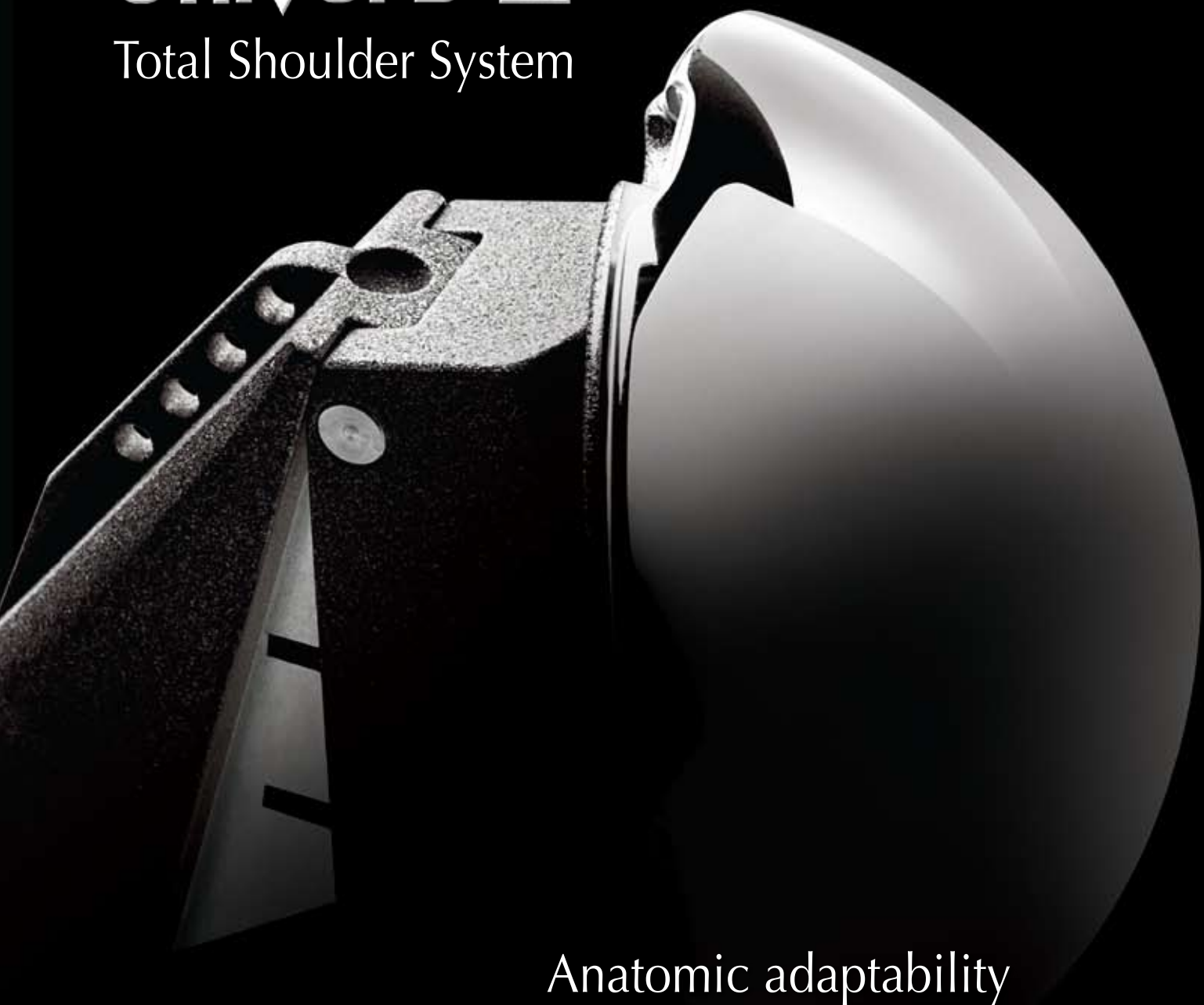


Univers™ II

Total Shoulder System



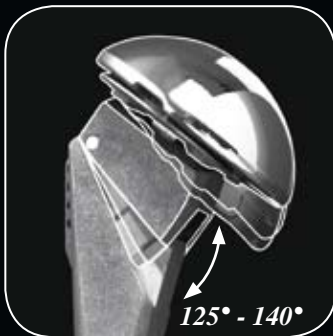Anatomic adaptability
... *simplified*

SURGICAL TECHNIQUE

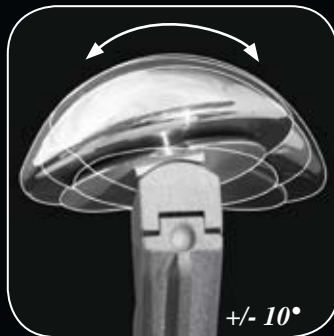Arthrex® 



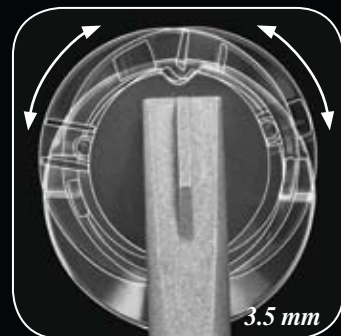
Inclination



Version



Offset



A **Univers**™ of Possibilities

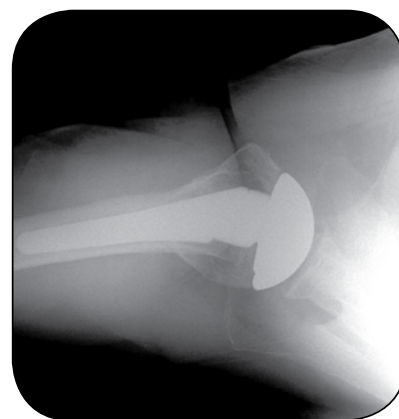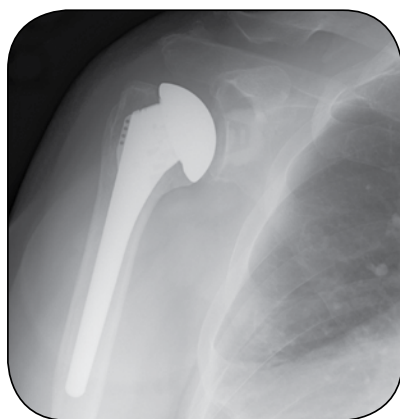The Univers™ II Total Shoulder System was designed in cooperation with Anthony Romeo, M.D., Rush University Medical Center, Chicago, IL and Professor Peter Habermeyer, M.D., ATOS Clinic, Heidelberg, Germany.

Univers[™] II TOTAL SHOULDER SYSTEM

The Definitive Anatomic Solution for Total Shoulder Arthroplasty

IMPLANT DESIGN RATIONALE

The Univers II humeral component was designed to account for anatomical variations of the proximal humerus commonly encountered by the surgeon. Variable adjustment with respect to the inclination angle, version and head offset are features critical to reconstruction of the proximal humerus. The simplified design of the Univers II humeral component allows the surgeon to adapt the humeral stem and articular surface to the position that best represents the patient's normal anatomy. All of the adjustments can be made intraoperatively with the implant in the humeral canal. This unique feature allows the surgeon to more accurately recreate the normal anatomical relationships of the shoulder joint. With anatomic restoration of the humerus and glenoid, soft tissue balancing of the rotator cuff is more accurate, allowing for improved functional outcome.




IMPLANT FEATURES:

- Variable inclination, version and offset
- Package-to-canal design: Anatomic restoration in situ
- Eccentric humeral heads
- Multiple head diameters and heights for precise anatomic reconstruction
- Instruments and trays designed to maximize efficiency in the operating room
- Keeled and pegged glenoid options available



Keeled Glenoid:

- Dual fenestrations for enhanced anchoring
- Reverse barbs for expansion effect within the glenoid vault



Pegged Glenoid:

- Unique 2-pegged design features a curved keel with reverse barbs and large fenestration for excellent fixation strength

SURGICAL APPROACH

As described by Anthony Romeo, M.D., Rush University Medical Center, Chicago, IL

1. PATIENT POSITIONING

Following general anesthesia, the patient is placed in the beach chair (semi-sitting) position. Typically the angle is 30-45° of elevation with respect to the operating room floor. The head and neck are secured using a ring headrest which is helpful for maintaining the head and neck position throughout the procedure. The endotracheal tube and intravenous lines are positioned on the contralateral side of the affected shoulder. The upper body is brought to the edge of the operating room table to allow full extension of the arm, which is essential for the exposure of the proximal humerus. A folded towel is placed behind the medial border of the scapula to stabilize the position of the glenoid throughout the procedure. A sterile preparation and draping is performed on the shoulder and arm to allow full exposure and free movement of the entire limb.

2. INCISION AND EXPOSURE

The deltopectoral incision begins at the inferior border of the midsection of the clavicle, proceeds at an angle past the medial aspect of the coracoid prominence, and ends at the superior aspect of the axillary fold. The skin incision often lies directly over the cephalic vein, and therefore the interval between the deltoid and pectoralis major muscles.

The cephalic vein clearly defines the junction between the deltoid and pectoralis major muscles. If the vein is not readily identified, the prominence of the coracoid also marks the deltopectoral interval, or the surgeon can identify the fibrous portion of the superior aspect of the pectoralis tendon at the distal part of the incision. The vein can be mobilized medially or laterally.

The conjoined tendon complex consisting of the short head of the biceps and the coracobrachialis muscle is identified. The muscular portion of the biceps (red) is the most lateral part of the conjoined tendon, with the tendinous portion (white) just medial to the visible muscle. The approach through the clavipectoral fascia is just lateral to the “red stripe” representing the muscular portion of the short head of the biceps. The deltoid muscle is carefully mobilized laterally and protected. The coracoacromial ligament is maintained (not released). A thin retractor (eg. Homann or Darrach) is placed under the coracoacromial ligament to provide exposure to the superior aspect of the subscapularis and humerus. Retraction of the deltoid and pectoralis major is maintained with a self-retaining retractor. Frequently, the superior 1-2 cm of the pectoralis tendon is released to provide exposure to the inferior aspect of the subscapularis and the anterior circumflex vessels. The arm is then externally rotated to further expose the boundaries of the subscapularis muscle and tendon insertion. The superior aspect of the subscapularis tendon is at the level of the coracoid tip and can be clearly identified by excising part of the subcoracoid bursa and rotator interval capsule. The inferior border of the subscapularis tendon is at the level of the anterior circumflex vessels. This group of vessels includes the anterior circumflex artery bordered by two anterior circumflex veins and is commonly referred to as the “Three Sisters”. The lateral border of the subscapularis tendon is identified just medial to the bicipital groove. Two tag stitches using #2 FiberWire® are placed into the medial aspect of the subscapularis tendon in preparation for the subscapularis release.

3. SUBSCAPULARIS RELEASE

For uncomplicated shoulder arthroplasty a transtendon approach is preferred, leaving 5 mm of tendon attached to the lesser tuberosity for later repair of the tendon to both the bone and the remaining tendon. The subscapularis tendon is entirely released beginning at the rotator interval over the top of the biceps and proceeding inferiorly below the level of the anterior circumflex vessels, continuing along the humeral neck. The humerus is externally rotated to facilitate the release of the capsule from the humerus to the 6 o'clock position on the humerus.



4. GLENOHUMERAL CAPSULE RELEASE

Once the subscapularis tendon is released from the humerus, the surgeon has an opportunity to release the anterior and inferior capsule with excellent direct visualization. This capsular release is a routine part of shoulder arthroplasty for patients with a loss of external rotation, most commonly seen in osteoarthritis patients. A ring retractor (Fukuda) is placed across the glenohumeral joint and hooked on the posterior glenoid. The retractor is used to sublax the humerus, posterior and lateral, placing tension in the inferior capsule. The junction between the muscular portion of the subscapularis (red) and the capsule (white) is clearly identified. The axillary nerve is generally just inferior to the muscular portion of the subscapularis or less than 1 cm from the capsule. The nerve should be identified and protected. With tension in the capsule, it is released from lateral to medial, ending at the 6 o'clock position on the glenoid. The anterior capsule is bluntly separated from the subscapularis and sharply incised (capsulotomy). Finally, the fibrous attachments from the lateral aspect of the coracoid to the subscapularis are released completing mobilization of the subscapularis when combined with the anterior/inferior capsulotomy. The release should remain lateral to the coracoid process to avoid injury to the nerve of the subscapularis and the brachial plexus. This step will be necessary for improved range of motion. The lack of bone preparation at this stage of the procedure provides excellent visualization of all the involved structures, particularly the capsule and its relationship to the axillary nerve. The subscapularis tendon is displaced medially under the coracoid process and held away from the surgical site with the self-retaining retractor, in anticipation of preparation of the humerus.

5. HUMERAL HEAD RESECTION

The humerus is dislocated from the glenoid using a flat retractor (eg. Darrach) as a shoehorn to gently guide the humerus out of the glenoid. The arm is externally rotated until a direct view of the entire humeral articular surface is achieved. This can be facilitated by using a flat retractor medially, as well as a retractor placed just behind the superior rotator cuff. The arm is held in greater than 90° of external rotation, 20-30° of extension, and adduction against the operating room table. If complete exposure of the humeral head articular surface cannot be accomplished, further capsulotomy may be necessary.

6. GLENOID EXPOSURE

Glenoid exposure begins with a complete anterior/inferior capsulotomy which is described in Section 4. This not only improves the motion postoperatively, but helps with visualization and exposure of the glenoid.

Following the identification and release of the capsule from the anterior/inferior aspect down to the 6 o'clock position, it is not unusual to have to continue the release further posteriorly, along the glenoid margin. Once the axillary nerve is identified, the release of the capsule may continue unimpeded until complete visualization of the glenoid is possible.

If the glenoid remains poorly visualized after the release of the anterior, inferior, and posterior capsule, additional steps may assist in achieving a direct approach to the glenoid. Full release of the deltopectoral interval should be confirmed. Additional release of the pectoralis major tendon can be included with repair of the tendon at the end of the procedure. Up to 1.5 cm of the tendon can be released safely and without consequence to increase visualization. On the deltoid side, the anterior attachment of the deltoid on the deltoid tubercle of the humerus can also be partially released.

Once a direct view of the glenoid is possible, a glenoid neck retractor is placed along the anterior glenoid neck, as medial as possible. This will help the surgeon with respect to the orientation of the glenoid, especially in cases where significant posterior erosion has occurred.

In any case, the important principle is to have a direct visualization of the face of the glenoid. Any deviation in the position of the component can lead to early failure of the arthroplasty.

HUMERAL PREPARATION



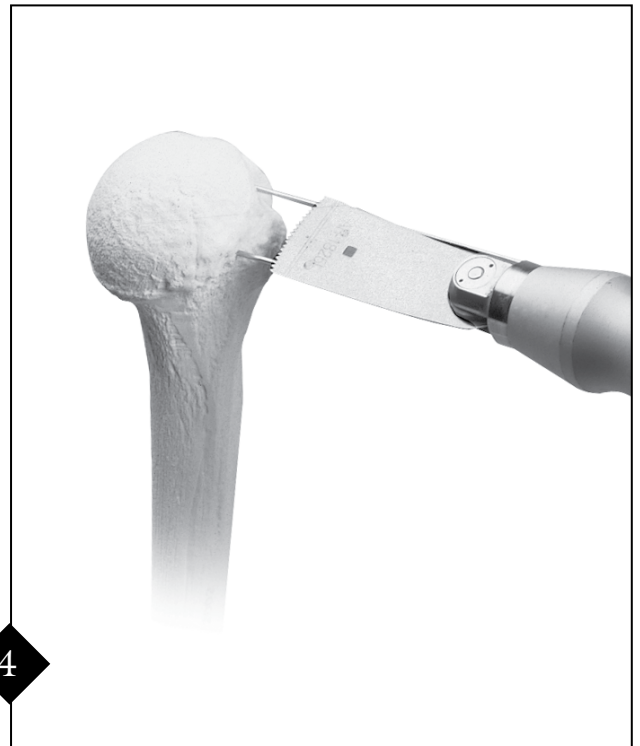Remove osteophytes with a Rongeur or small osteotome to identify the anatomic neck. Either the left or right, small or large Humeral Head Resection Guide is placed on the humeral head. Version Rods are placed in the guide at the 20° and/or 40° position and aligned with the forearm when the elbow is flexed 90° to determine retroversion. Typically, the forearm should be visualized between the position of the two Version Rods so that a retroversion of 30° is achieved based on the orientation of the forearm.



The appropriate guide size and position will result in subsequent pin placement across the anatomic neck. Once the appropriate position has been established, the 2.8 mm Steinman Pin is advanced down the center cannulation of the Humeral Head Resection Guide to secure it to bone.



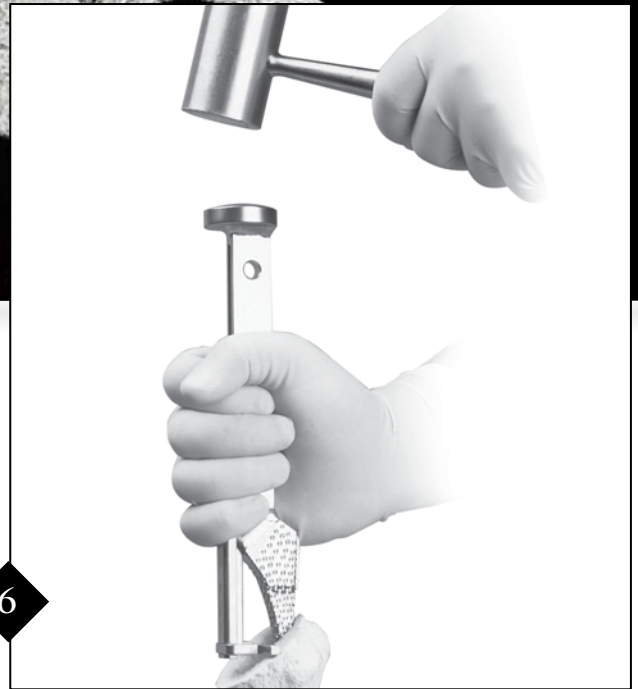Two 1.6 mm K-wires are drilled through the holes of the Humeral Head Resection Guide until they exit the opposite cortex.



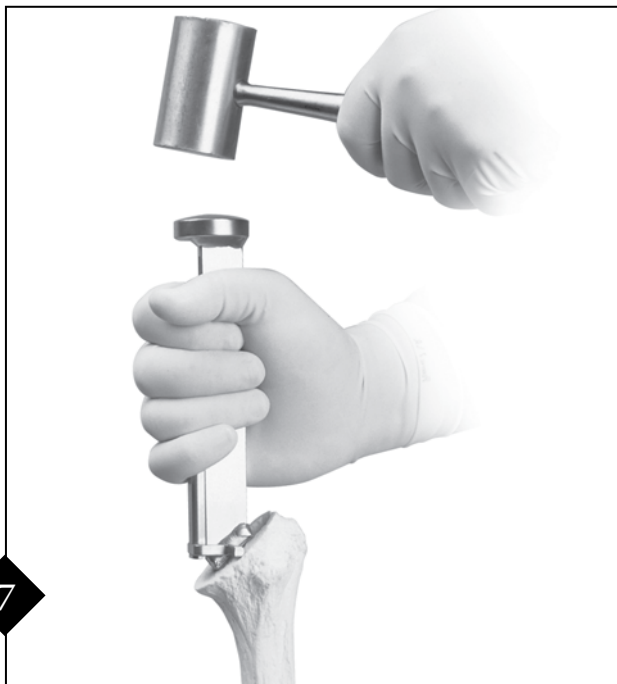The Steinman Pin is removed and the resection guide is disengaged from the K-wires. The humeral head is resected with a saw, using the K-wires as a guide. The resected humeral head or cut surface of the humerus is compared to a trial of corresponding size. The proportions should be noted for subsequent glenoid selection.



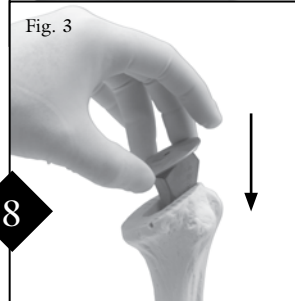
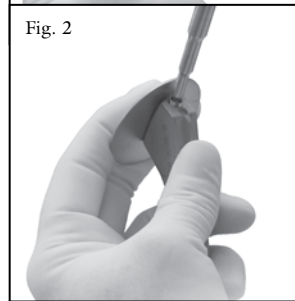
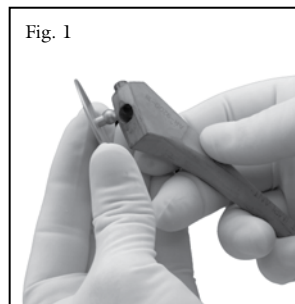
Attach the Reamer T-Handle to the 6 mm reamer. Position the tip at the superior lateral aspect of the humerus. Advance the reamer down the medullary canal to the circumferential groove adjacent to the cutting flutes. Repeat with the 7 mm reamer if necessary.



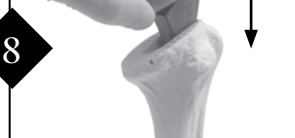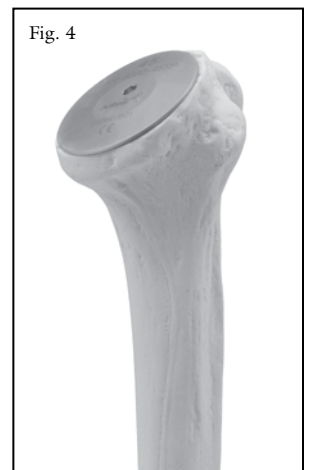Broaching begins with the 6 mm Humeral Broach. The Broach Alignment Guide is positioned onto the 6 mm broach. Advance the broach with a mallet slightly until the forks of the guide rest evenly on the medial surface of the resection. The guide assures the broach maintains proper orientation during impaction.



Each broach should be advanced until the angled laser mark is aligned with the resected surface. Proceed with the next size broach until the appropriate fit is obtained. Take care to stay within the inclination angle defined by the laser marks and not to over-broach. For noncemented application, select the implant which corresponds to the final broach size. *If cementing the stem is desired, an implant one size smaller than the final broach is recommended.*



A Resection Protector of appropriate diameter is assembled to a trial stem one size smaller than the canal preparation. Do not overtighten the set screw. This will allow the protector to rest evenly on the resected surface (Fig. 1-2). The construct is inserted into the proximal humerus until the plate comes to rest on the humeral cut (Fig. 3-4).



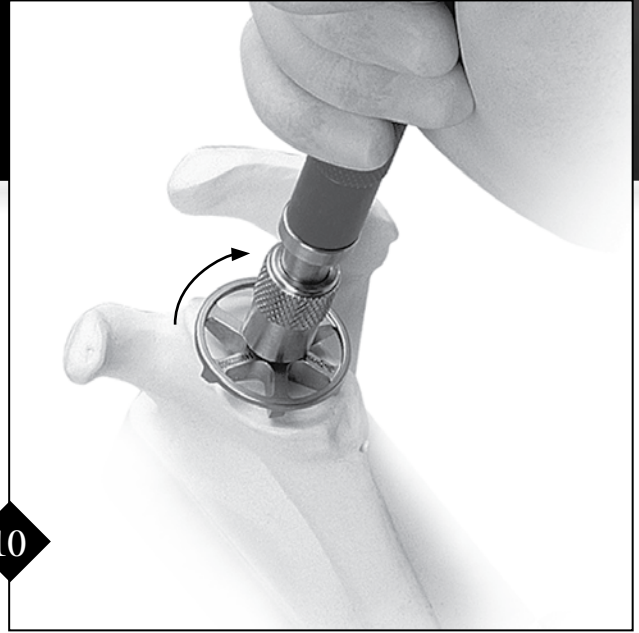
Proceed to Glenoid Preparation...
 For Keel Glenoid see Step 9, page 6
 For Pegged Glenoid see Step 9A, page 8

KEELED GLENOID PREPARATION AND IMPLANTATION



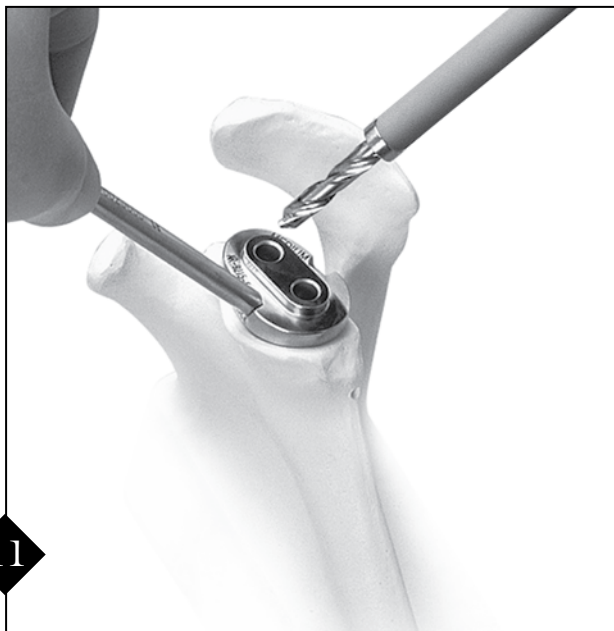9

The small, medium or large Glenoid Guide #1 (with single, central hole) is selected and a handle attached to the anterior side. The guide is placed on the central axis of the prepared glenoid. The handle of the guide is 65° to the orientation of the surface of the glenoid, which corresponds to the relatively fixed 65° anatomic slope of the anterior glenoid neck. This may help identify the proper orientation of the glenoid version. The 6 mm drill is used to drill a hole through the guide. There is a mechanical stop on the drill bit for depth control.



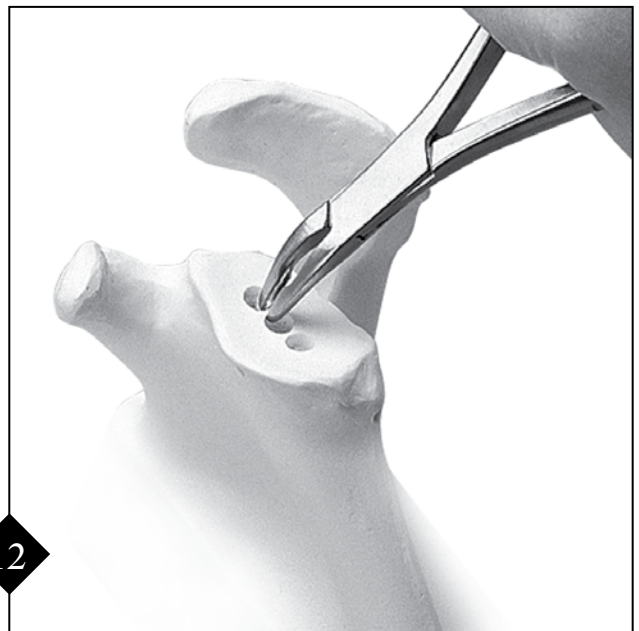
10

To prepare the glenoid surface, the appropriate size Glenoid Reamer is assembled to the reamer shaft. The reamer shaft may be driven by either the Reamer T-Handle or a powered handpiece with a Hudson-style fitting. The nipple end of the reamer is inserted into the central glenoid drill hole and reaming is initiated. The glenoid is reamed until the superior to inferior surface is made congruent to the mating implant component.



11

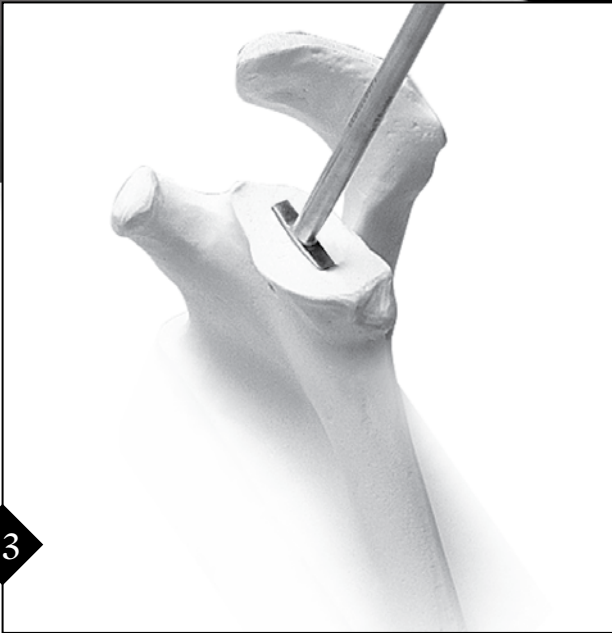The small, medium or large Glenoid Guide #2 (with two holes and peg) is selected and the handle attached. Again, the handle is oriented 65° to the face of the glenoid matching the normal anatomic slope of the anterior glenoid neck. The peg on the back of the guide is engaged in the previously drilled peg hole. The 6 mm drill is used to drill through both holes in the guide. If desired, the short drill bit can be disconnected and left in the first drill hole to function as anti-rotation peg during drilling of the final hole.



12

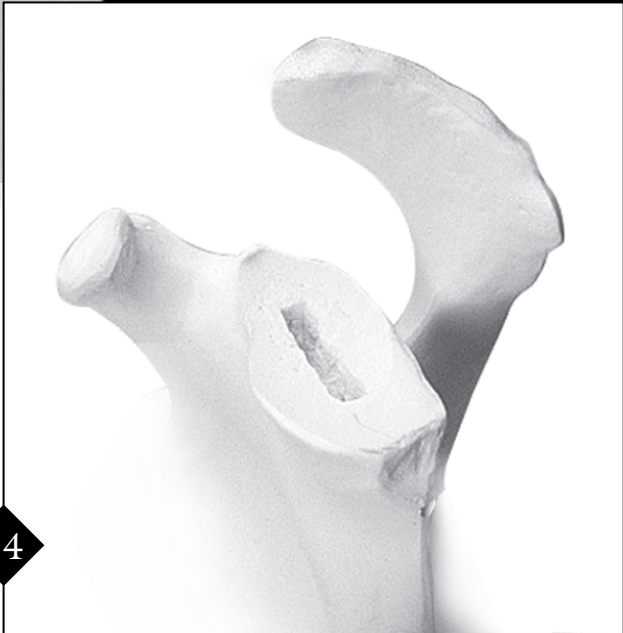
A small Rongeur is used to remove the bone bridge between the three drill holes, resulting in a roughly prepared glenoid slot.

13



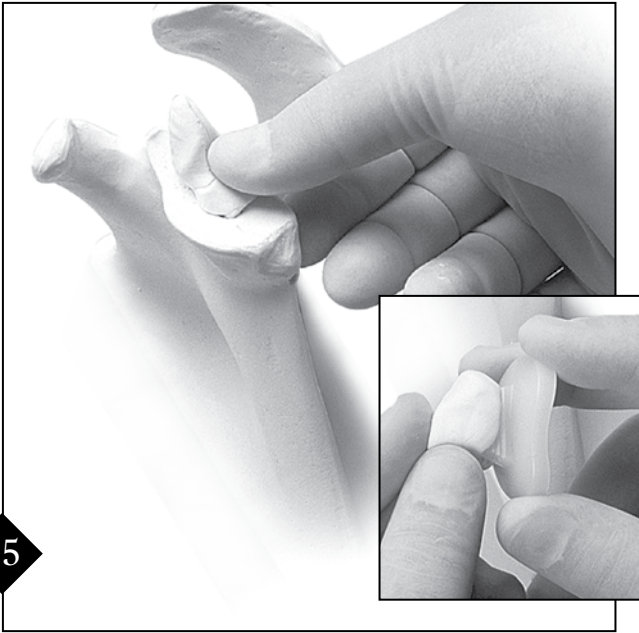
The Glenoid Punch is used to make the final preparation for the keel of the glenoid implant. Position the punch perpendicular to the glenoid surface. A mallet is used to advance the punch into the roughly prepared slot. The punch should be advanced until it is flush with the bone surface. The bone slot for the keel should closely match the geometry of the keel. Therefore, it is important to prepare the slot with the punch. Cement fixation will be enhanced by this method and with preservation of the cancellous bone of the glenoid vault.

14



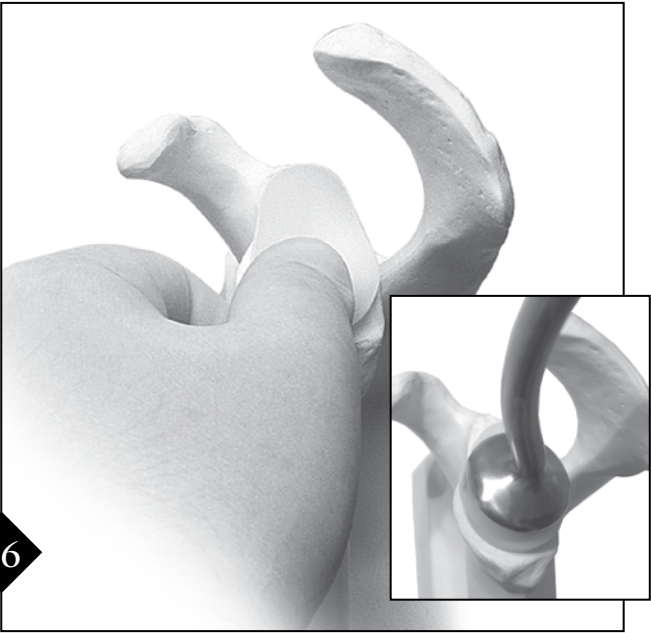
After preparing the glenoid for the keeled glenoid implant, meticulous irrigation and suctioning is performed to remove bone and soft tissue debris from the area. If desired, a keeled Glenoid Trial can be used at this time. Hemostasis should be achieved prior to proceeding with cemented glenoid placement.

15



The appropriate size glenoid is opened and bone cement is pressed into the fenestrations on the implant keel. Cement is inserted into the glenoid slot and is pressurized by hand using the Glenoid Punch. Cementing and pressurization should be alternated until a sufficient quantity of cement has filled the glenoid vault. Prior to Step 16, the slot should be filled with cement an additional time.


16



The keel of the implant is pushed into the cemented glenoid vault and impacted. Excess cement should be removed. The glenoid component is held firmly in place until the cement has cured.

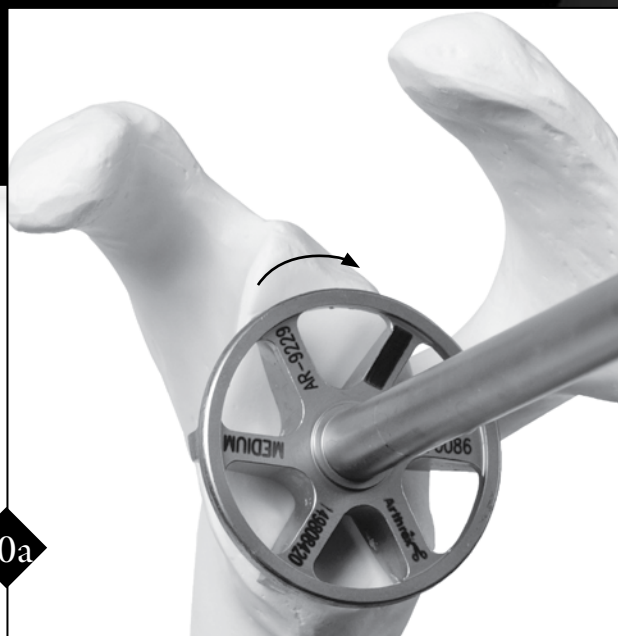When complete, proceed to Humeral Stem Implantation Step 19, page 11

PEGGED GLENOID PREPARATION AND IMPLANTATION



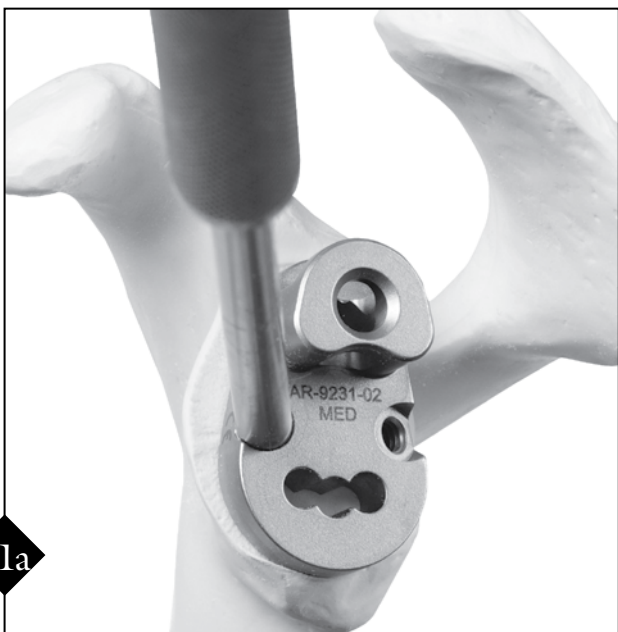9a

The small, medium or large Glenoid Guide #1 (with single, central hole) is selected and a handle attached to the anterior side. This guide is placed on the central axis of the prepared glenoid. The handle of this guide is 65° to the orientation of the surface of the glenoid, which corresponds to the relatively fixed 65° anatomic slope of the anterior glenoid neck. This may help identify the proper orientation of the glenoid version. The 6 mm drill is used to drill a hole through the guide. There is a mechanical stop on the drill bit for depth control.



10a

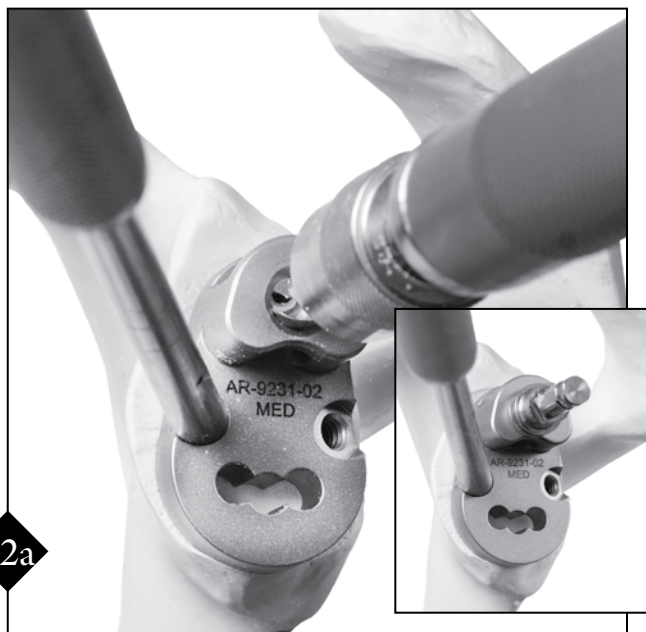
To prepare the glenoid surface, the appropriate size Glenoid Reamer is assembled to the reamer shaft. The reamer shaft may be driven with either the Reamer T-Handle or a powered handpiece with a Hudson-style fitting. The nipple end of the reamer is inserted into the central glenoid drill hole and reaming is initiated. The glenoid is reamed until the superior to inferior surface is made to be congruent to the mating implant component.



11a

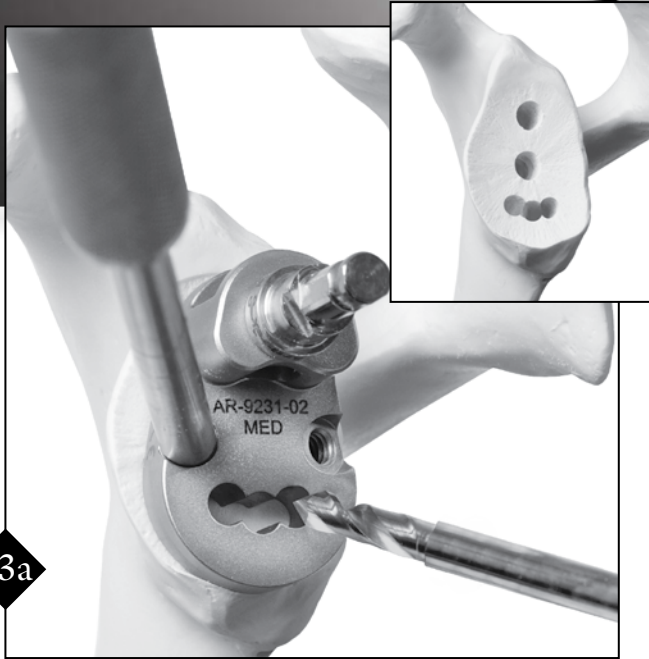
The Pegged Glenoid Guide #2 is moved into position by engaging the peg into the previously drilled central peg hole in the glenoid.

Note: If significant glenoid reaming has been performed and the Pegged Glenoid Guide #2 does not sit flush against the glenoid surface, it may be necessary to reinsert the Glenoid Guide #1 and redrill the central peg hole.




12a

The 6 mm Drill Bit is positioned into the reamer quick connect adapter and the superior glenoid hole is drilled. The drill is detached and remains in place to hold guide orientation.



13a

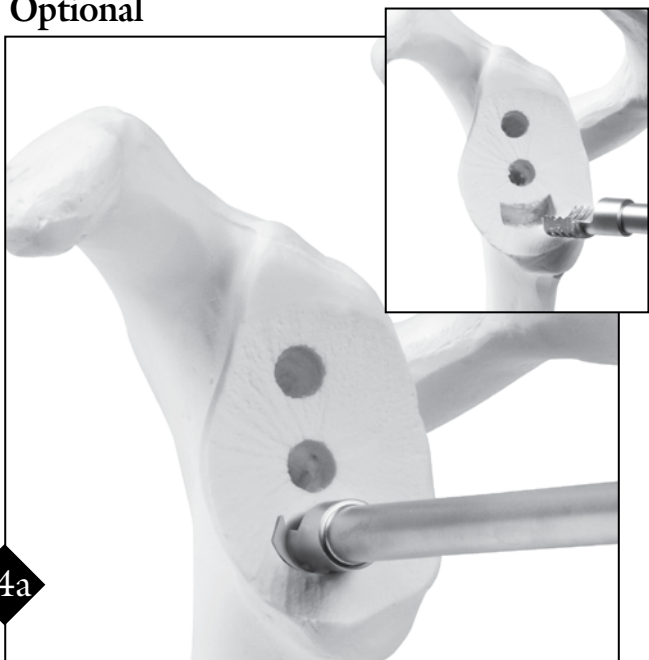
The 4.5 mm Drill is used to prepare the three inferior holes. There is a mechanical stop on the drill for depth control. The guide is removed.
Note: Insert drill into guide before activation.



14a

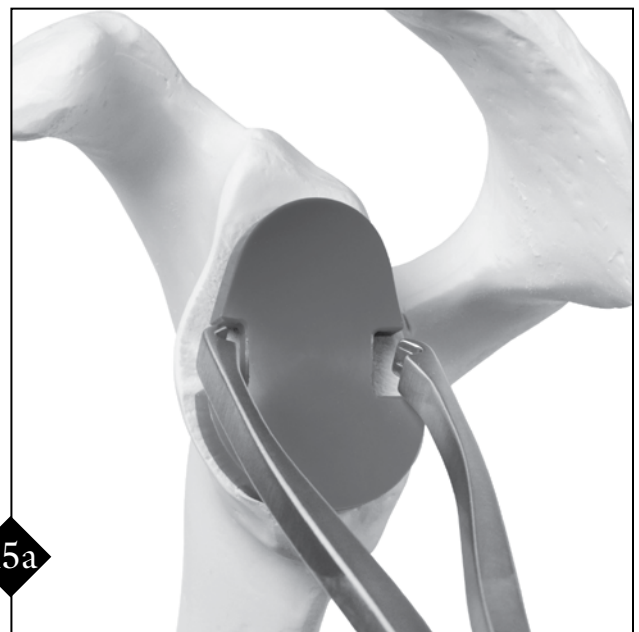
The pegs on the Glenoid Broach are engaged into the previously drilled holes. A mallet is used to advance the Glenoid Broach into the roughly prepared slot.

Optional



14a

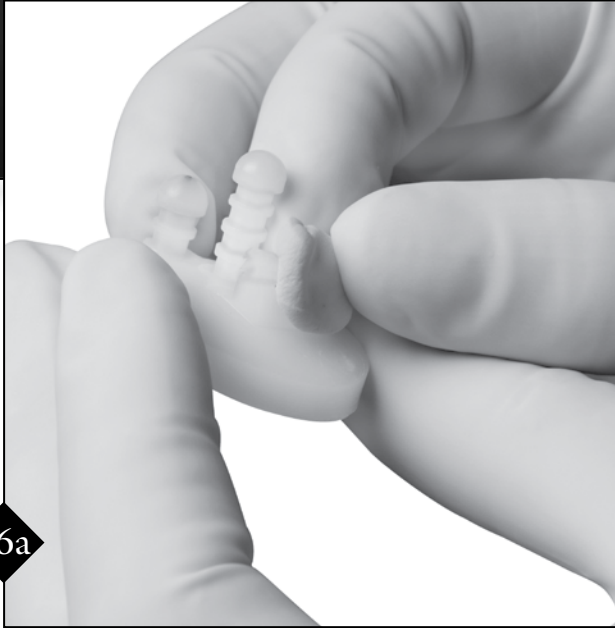Alternatively, the Pegged Glenoid Punch can be used to prepare the keel slot in place of the Glenoid Broach. The punch is advanced until the shoulder of the punch is flush with the bone surface.



15a

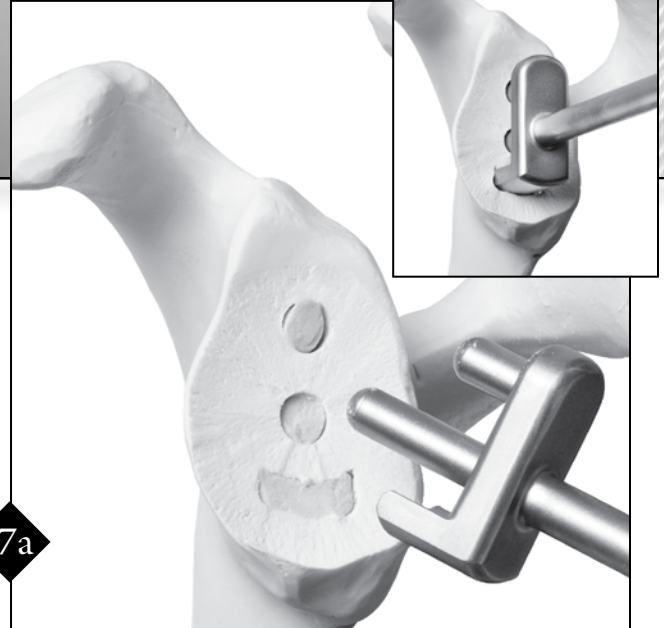
The Pegged Glenoid Trial can now be inserted with the Trial Forceps and impacted.
Note: Verify the trial is fully seated to ensure proper fit of the actual glenoid implant.

PEGGED GLENOID PREPARATION AND IMPLANTATION



16a

After preparation of the peg holes/keel slot, meticulous irrigation and suctioning is performed to remove bone and soft tissue debris from the area. Hemostasis should be achieved prior to proceeding with cemented glenoid placement. Once the glenoid has been fully prepared, the appropriate size glenoid implant is opened and bone cement is pressed into the fenestration on the implant keel and around the pegs.



17a

The keel slot and peg holes are packed with cement using a syringe or finger. The Pressurizer Tool is used to impact cement into the keel slot and peg holes and to create good cement interdigitation within the glenoid vault. Cementing and pressurization should be alternated until a sufficient quantity of cement has filled the glenoid vault. Prior to Step 18a, the holes and slot should be filled with cement an additional time.

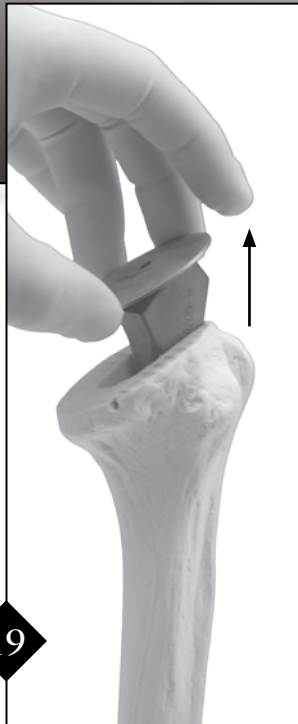


18a

The implant is pushed into the cement filled glenoid vault and impacted. Excess cement is removed and the glenoid component is held firmly in place until the cement has cured.

**When complete, proceed to Humeral Stem
Implantation Step 19, page 11**

HUMERAL STEM IMPLANTATION



19

The Resection Protector and trial stem are removed.




Fig. 1

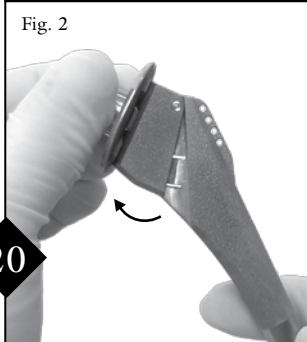


Fig. 2

20

The humeral implant is opened in a sterile fashion. The inclination angle is manually opened to its maximum position (Fig. 1-2) and the stem is inserted into the humeral canal (Fig. 3). *Note: It is not necessary to adjust screws prior to implantation.*

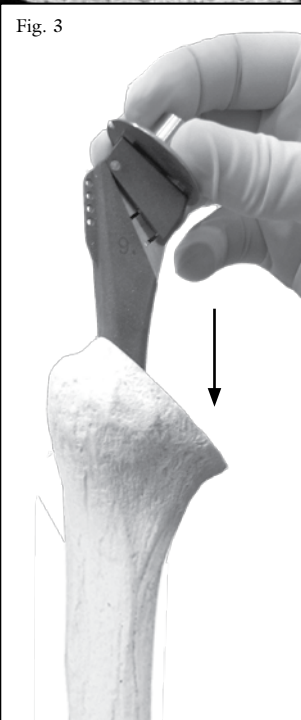
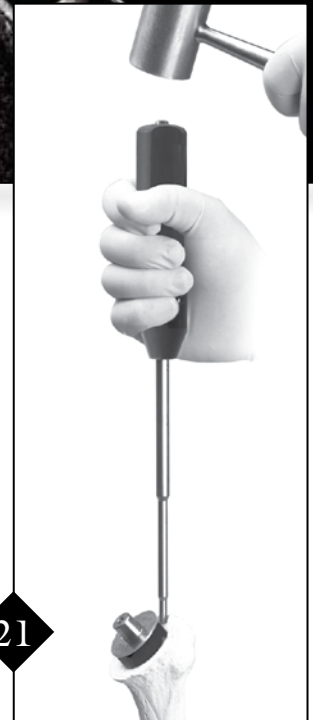
Fig. 3



21

The Pointed Stem Impactor is placed into the dimple on the lateral portion of the stem. The stem is impacted as far as possible. Change to the angled Morse Taper Stem Impactor (see step 22).

The angled Morse Taper Stem Impactor is placed over the Morse Taper and impaction is completed (Fig. 1). The inclination angle remains free while the stem is impacted into the humerus (Fig. 2). The inclination angle is established when the flange contacts the humeral surface and is fully seated. *Note: For cemented application, select a Humeral Stem one size smaller than the canal preparation. Perform steps 21 through 25. Remove the stem, place the cement into the canal and reinsert the stem. It may be necessary to use the Stem Impactors. Continue to step 26.*



Fig. 1



Fig. 2

22




23

Tighten the inferior locking screw located on the medial portion of the trunion. The inferior (inclination) locking screw should be locked before the superior (version) screw is locked.

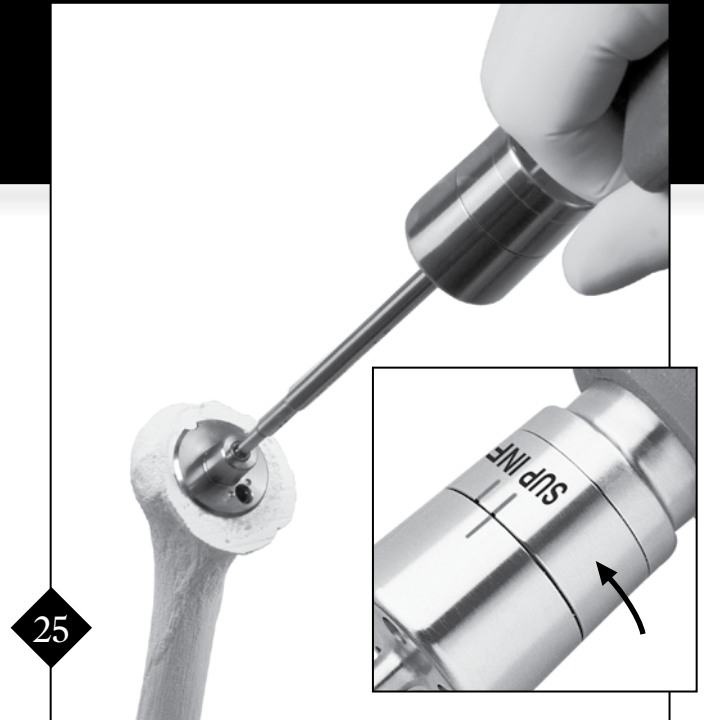
Note: This screw can be provisionally tightened with the standard hex driver, however, the Torque Driver must be used for final tightening (see step 24).

HUMERAL STEM IMPLANTATION



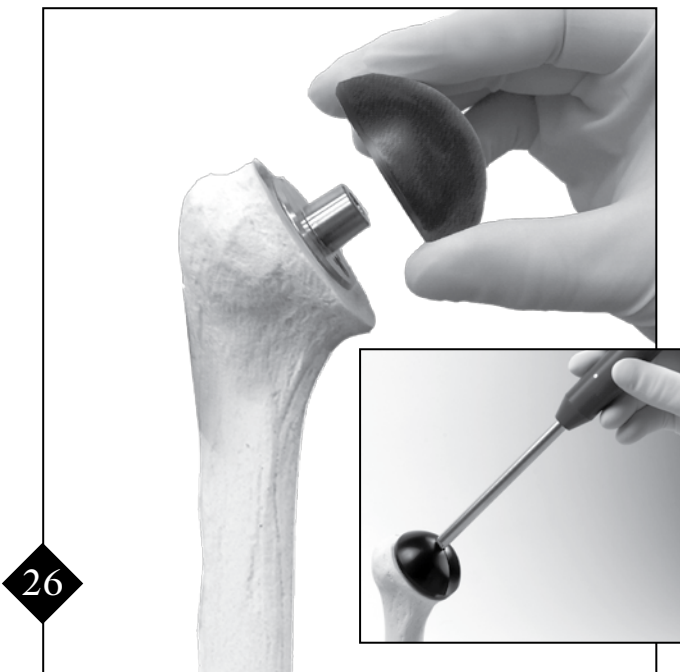
Ensure that the inclination (inferior) screw is properly tightened. This is accomplished by visually confirming that the “INF” mark is rotated to the indicator line on the Torque Driver.

Note: Care must be taken to ensure drivers are completely seated into the locking screws during tightening.

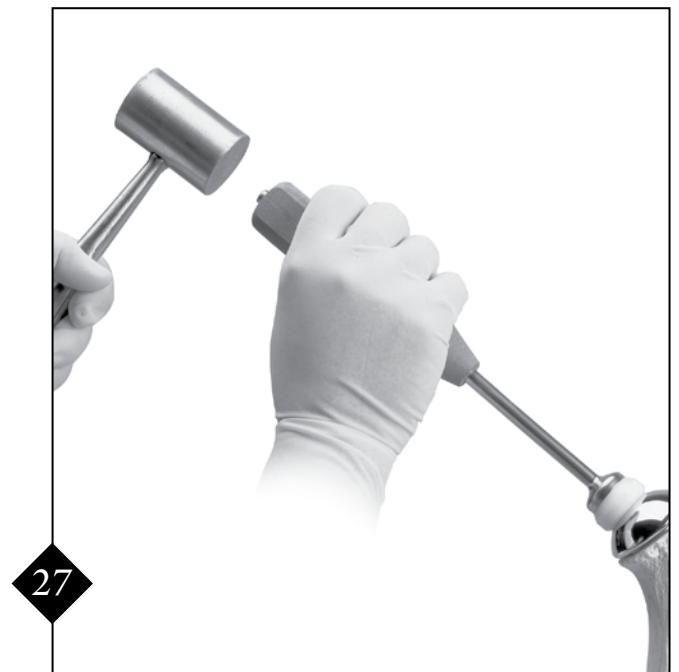

The Torque Driver is used to lock the version (superior) screw located on the Morse Taper of the humeral stem. Ensure that the set screw is properly tightened by visually confirming that the “SUP” mark is rotated to the indicator line on the Torque Driver.

Note: This screw can be provisionally tightened with the standard hex driver, however, the Torque Driver must be used for final tightening.



The appropriate Trial Head is attached and the Trial Driver is used to adjust offset. A trial reduction is performed. The position of maximum offset is designated by a line on the surface of the trial head.



After the trial reduction, the Trial Head is removed and an implant head is impacted onto the humeral stem using the Head Impactor.



WOUND CLOSURE

As described by Anthony Romeo, M.D., Rush University Medical Center, Chicago, IL

Prior to closure, stability and mobility should be assessed with the final implants in place. This can be accomplished intraoperatively using the “40-50-60” method: A stable 40° of external rotation with the arm in neutral position, 50% posterior translation with good “bounce-back”, and 60° of internal rotation with the arm in abduction.

Wound closure begins with thorough irrigation, removing any remaining soft tissue or bony debris. Hemostasis is obtained with electrocautery. The initial focus of wound closure is the repair of the subscapularis tendon. To ensure that the subscapularis tendon is repaired to its anatomic position, the first step of the repair is reattaching the superior lateral edge of the subscapularis to the anterior lateral edge of the supraspinatus directly over the bicipital groove. This is performed with #2 FiberWire sutures. By securing the superior lateral edge of the subscapularis at the beginning of the repair, the tendon is held in an anatomic position.

Four braided #5 FiberWire sutures which were placed at the rim of the osteotomy site are individually passed through the subscapularis tendon separated by approximately 1 cm. The sutures can be passed with a Mason-Allen configuration to improve security of the suture in the tendon. The sutures are tied beginning superiorly and proceeding inferiorly. Additional #2 FiberWire sutures are placed in between each of the #5 FiberWire sutures for a tendon-to-tendon repair, reattaching the subscapularis tendon to the remaining fibers in the lesser tuberosity. A total of eight sutures, four #2 FiberWire sutures for the tendon-to-tendon repair, and four #5 FiberWire sutures for a tendon-to-bone repair are used for a secure subscapularis repair. This will allow for an early range of motion program and minimize the risk of subscapularis rupture.

Hemostasis is assessed at this time and if excessive bleeding is found, a single hemovac wound drainage device is placed into the deep layer. The deltoid and pectoralis major muscle are repaired with a side-to-side closure using #1 absorbable suture. The subcutaneous layer is repaired with 2-0 interrupted absorbable suture and finally, a 3-0 suture is used for the skin closure. The skin closure is supported by steri-strips. If used, the hemovac drain is secured and suction is initiated. The drain is usually removed on the first postoperative day.



POSTOPERATIVE MANAGEMENT

As described by Anthony Romeo, M.D., Rush University Medical Center, Chicago, IL

The arm is placed in a sling supported by a form-fitting pillow with a waist strap, which immobilizes the upper extremity. Wrist, hand, and finger range of motion and grip strengthening begin on the evening of surgery. On the first day after surgery (postoperative day one), passive and active-assisted range of motion exercises are started. These activities will include pendulum exercises in a standing position, as well as assisted forward elevation exercises in a supine position with a limitation of 90°, which may be adjusted based on the intraoperative assessment by the surgeon. Active-assisted external rotation exercises in the supine position are allowed up to 20° of external rotation and again adjusted based on the surgeon's evaluation at the completion of the subscapularis repair. The focus of the rehabilitation program is to teach the patient exercises that they can conduct three to four times per day on their own. Assisted devices such as a pulley or a physical therapy baton can be valuable.

The patient is typically discharged 48 hours following the surgical procedure. Younger patients and patients undergoing a hemi-arthroplasty alone may be comfortable and independent within 24 hours. The rehabilitation goals upon discharge include a minimum of 90° of forward elevation and 20° of external rotation and successful education of the patient regarding their home exercise program.

Upon discharge, an outpatient physical therapy program is initiated. Active exercises are started 10-14 days after the surgical procedure. The major restriction to physical therapy, within the first six weeks, is prohibiting resisted internal rotation or other activities that would put stress on the subscapularis repair such as passive unprotected external rotation performed by the physical therapist. If the patient is allowed independent active-assisted external rotation, the subscapularis repair will not be jeopardized.

For the first six weeks the focus is on stretching and improving active range of motion. Once the subscapularis tendon has had adequate time to heal, at approximately six weeks, all range of motions including internal rotation are advanced as tolerated. Furthermore, the strengthening program is balanced to include both the anterior rotator cuff (subscapularis) and posterior rotator cuff (primarily supraspinatus and infraspinatus). Deltoid strengthening as well as scapular muscle strengthening (shoulder shrugs, scapular protraction, scapular retraction, rows, front pull downs) can be gradually incorporated into the patient's rehabilitation program. By three months, the patient should be independent with a rehabilitation program. They should be encouraged to pursue both the stretching and strengthening program throughout the entire first year following their shoulder arthroplasty procedure. Outcome analysis has clearly shown that patients will continue to improve with regards to strength and function for 18-24 months following shoulder arthroplasty.

The final result for an uncomplicated total shoulder arthroplasty when treating osteoarthritis should be an average forward elevation of greater than 140°, active external rotation of greater than 45°, and active internal rotation up behind the back to the T12 level or above. Strength should allow all activities of daily living as well as light recreational activities such as golf, light fitness training, household chores, gardening and swimming in select patients. The final weight-restriction based on theoretical concerns of prosthetic loosening includes no repetitive lifting activities greater than 20 pounds and no repetitive work activities at shoulder level or above on a routine basis.

Ordering Information

Univers II Glenoid Instrumentation	AR-9225S
Univers II Humeral Instrumentation	AR-9226S
Univers II Shoulder Head Resection Disposables Kit	AR-9206S

Univers Arthroplasty Systems Folder (LM0700) includes:

Univers II Total Shoulder System Surgical Technique	LT0701
Univers Shoulder Fracture System Surgical Technique	LT0700
Univers II X-ray Templates	LXT0701
<i>(surgical techniques and x-ray templates can also be ordered separately)</i>	
Univers II Technique Video	DVD-1101

Implants:

Humeral Stem, 6 mm x 115 mm	AR-9100-06P
Humeral Stem, 7 mm x 140 mm	AR-9100-07P
Humeral Stem, 8 mm x 143 mm	AR-9100-08P
Humeral Stem, 9 mm x 146 mm	AR-9100-09P
Humeral Stem, 10 mm x 148 mm	AR-9100-10P
Humeral Stem, 11 mm x 151 mm	AR-9100-11P
Humeral Stem, 12 mm x 151 mm	AR-9100-12P
Humeral Stem, 13 mm x 151 mm	AR-9100-13P
Humeral Stem, 14 mm x 151 mm <i>(available upon request)</i>	AR-9100-14P
Humeral Stem, 15 mm x 151 mm <i>(available upon request)</i>	AR-9100-15P

Keeled Glenoid, cemented, small	AR-9104-01
Keeled Glenoid, cemented, medium	AR-9104-02
Keeled Glenoid, cemented, large	AR-9104-03
Pegged Glenoid, cemented, small	AR-9105-01
Pegged Glenoid, cemented, medium	AR-9105-02
Pegged Glenoid, cemented, large	AR-9105-03

Humeral Head, 40 mm x 17 mm	AR-9140-17P
Humeral Head, 42 mm x 17 mm	AR-9142-17P
Humeral Head, 44 mm x 17 mm	AR-9144-17P
Humeral Head, 44 mm x 19 mm	AR-9144-19P
Humeral Head, 46 mm x 18 mm	AR-9146-18P
Humeral Head, 46 mm x 20 mm	AR-9146-20P
Humeral Head, 48 mm x 19 mm	AR-9148-19P
Humeral Head, 48 mm x 21 mm	AR-9148-21P
Humeral Head, 50 mm x 19 mm	AR-9150-19P
Humeral Head, 50 mm x 21 mm	AR-9150-21P
Humeral Head, 52 mm x 20 mm	AR-9152-20P
Humeral Head, 52 mm x 22 mm	AR-9152-22P
Humeral Head, 54 mm x 21 mm	AR-9154-21P
Humeral Head, 54 mm x 23 mm	AR-9154-23P


Accessories:

#2 FiberWire, 38 inches (blue) w/Tapered Needle, 26.5 mm, 1/2 circle, qty. 12	AR-7200
#2 FiberWire, 38 inches w/Reverse Cutting Needle, 36.6 mm, 1/2 circle, qty. 12	AR-7202
#5 FiberWire, 38 inches (blue)	AR-7210
#5 FiberWire, 38 inches w/Conventional Cutting Needle, 48 mm, 1/2 circle, qty. 12	AR-7211
FiberWire Suture Kit	AR-7219

HUMERAL INSTRUMENTATION (AR-9226S)

Bone Preparation (AR-9226C-1) - Base Tray


- 1 Humeral Broaches, 6 mm - 13 mm
- 2 Slap Hammer



AR-9226C-1 BASE TRAY

Bone Preparation (AR-9226C-1) - Top Tray


- 1 Humeral Resection Guides
- 2 Reamer T-Handle
- 3 Broach Alignment Guide
- 4 Resection Guide Version Rods
- 5 6 mm Humeral Reamer
- 6 7 mm Humeral Reamer



AR-9226C-1 TOP TRAY

Implant Preparation (AR-9226C-2) - Base Tray


- 1 Pointed Stem Impactor
- 2 Stem Impactor - Morse Taper
- 3 Head Impactor
- 4 Hex Driver
- 5 Trial Head Driver
- 6 Torque Driver
- 7 Trunion Extractor
- 8 Head Extractor
- 9 Stem Extraction Block



AR-9226C-2 BASE TRAY

Implant Preparation (AR-9226C-2) - Top Tray


- 1 Humeral Stem Trials, 6 mm - 13 mm
- 2 Humeral Head Trials
- 3 Resection Protectors for Trial Stems
- 4 Resection Protectors
- 5 Trial Trunion



AR-9226C-2 TOP TRAY

KEELED GLENOID INSTRUMENTATION (AR-9225S)


- 1 Glenoid Reamers - S, M, L
- 2 Glove Protector - Glenoid Reamer Shaft
- 3 Keeled Glenoid Trials - S, M, L
- 4 Glenoid Drill Guide #1 - S, M, L
- 5 Keeled Glenoid Drill Guide #2 - S, M, L
- 6 Posterior Glenoid Retractor
- 7 Glenoid Reamer Shaft
- 8 Glenoid Impactor
- 9 Keel Punch
- 10 Angled Glenoid Reamer Shaft
- 11 6 mm Drill
- 12 Drill Guide Handle
- 13 Glove Protector - 6 mm Drill
- 14 6 mm Quick Release Drill, Short



AR-9225S

PEGGED GLENOID INSTRUMENTATION (AR-9237S)

- 1 Pegged Glenoid Trials - S, M, L
- 2 Pegged Glenoid Drill Guide #2 - S, M, L
- 3 4.5 mm Quick Release Drill
- 4 Glenoid Trial Forceps
- 5 Pegged Glenoid Broach
- 6 Pegged Glenoid Punch
- 7 Pegged Glenoid Cement Pressurizer
- 8 Extended Shaft Glenoid Reamers - S, M, L
- 9 6 mm Quick Release Drill, Long



AR-9237S

Glenoid Sizing Matrix (Mismatch)

<i>Humeral Head (Radius of Curvature)</i>	<i>Small</i>	<i>Medium</i>	<i>Large</i>
40/17 (20.5 mm)	8.5		
42/17 (21.5 mm)	7.5		
44/17 (22.6 mm)	6.4	7.9	
44/19 (22.6 mm)	6.4	7.9	
46/18 (23.7 mm)		6.8	
46/20 (23.7 mm)		6.8	
48/19 (24.8 mm)		5.7	7.2
48/21 (24.8 mm)		5.7	7.2
50/19 (25.9 mm)		4.6	6.1
50/21 (25.9 mm)		4.6	6.1
52/20 (26.7 mm)			5.3
52/22 (26.7 mm)			5.3
54/21 (28 mm)			4
54/23 (28 mm)			4


Note: Gray shading corresponds with black trials (2nd head height) in the instrument set



This description of technique is provided as an educational tool and clinical aid to assist properly licensed medical professionals in the usage of specific Arthrex products. As part of this professional usage, the medical professional must use their professional judgment in making any final determinations in product usage and technique. In doing so, the medical professional should rely on their own training and experience and should conduct a thorough review of pertinent medical literature and the product's Directions For Use.

Arthrex® 

www.arthrex.com

...up-to-date technology
just a click away 

*This surgical technique has been developed in cooperation with
Anthony Romeo, M.D., Rush University Medical Center, Chicago, IL.*

U.S. PATENT NO. 6,716,234; 7,204,854 and PATENTS PENDING.

© 2009, Arthrex Inc. All rights reserved. LT0701G