

NOTICE WARNING CONCERNING COPYRIGHT RESTRICTIONS

The copyright law of the United States [Title 17, United States Code] governs the making of photocopies or other reproductions of copyrighted material

Under certain conditions specified in the law, libraries and archives are authorized to furnish a photocopy or other reproduction. One of these specified conditions is that the reproduction is not to be used for any purpose other than private study, scholarship, or research. If a user makes a request for, or later uses, a photocopy or reproduction for purposes in excess of "fair use," that use may be liable for copyright infringement.

This institution reserves the right to refuse to accept a copying order if, in its judgement, fulfillment of the order would involve violation of copyright law. No further reproduction and distribution of this copy is permitted by transmission or any other means.



Request # 2936676

APR 23, 2001

Email (PDF) To: colleyp@home.com

Peter Colley
3811 NE 41st St.
Seattle, WA 98105

042508

LOANSOME DOC: Journal Copy Affiliated

Title: Anesthesia and analgesia.
 Title Abbrev: Anesth Analg
 Citation: 1999 Nov;89(5):1292-5
 Article: Teaching the use of fiberoptic intubation in anesthetized, s
 Author: Erb T; Hampf KF; Schurch M; Kern CG; Marsch SC;
 NLM Unique ID: 1310650 ISSN: 0003-2999
 PubMed UI: 10553854
 Holding: Library reports holding vol/yr
 Need By: N/A
 DOCLINE: Yes
 Patron UserID: PCOLLEY
 Phone: 1.206.525-7534
 Comments: Deliver via PDF, UW Faculty, Anesthesiology, Grant #
 63-5503(xx515u)
 Received: 24-Apr-01 09:00 AM
 Lender: University of Washington Health Sciences Library/ Seattle/ WA
 USA (WAUWAS)

PDF

This material may be protected by copyright law (TITLE 17,U.S. CODE)

Teaching the Use of Fiberoptic Intubation in Anesthetized, Spontaneously Breathing Patients

Thomas Erb, MD, Karl F. Hampl, MD, Moritz Schürch, MD, Christian G. Kern, MD, and Stephan C. U. Marsch, MD, DPhil

Department of Anesthesia, University of Basel/Kantonsspital, Basel, Switzerland

In patients with difficult airways, the standard of care involves fiberoptic intubation under spontaneous ventilation. However, the safety and feasibility of a fiberoptic intubation teaching program has only been documented in paralyzed and apneic patients, whereas data obtained in patients under spontaneous respiration are limited and conflicting. We evaluated 100 anesthetized patients undergoing orotracheal fiberoptic intubation. Five anesthesia residents with no prior experience in fiberoptic laryngoscopy participated in the study. In a randomized fashion, each participant tracheally intubated 10 spontaneously breathing patients (Group A: sevoflurane anesthesia via an airway endoscopy mask) and 10 paralyzed patients (Group B: total IV anesthesia with propofol, fentanyl, atracurium). Overall rate of success (96%), defined as successful intubation of the trachea within two attempts, was not different between

groups. During fiberoptic intubation, SpO_2 values remained >95% in Group A, whereas SpO_2 decreased to <95% in two patients in Group B. Failure to pass the tube into the trachea over the bronchoscope was encountered in four patients in Group A and in no patient in Group B. Our data suggest that it is safe to teach the use of fiberoptic intubation in anesthetized, spontaneously breathing patients with normal airway anatomy. **Implications:** Fiberoptic intubation under spontaneous respiration is a well established technique for management of difficult airways. Our study demonstrates the feasibility and safety of a novice training program for fiberoptic intubation under general anesthesia, not only in paralyzed patients but also in those breathing spontaneously.

(Anesth Analg 1999;89:1292-5)

The development of skills in fiberoptic intubation (FOI) is recognized as an essential part of anesthetic training because it is an important technique for airway management (1-3). Previous work in anesthetized and paralyzed subjects showed that FOI training can be successfully accomplished without overt patient disadvantage (4-7). However, data on the safety of similar training programs on anesthetized patients breathing spontaneously are limited, and some suggest that this approach may be associated with an increased incidence of hypoxemia (8,9). This is of concern because FOI may be necessary in spontaneously breathing patients under certain clinical conditions, in particular, in patients with compromised airways. Therefore, a training program providing opportunities to acquire skills in FOI in spontaneously breathing patients is highly desirable. Accordingly, we sought to determine the feasibility and

safety of a FOI training program in patients breathing spontaneously under general anesthesia with sevoflurane while comparing this technique with a technique with well established safety, i.e., in paralyzed patients under total IV anesthesia (4,7,10,11).

Methods

After institutional approval and written, informed consent, 100 surgical patients were prospectively studied. All patients were ASA physical status I or II and were not expected to present difficult intubation. Patients with morbid obesity or increased risk for aspiration of gastric fluid were excluded.

Five residents in their first or second year of anesthesia training participated in the study. None of the study participants had any previous experience in fiberoptic airway instrumentation. Before the start of the study, all participants completed a short structured fiberoptic training program as follows: First, an instructional videotape, demonstrating both handling of the instrument and various FOI techniques, was shown to the trainees. Second, the trainees received

Accepted for publication June 29, 1999.

Presented in part at the Annual Meeting of the American Society of Anesthesiologists, Orlando, FL, October 17-21, 1998.

Address correspondence and reprint requests to Thomas Erb, MD, Department of Anesthesiology, Duke University Medical Center, PO Box 3094, Durham, NC 27710. Address e-mail to ERB00003@mc.duke.edu.

the opportunity to practice FOI on an intubation mannequin with and without airway endoscopy mask (VBM, Sulz am Neckar, Germany) (12) under the supervision of an instructor.

A block-randomization was used to assign each trainee 10 spontaneously breathing patients (Group A: sevoflurane anesthesia via an airway endoscopy mask) and 10 paralyzed apneic patients (Group B: total IV anesthesia and full neuromuscular blockade) in a randomized order.

Oral premedication consisted of ranitidin 300 mg the night before and midazolam 7.5 mg 1 h before the start of anesthesia. Routine monitoring was used. In Group A, the pharynx was sprayed with 4-6 puffs of lidocaine aerosol. Then, inhaled induction of anesthesia was started with sevoflurane 8% in 100% oxygen (fresh gas flow 6 L/min) via an airway endoscopy mask. After 3 min, the inspiratory concentration of sevoflurane was reduced to 5%. An Ovassapian fiberoptic intubating airway (Kendall, Irvine, CA) was inserted as soon as deemed appropriate (13). Depth of anesthesia was assessed and was considered adequate for FOI when pupils were miotic, no eyeball activity was noted, and when a vigorous anterior displacement of the mandible did not evoke a motor response. The bronchoscope was then inserted through the silicon membrane of the endoscopy mask. When the tip of the bronchoscope was positioned immediately above the epiglottis, topical anesthesia of the larynx was applied through the suction channel of the bronchoscope using 2 mL of lidocaine 4%. Advancement of the fiberscope into the trachea was withheld for 60 s to allow for the drug's anesthetic effect.

In Group B, all patients received lidocaine 30 mg IV in an attempt to blunt pain on injection of propofol. Anesthesia was induced with fentanyl 3 $\mu\text{g}/\text{kg}$ and propofol 1 mg/kg IV. Anesthesia was maintained with continuous infusion of propofol 10 mg \cdot kg⁻¹ \cdot h⁻¹. Muscle relaxation was performed with atracurium 0.5 mg/kg, and the lungs were manually ventilated with 100% O₂ via a regular face mask.

In both groups, fiberoptic airway instrumentation was performed with the patient's mandible anteriorly dislocated at the temporomandibular joint by the supervisor in order to open the retropharyngeal space. A plastic endotracheal tube, size 7.5, attached to a Olympus BF P20D fiberbronchoscope (Olympus Optical Company, Tokyo, Japan) was used in all patients. Duration of intubation was defined as the time from introducing the bronchoscope into the patient's mouth until end-tidal carbon dioxide was recorded after resumption of ventilation via endotracheal tube.

Inhaled induction under spontaneous ventilation or intubation attempts were discontinued if SpO₂ decreased below 95%; in this case, patients were ventilated manually via face mask for 3 min before the next attempt. If

the trainee failed to intubate within two attempts, the patient's trachea was intubated by the supervisor.

Postoperatively, patients were asked for side effects of tracheal intubations, such as sore throat.

Data were analyzed using the χ^2 test or Fisher's exact test, and the unpaired Student's *t*-test, as appropriate. Time to complete intubation was further analyzed using the log-rank (Mantel-Cox) test and, in addition, comparing the first five intubations with the subsequent intubations within each group using the Wilcoxon's rank sum test. A *P* value of <0.05 was considered significant.

Results

Demographic data did not differ between study groups (Table 1). In Group A, one patient had to be excluded because of a laryngospasm during induction requiring treatment with a muscle relaxant.

The number of successful intubations at first attempt and overall success rate are shown in Table 2. In Group A, seven patients could not be intubated on the first attempt: in four patients, the tube could not be passed over the bronchoscope into the trachea despite successful intubation of the trachea with the fiberbronchoscope. In two patients, an inadvertent esophageal intubation was performed, and, in one case, the trainee abandoned FOI during the first attempt because he felt uncomfortable and, therefore, left FOI to the instructor. FOI was successfully accomplished by the trainees at the second attempt in five patients. In one patient, the trainee again failed to pass the tube over the bronchoscope into the trachea; however, the supervisor had no difficulty performing this maneuver. In Group B, two patients could not be intubated at first attempt: in one patient the oxygen saturation (SpO₂) decreased to <95%, whereas in the other patient the esophagus was inadvertently intubated. Although the trainees also failed to intubate these patients at the second attempt, both patients were subsequently tracheally intubated fiberoptically by the supervisor without difficulty.

The duration of intubation is shown in Table 2 and Figure 1. In both groups, individual median time required to accomplish FOI was significantly longer for the first five intubations as compared with the second five intubations: Group A, 185 vs 144 s (*P* > 0.05); and Group B; 104 vs 64 s (*P* > 0.01). SpO₂ and ETco₂ after intubation and the incidence of coughing are shown in Table 2.

Patients complained significantly more about postoperative sore throat in Group A than in Group B (15 vs 6 patients, *P* < 0.05).

Discussion

The feasibility and safety of a fiberoptic orotracheal intubation training program has been demonstrated

Table 1. Demographic Data

	Group A (n = 50)	Group B (n = 50)
Age (yr)	40.8 ± 11.4	37.6 ± 10.7
Weight (kg)	70.2 ± 10.8	65.4 ± 10.7
Height (cm)	169.0 ± 6.7	168.2 ± 6.9
Gender (M/F)	26/24	28/22

Values are mean ± SD or n.
Group A = spontaneously breathing patients, Group B = apneic, paralyzed patients.
There are no significant differences among the groups.

Table 2. Characteristics of fiberoptic intubation

	Group A (n = 49)	Group B (n = 50)
Intubation at first attempt	42 (86%)	48 (96%)
Overall success rate	47 (96%)	48 (96%)
Duration (sec)	215 ± 90†	95 ± 34
Spo ₂ (%)	98.4 ± 0.7*	99.1 ± 0.8
ETco ₂ (mm Hg)	40 ± 5†	35 ± 4
Spo ₂ < 95%	0	2
Coughing during endoscopy	15 (31%)†	0
Coughing during intubation	6 (12%)*	0

Values are mean ± SD or n (%).
Group A = spontaneously breathing patients, group B = apneic, paralyzed patients.
* P < 0.01.
† P < 0.001.

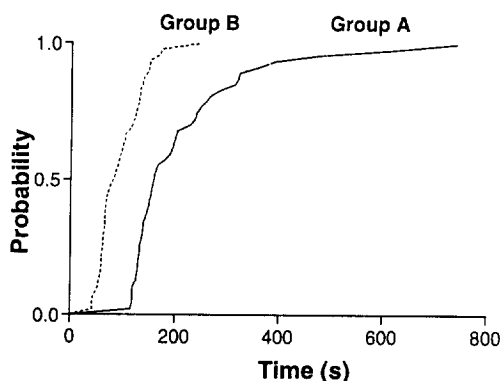


Figure 1. Survival curves for the two modes of intubation. Probability refers to the fractional probability of successful intubation. There was a highly significant difference between the two groups ($P < 0.001$, log-rank test). Group A = spontaneously breathing patients, Group B = apneic, paralyzed patients.

previously in anesthetized and paralyzed patients (4,5,7). As an alternative approach, Smith et al. (9) suggested FOI in anesthetized spontaneously breathing patients. With this technique, time to perform FOI is not restricted by apnea, a fact which may be particularly advantageous in patients with a difficult airway. Therefore, it appears to be desirable to perform a fiberoptic training program not only in paralyzed patients but also in patients breathing spontaneously (14). This may allow for a more useful training experience by providing a more realistic model for patients with a difficult airway (15).

However, available data on FOI under spontaneous respiration are limited. Smith et al. (9) reported desaturation episodes (Spo₂ < 90%) with an incidence as high as 30% in patients with expected difficult intubation when breathing halothane and nitrous oxide in 50% oxygen via a Mathias oral airway. Furthermore, in that study, desaturation episodes were associated with difficulties in maintaining a patent airway and, as a result, in maintaining an adequate depth of anesthesia.

In our study, fiberoptic airway instrumentation never had to be interrupted because of hypoxemia (Spo₂ < 95%) in Group A. We suggest that this favorable outcome compared with previous studies (8,9) may, at least in part, result from differences in airway management. First, we used a specifically designed

airway endoscopy mask that fits tightly to the patient's face and, therefore, not only enables the administration of 100% oxygen during fiberoptic airway instrumentation but also prevents loss of anesthetic gases (12). Second, we used sevoflurane as an anesthetic whose physicochemical properties, along with lack of pungency, allows a rapid and smooth induction when delivered via a face mask (16). Third, the use of topical anesthesia in Group A may have contributed to a more profound blunting of airway reflexes in nonparalyzed patients. Fourth, our patients had normal airway anatomy, whereas Smith et al. (9) studied individuals with predicted difficult intubation. Of note, however, 17/18 patients in Smith et al.'s study with hypoxemic episodes (Spo₂ < 90%) presented a glottic visible at Cormack and Lehane grade I or II at direct laryngoscopy (17), which suggests that abnormal airway anatomy was not a major contributing factor in the development of hypoxemia in these patients. Finally, our patients received 100% oxygen, via a face mask, a fact which might have improved a patient's tolerance for possibly inadequate alveolar ventilation during airway instrumentation.

The overall percentage of successful intubation by our novices in FOI was high (Table 2). Nonetheless, the time necessary to perform successful intubation decreased with an increasing number of FOIs in both groups, thereby demonstrating a significant learning effect. Duration of intubation was increased in Group A (Figure 1) and reflects, in part, the time needed to apply local anesthetics through the bronchoscope and the delay of 60 seconds to allow for the desired drug effect. In addition, coughing and, more important, time to overcome impingement of the tube on the larynx accounts for prolonged FOI in certain subjects. However, we suggest that this had no untoward effect on patients' safety in Group A because all patients in this study were at low risk of regurgitation and, furthermore, none of the patients in this group sustained critical decreases in Spo₂ values (Table 2).

In conclusion, in addition to a fiberoptic training program in apneic patients, a training program with spontaneously breathing patients may allow the acquisition of additional skills required when dealing with awake patients with difficult airways. Our data suggest that such a training program can be safely performed without significant untoward effects to spontaneously breathing patients under general anesthesia with sevoflurane. However, we emphasize the fact that our data cannot be extrapolated to patients with difficult airways, although the successful use of sevoflurane anesthesia has been reported in small number of such patients (18,19). Therefore, further studies are required to demonstrate the safety and feasibility of FOI of patients with difficult airways under general anesthesia.

References

1. Mason RA. Learning fiberoptic intubation: fundamental problems. *Anaesthesia* 1992;47:729-31.
2. Vaughan RS. Training in fiberoptic laryngoscopy. *Br J Anaesth* 1991;66:538-40.
3. Morris IR. Fiberoptic intubation. *Can J Anaesth* 1994;41:996-1007.
4. Cole AFD, Mallon JS, Rolbin SH, et al. Fiberoptic intubation using anesthetized paralyzed, apneic patients. *Anesthesiology* 1996;84:1101-6.
5. Erb T, Marsch SC, Hampl KF, et al. Teaching the use of fiberoptic intubation for children older than two years of age. *Anesth Analg* 1997;85:1037-41.
6. Smith JE, Jackson AP, Hurdley J, et al. Learning curves for fiberoptic nasotracheal intubation when using the endoscopic video camera. *Anaesthesia* 1997;52:101-6.
7. Schaefer HG, Marsch SC, Keller HL, et al. Teaching fiberoptic intubation in anaesthetised patients. *Anaesthesia* 1994;49:331-4.
8. Wrigley SR, Black AE, Sidhu VS. A fiberoptic laryngoscope for paediatric anaesthesia: a study to evaluate the use of the 2.2 mm Olympus (LF-P) intubating fibroscope. *Anaesthesia* 1995;50:709-12.
9. Smith M, Calder I, Crockard A, et al. Oxygen saturation and cardiovascular changes during fiberoptic intubation under general anaesthesia. *Anaesthesia* 1992;47:158-61.
10. Schaefer HG, Marsch SC, Strebel SP, et al. Cardiovascular effects of fiberoptic oral intubation: a comparison of a total intravenous and a balanced volatile technique. *Anaesthesia* 1992;47:1034-6.
11. Schaefer HG, Marsch SC. Comparison of orthodox with fiberoptic orotracheal intubation under total i.v. anaesthesia. *Br J Anaesth* 1991;66:608-10.
12. Frei FJ, Wengen DF, Rutishauser M, et al. The airway endoscopy mask: useful device for fiberoptic evaluation and intubation of the paediatric airway. *Paediatr Anaesth* 1995;5:319-24.
13. Ovassapian A. Fiberoptic tracheal intubation in adults. In: Ovassapian A, ed. *Fiberoptic endoscopy and the difficult airway*. Philadelphia: Lippincott-Raven, 1996:71-103.
14. Sidhu V, Wrigley S, Black A. Ultrathin fiberoptic laryngoscope. *Can J Anaesth* 1995;42:747.
15. Cormier S, Hagman J. *Transfer of learning*. New York: Academic Press, 1987.
16. Muzi M, Robinson BJ, Ebert TJ, et al. Induction of anesthesia and tracheal intubation with sevoflurane in adults. *Anesthesiology* 1996;85:536-43.
17. Cormack RS, Lehane J. Difficult tracheal intubation in obstetrics. *Anaesthesia* 1984;39:1105-11.
18. Mostafa SM, Atherton AM. Sevoflurane for difficult tracheal intubation. *Br J Anaesth* 1997;79:392-3.
19. Watters MP, McKenzie JM. Inhalational induction with sevoflurane in an adult with severe complex central airways obstruction. *Anaesth Intensive Care* 1997;25:704-6.