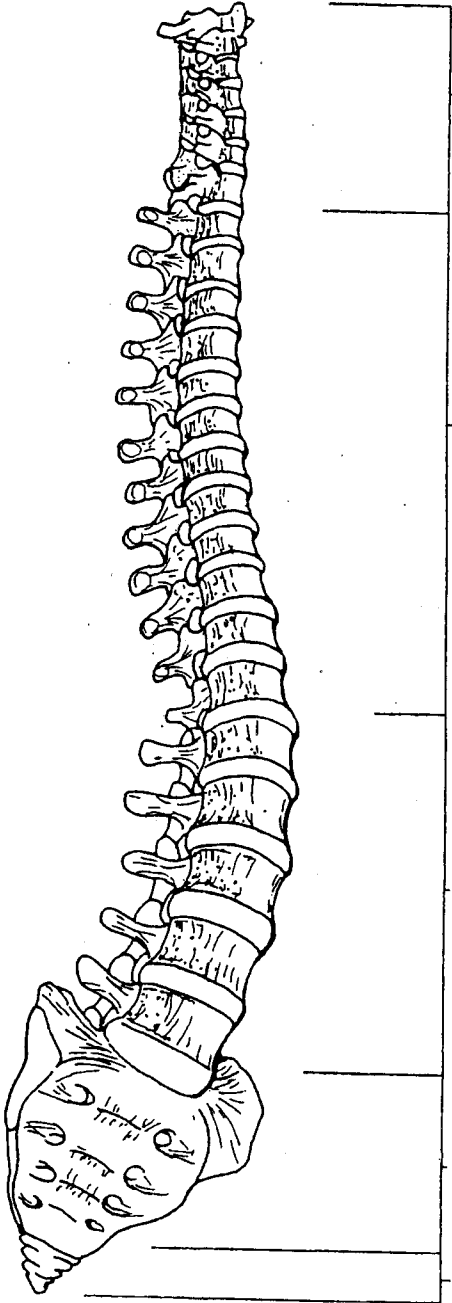
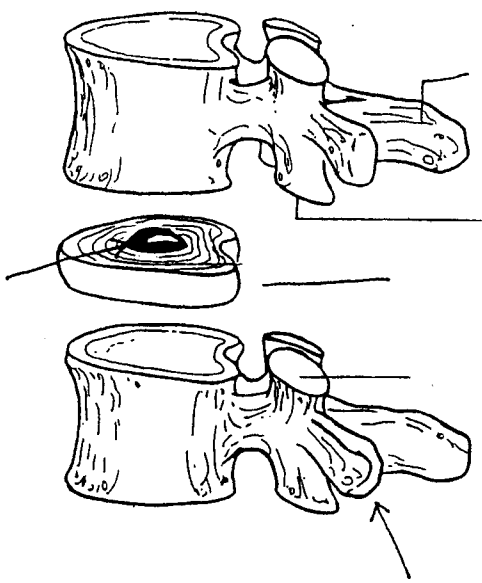
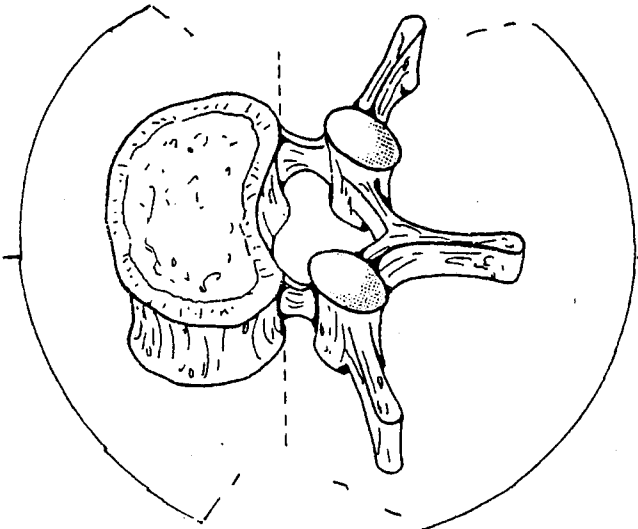
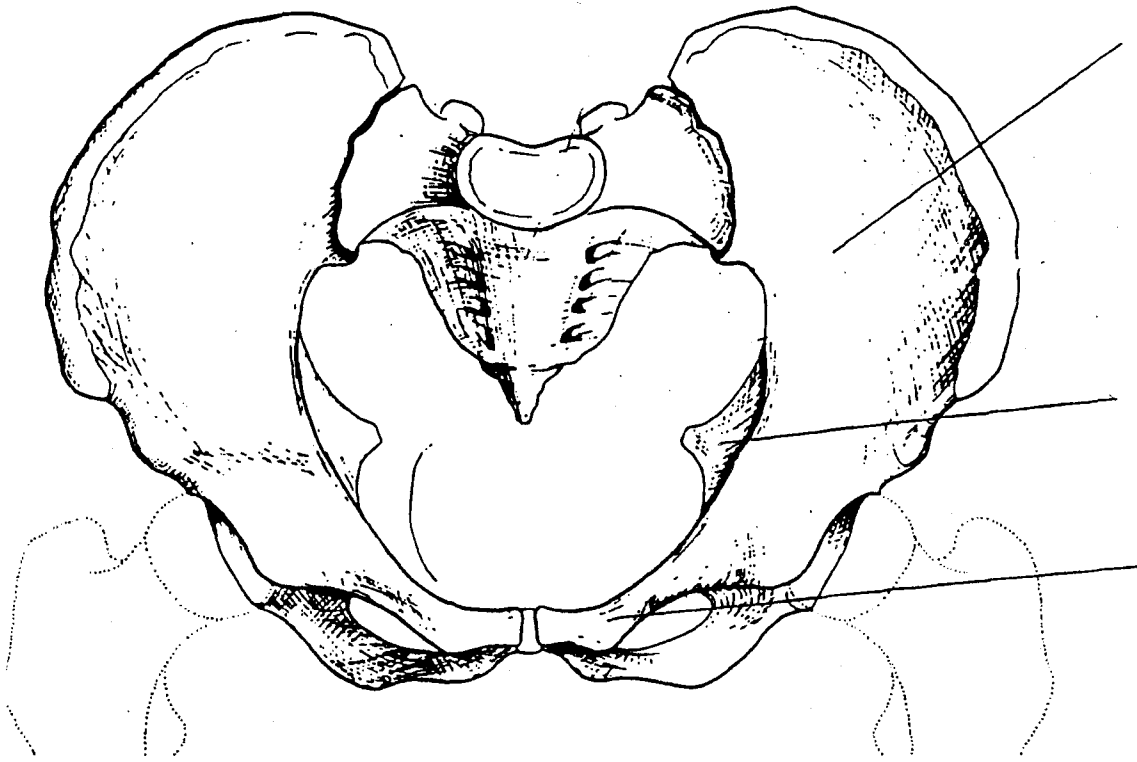


REGIONS OF THE SPINE




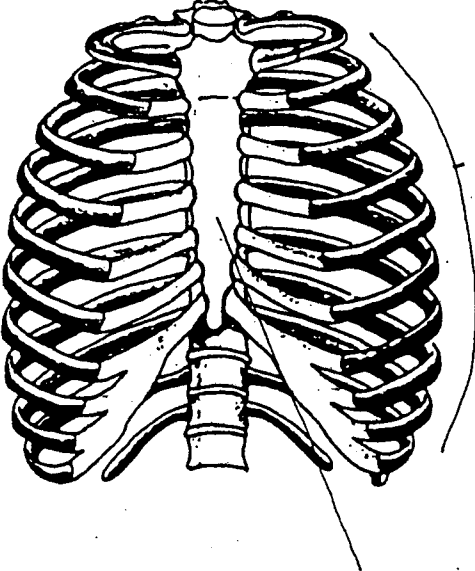
BONY LANDMARKS OF THE SPINE



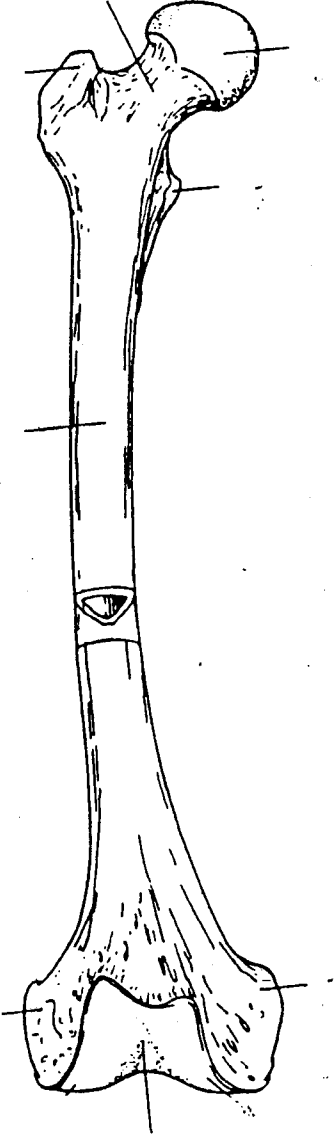
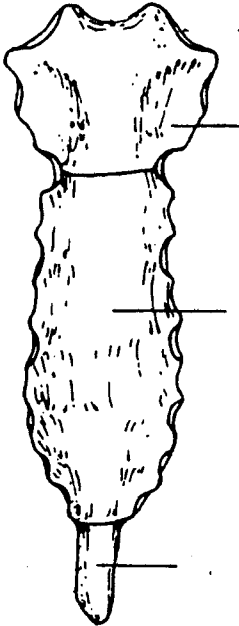


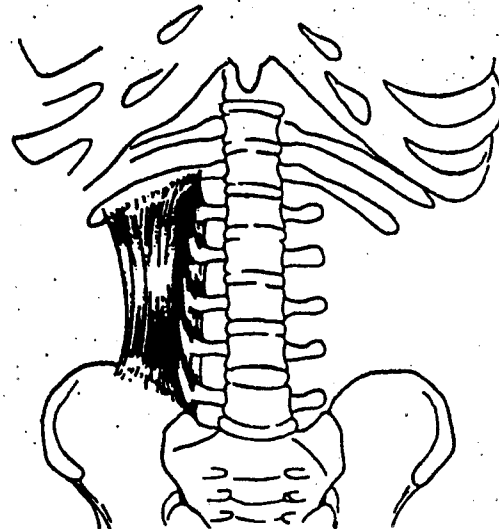
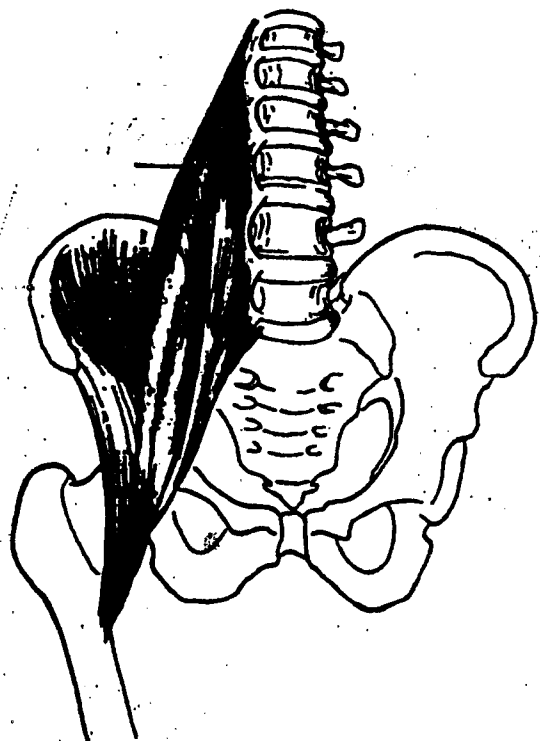
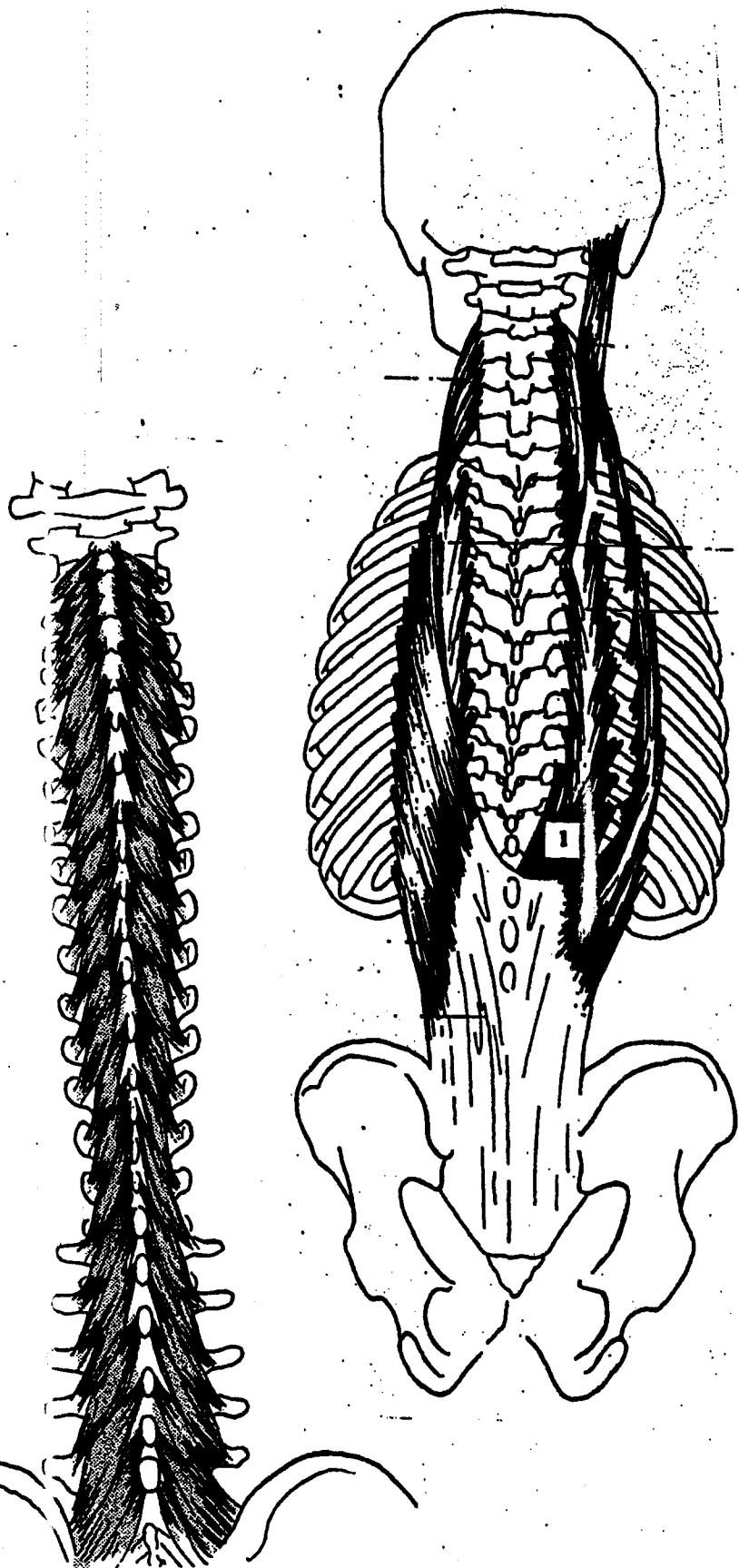
PELVIC LANDMARKS



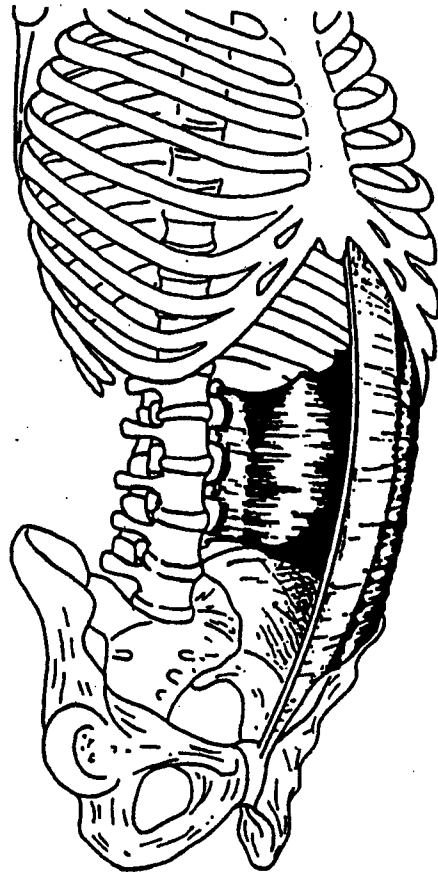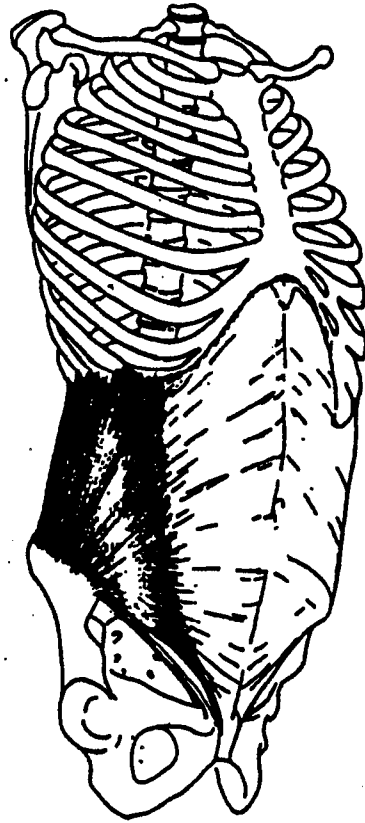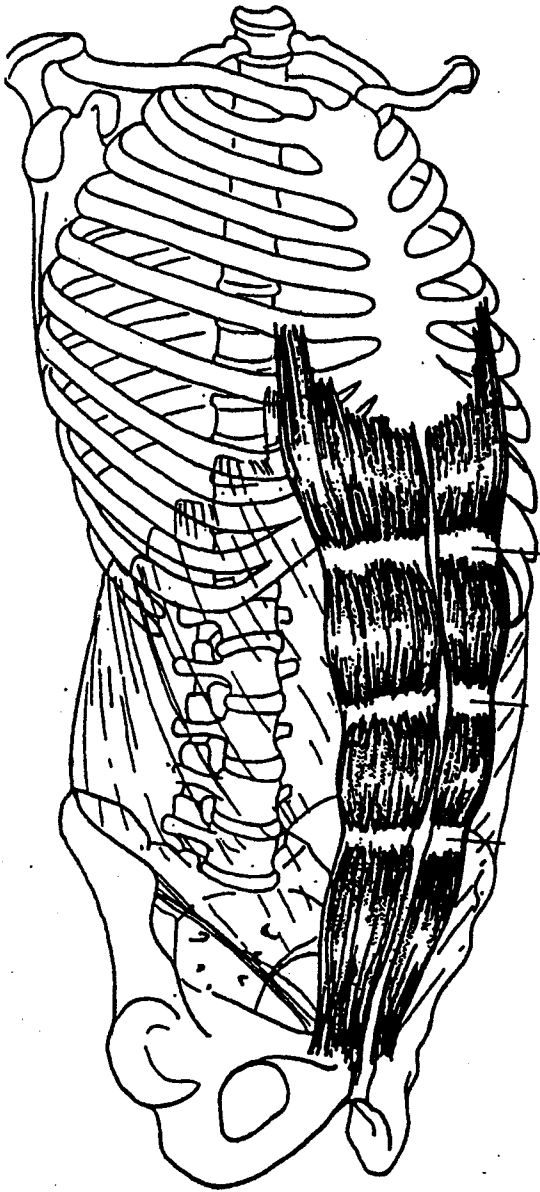


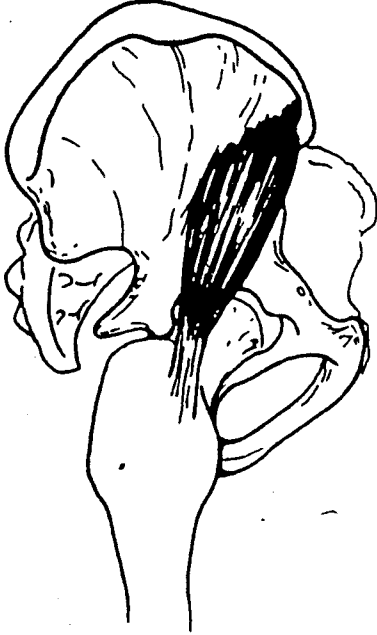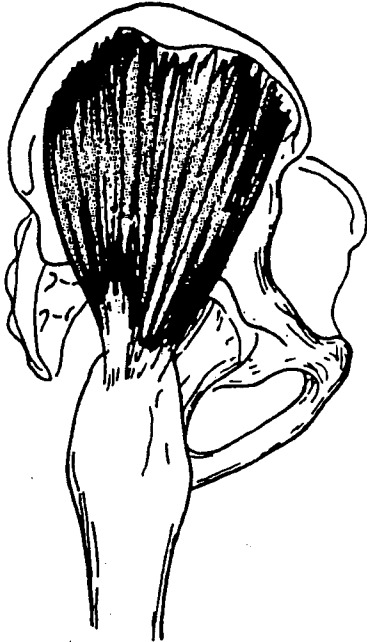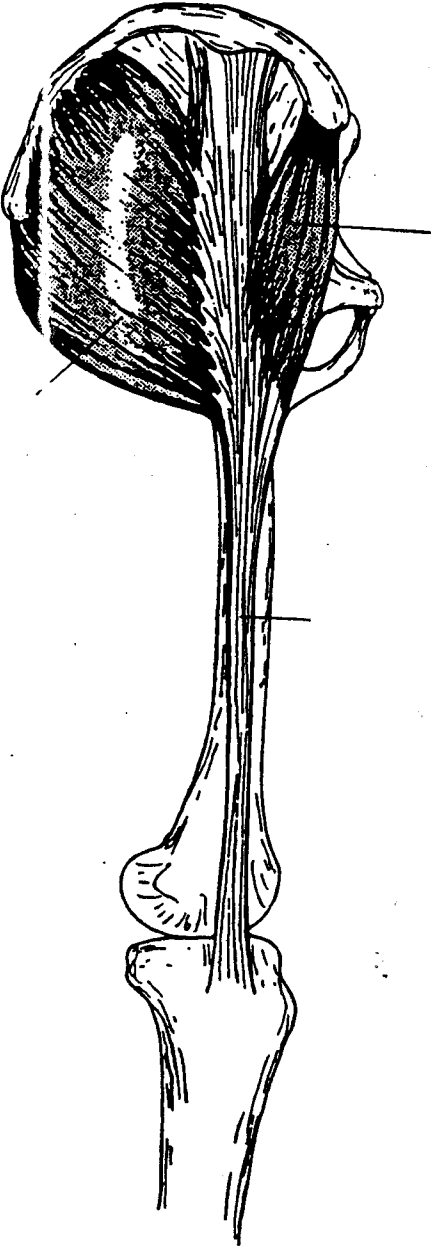
BONE PARTS



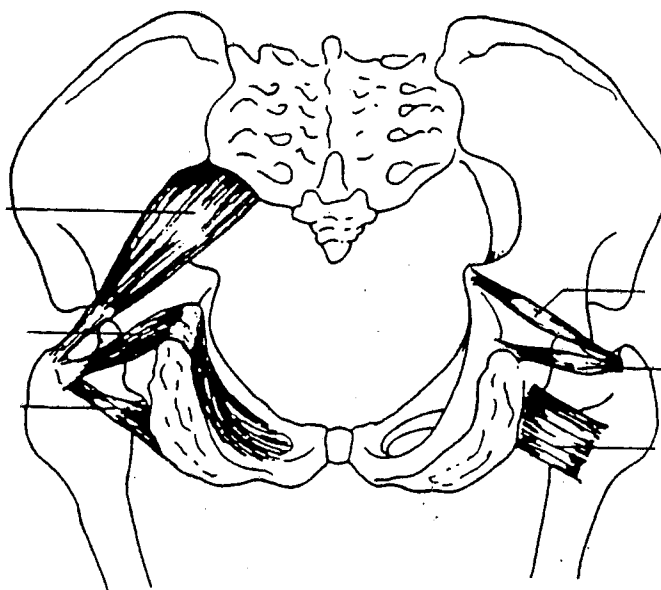


MUSCLES OF ABDOMEN

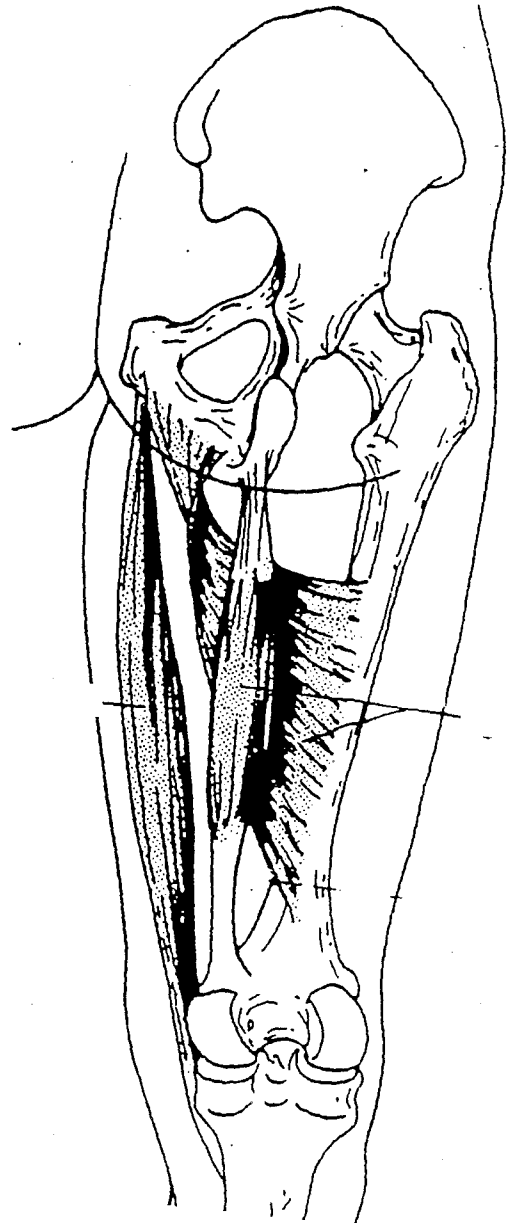
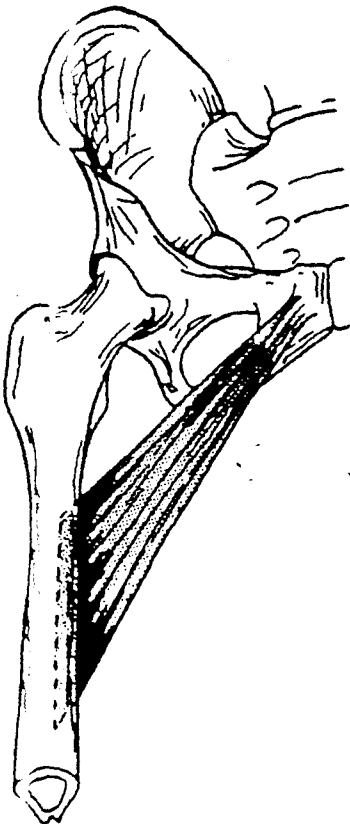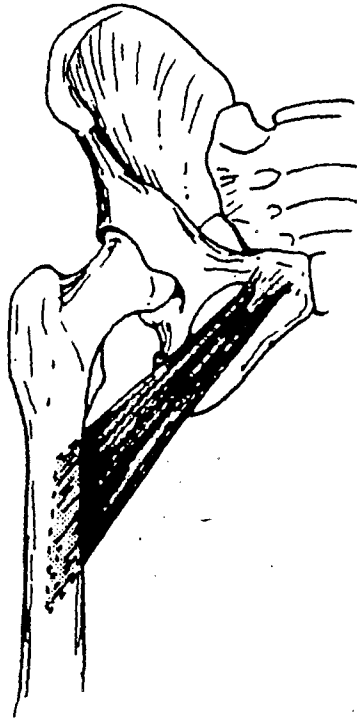
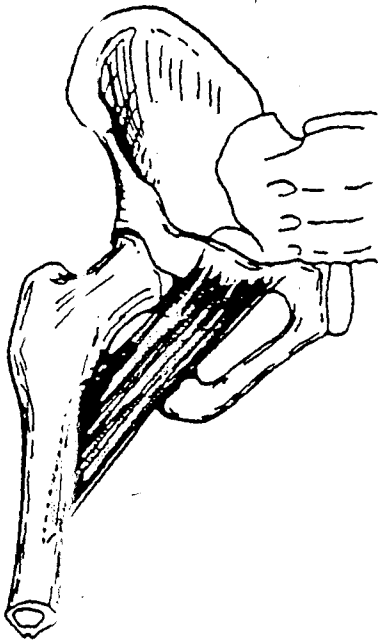




EXTERNAL ROTATORS

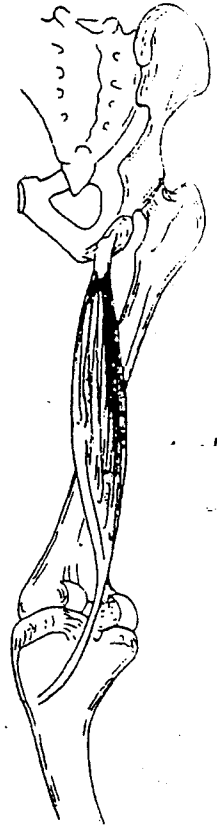
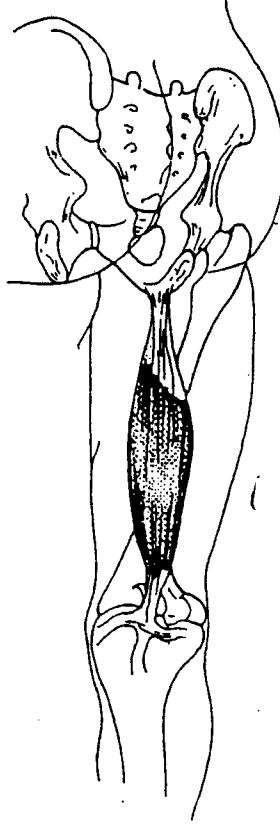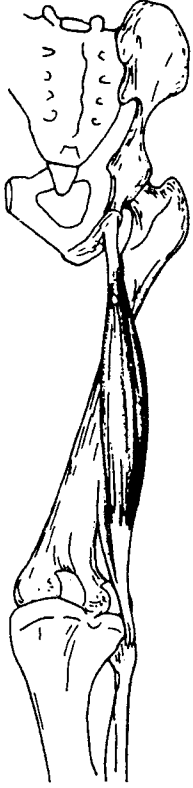


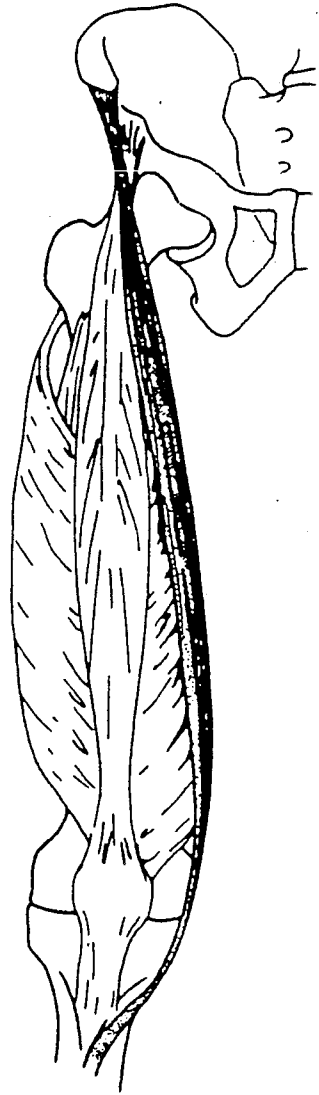

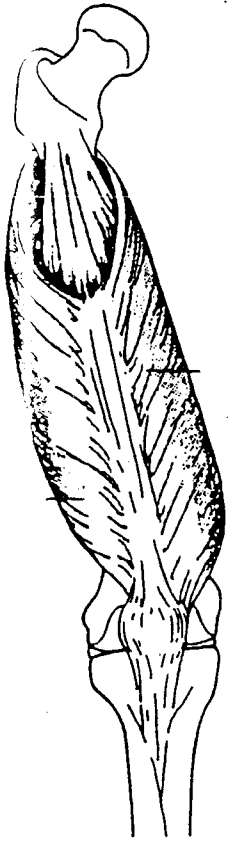
ADDUCTORS

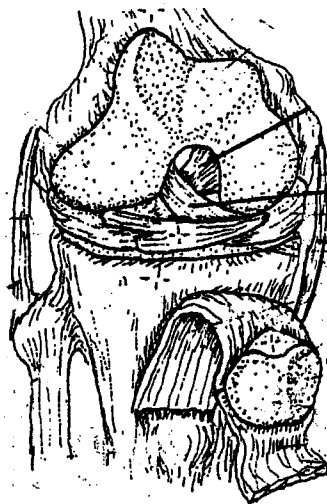
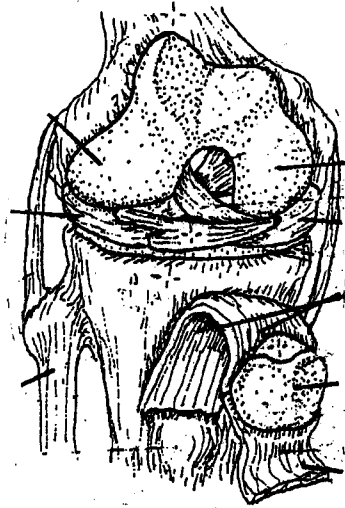


POSTERIOR MUSCLES OF HIP & KNEE

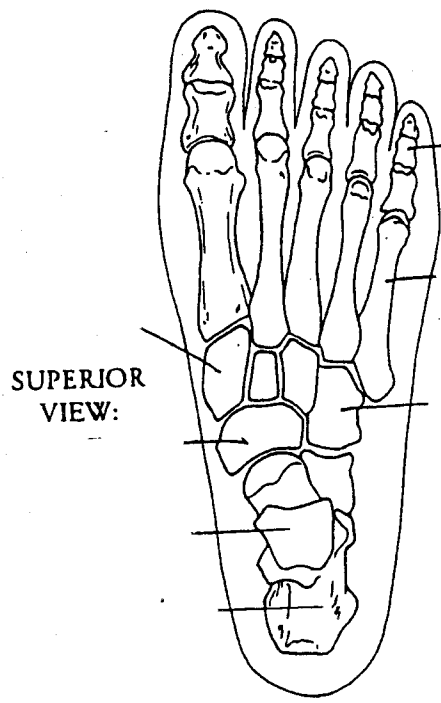
P10



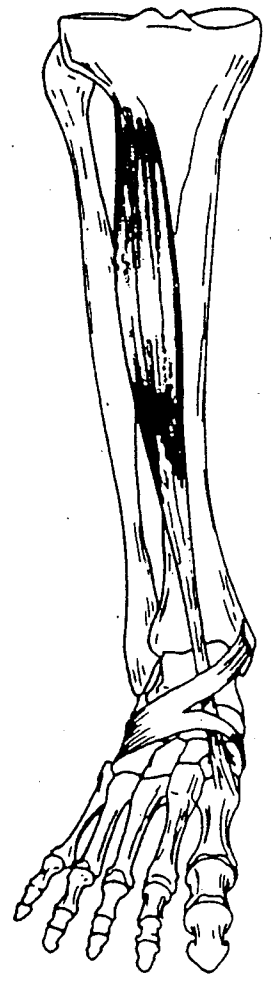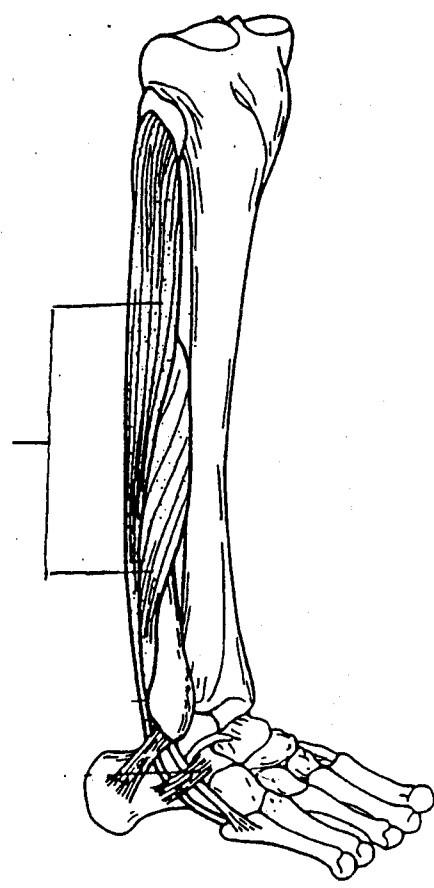


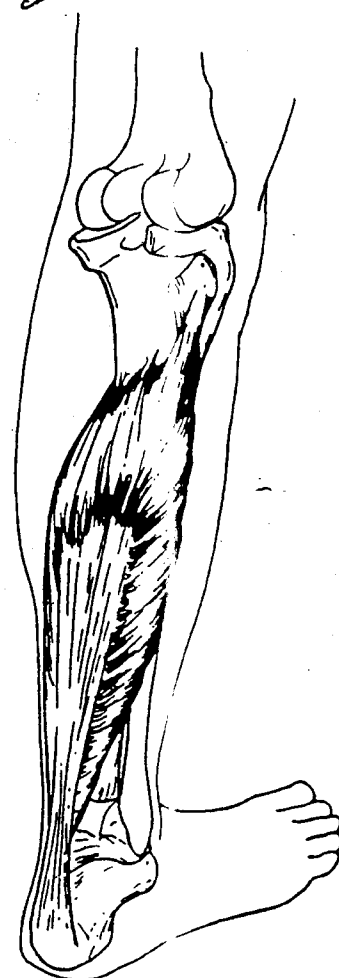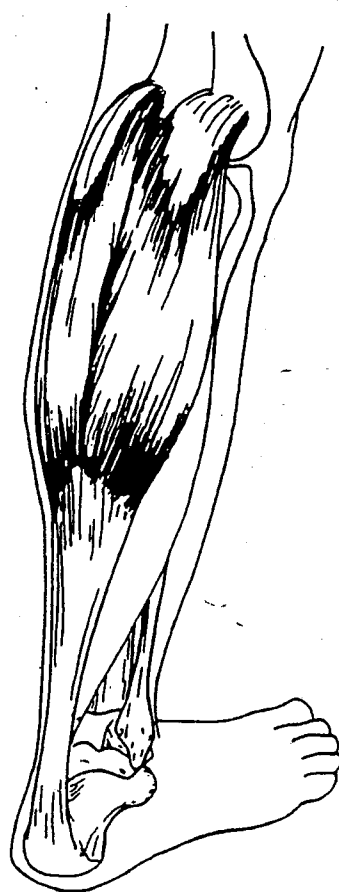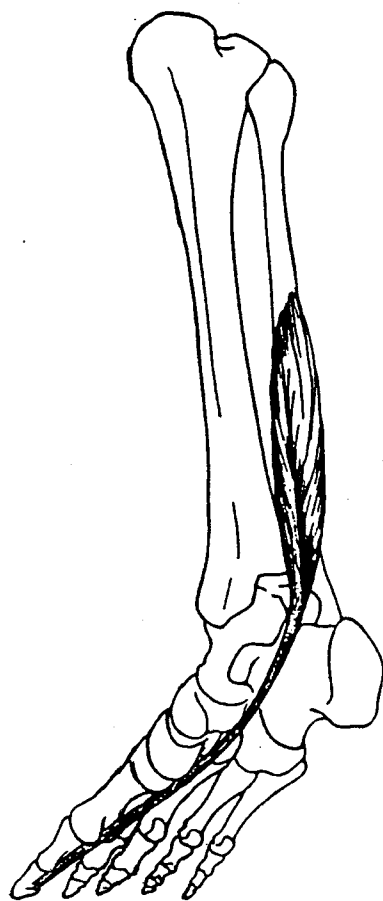
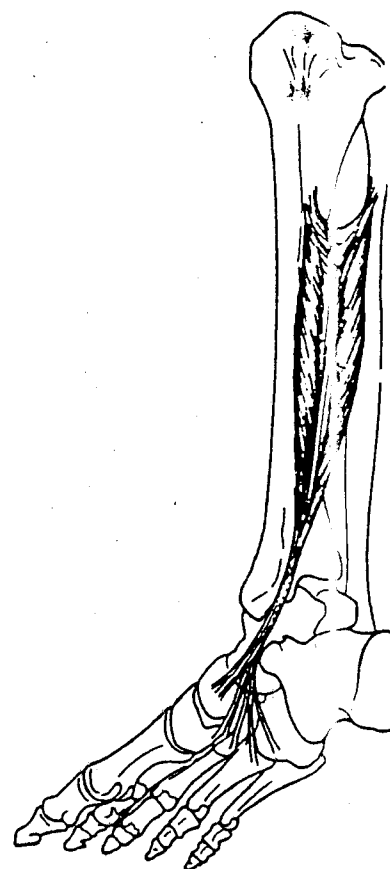
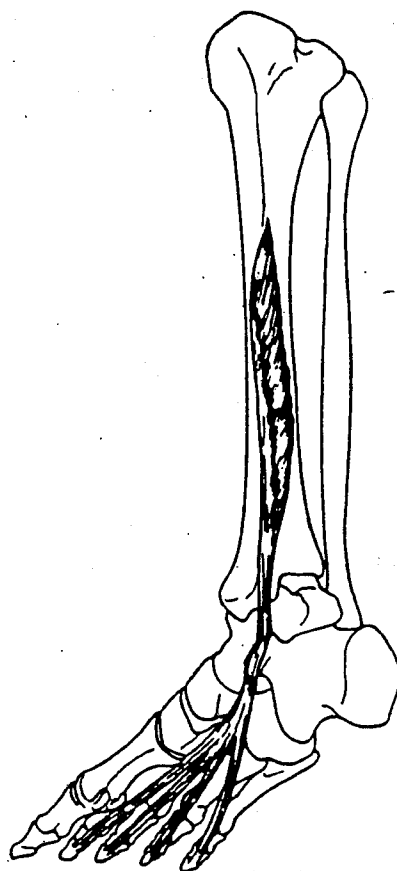



BONES

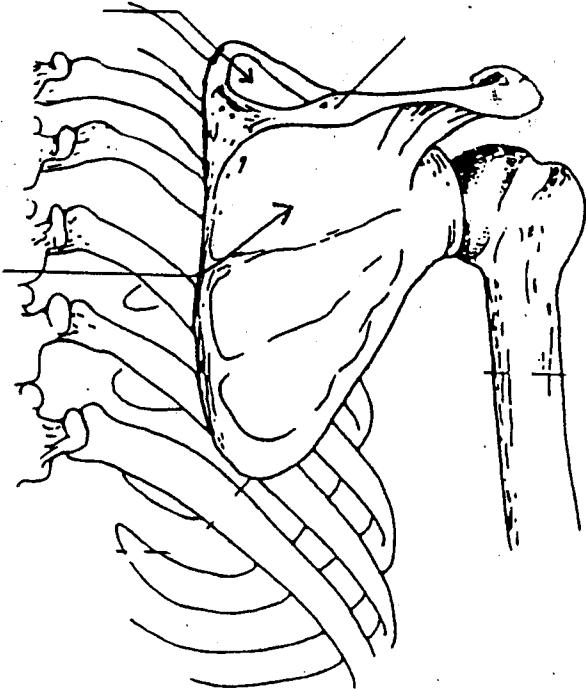
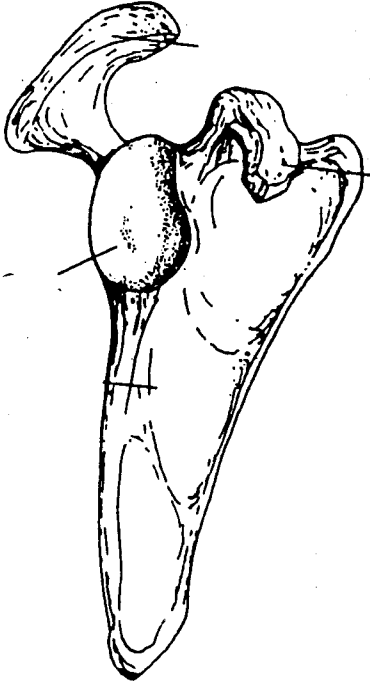


MUSCLES



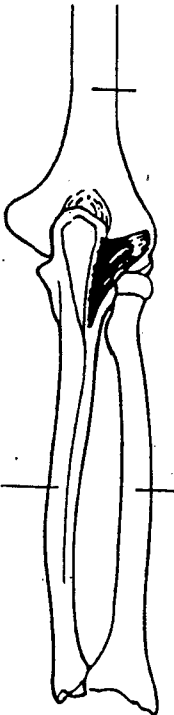


BONY LANDMARKS

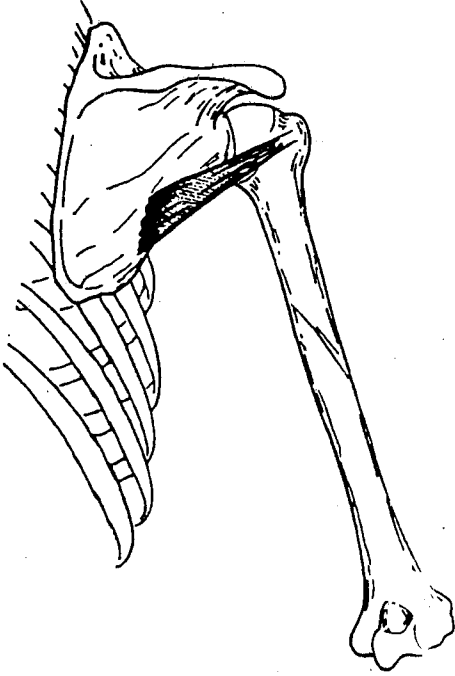
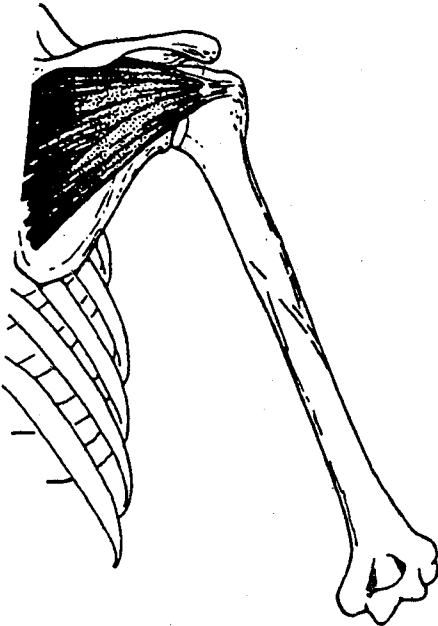
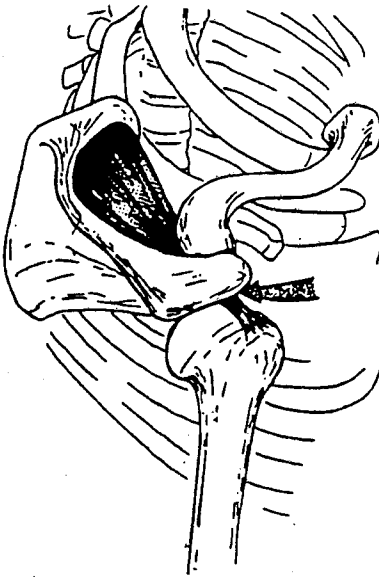
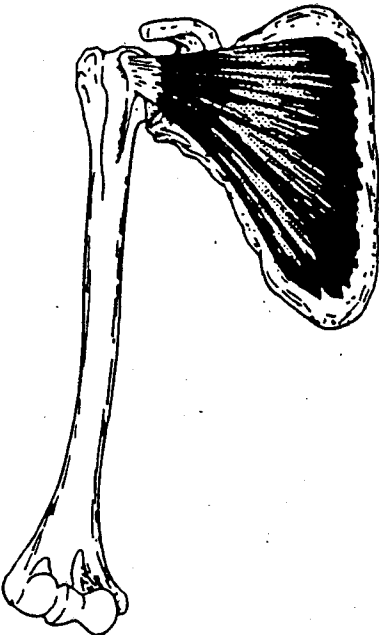

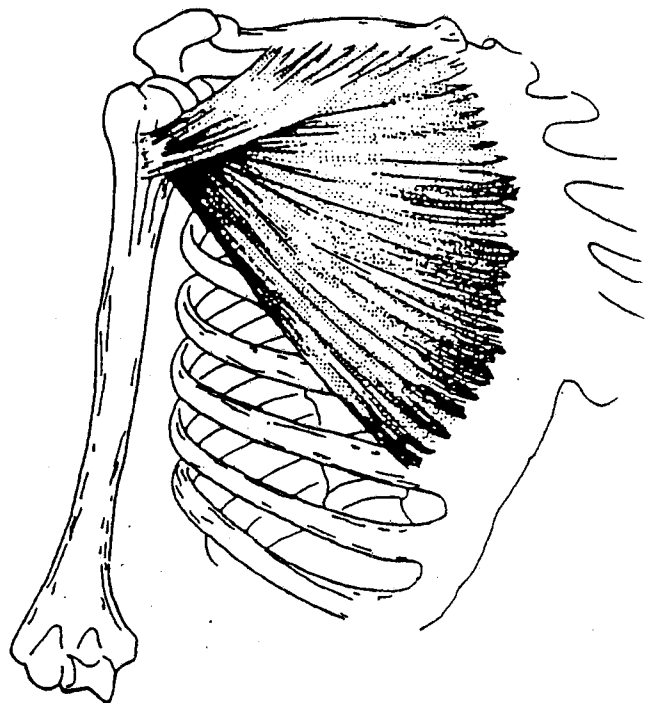
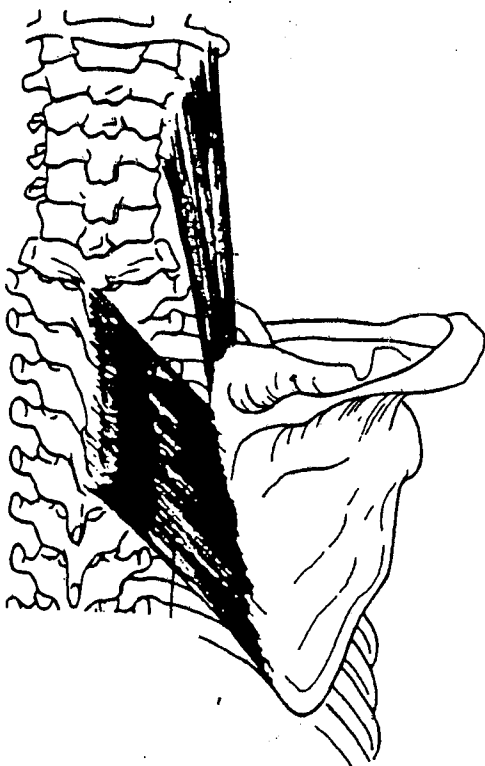
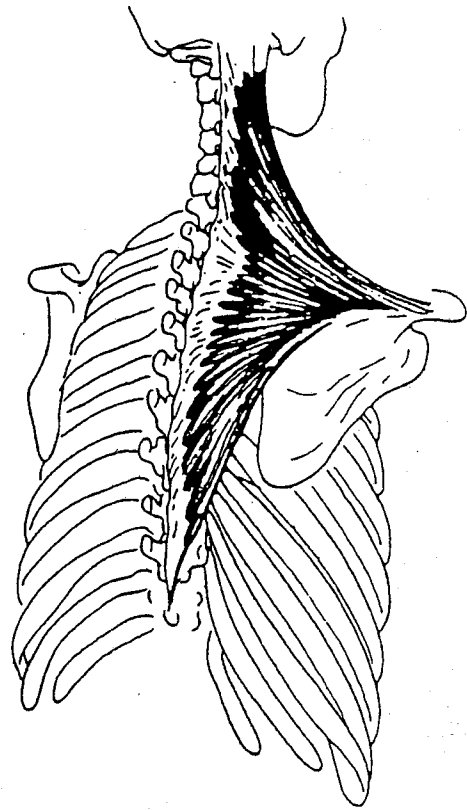
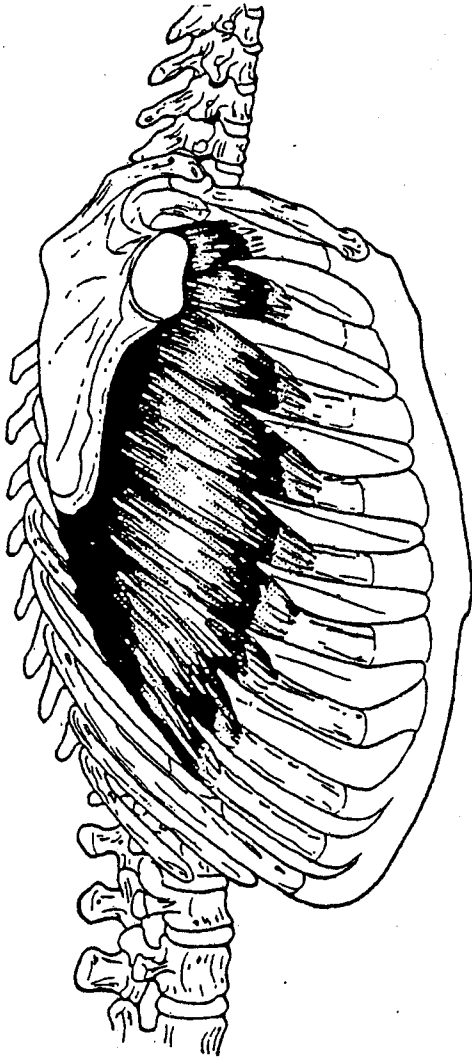
BONES

Right arm, posterior aspect



ROTATOR CUFF MUSCLES





MUSCLES OF UPPER EXTREMITY

