

NOTE

Detection of Rickettsiales-like Prokaryotes by *in Situ* Hybridization in Black Abalone, *Haliotis cracherodii*, with Withering Syndrome

Rickettsiales and Rickettsiales-like bacteria are emerging as significant pathogens of fish and shellfish (Fryer and Lannan, 1994; Fryer and Maule, 1997). Among shellfish, "withering syndrome" (WS) has been catastrophic to wild populations of black abalone, *Haliotis cracherodii*, in California (Haaker *et al.*, 1992; VanBlaricom *et al.*, 1993). Characterized by severe foot muscle atrophy and death, WS is presumably caused by a Rickettsiales-like prokaryote (RLP) that infects the epithelium lining the alimentary tract of the abalone (Gardner *et al.*, 1995; Friedman *et al.*, 1997). Signs of the disease and the RLP have recently been observed in red abalone, *Haliotis rufescens* (Moore *et al.*, 1999). Electron and light microscopic examinations of stained tissue sections are currently the principal methods employed to detect the organism (Gardner *et al.*, 1995). However, early stages of the infection are difficult to detect by light microscopy (VanBlaricom *et al.*, 1993). The use of DNA-based approaches, such as the polymerase chain reaction (PCR) and *in situ* hybridization (ISH) tests, may provide the sensitivity and specificity needed to detect and identify the agent in abalone. A nested PCR assay has been effective for diagnosing asymptomatic carriers of the Rickettsial pathogen *Piscirickettsia salmonis* among farmed salmon (Fryer *et al.*, 1992; Maule *et al.*, 1996). We have developed an ISH procedure to improve early detection of the RLP in abalone with WS. Additionally, the specificity of the ISH for the RLP was examined by testing three species of abalone with RLPs and other Rickettsiales-like organisms as found in two species of shellfish and two species of finfish.

Four probes derived from the small-subunit ribosomal DNA (rDNA) of the RLP were designed to hybridize with the RLP DNA present in abalone tissues (Andree *et al.*, submitted). An equivolume mixture of the four probes was tailed at the 3'-end with digoxigenin-labeled deoxyuridine-triphosphate (DIG-dUTP, Boehringer Mannheim) according to the manufacturer's instructions. Different probe combinations were labeled and tested by ISH to determine which mixtures would demonstrate the optimum binding ability (most intense hybridization signals) to homologous DNA of RLPs present in abalone tissues. The RLP rDNA was amplified and sequenced and the sequences of the

probes used for ISH are given below in the 5–3' direction (Andree *et al.*, submitted):

RA 5-1,	GTTGAACGTGCCTTCAGTTTAC;
RA 3-6,	ACTTGGACTCATTCAAAGCGGA;
RA 3-8,	CCACTGTGAGTGGTTATCTCCTG;
RA 5-6,	GAAGCAATATTGTGAGATAAAGCA.

The protocol for the RLP was adopted from the ISH procedure for detecting the myxosporean parasite *Myxobolus cerebralis* (Antonio *et al.*, 1998). Immediately after collecting field samples, abalone tissues were removed, fixed in shellfish Davidson's solution for 48–72 h, and then transferred to 70% ethanol. Using standard histological procedures (Humason, 1979), abalone tissues were embedded in paraffin, sectioned to 5–6 μm , adhered onto positively charged slides (Fisher Scientific), and then stored in slide boxes at room temperature until used for ISH and hematoxylin and eosin (H&E) staining.

A population of black abalone was collected at Vandenberg Air Force Base (Point Arguello, near San Luis Obispo, CA) during an epizootic attributed to WS. Farmed red abalone were also examined to determine if the RLPs were identical to those found in black abalone. Uninfected black abalone from Carmel Point ($n = 8$), where WS has not been observed, were included in the hybridization trials as negative controls. Black and red abalone infected with a renal coccidian (Friedman, 1990; Friedman *et al.*, 1995) and gregarine protozoans were also examined by ISH.

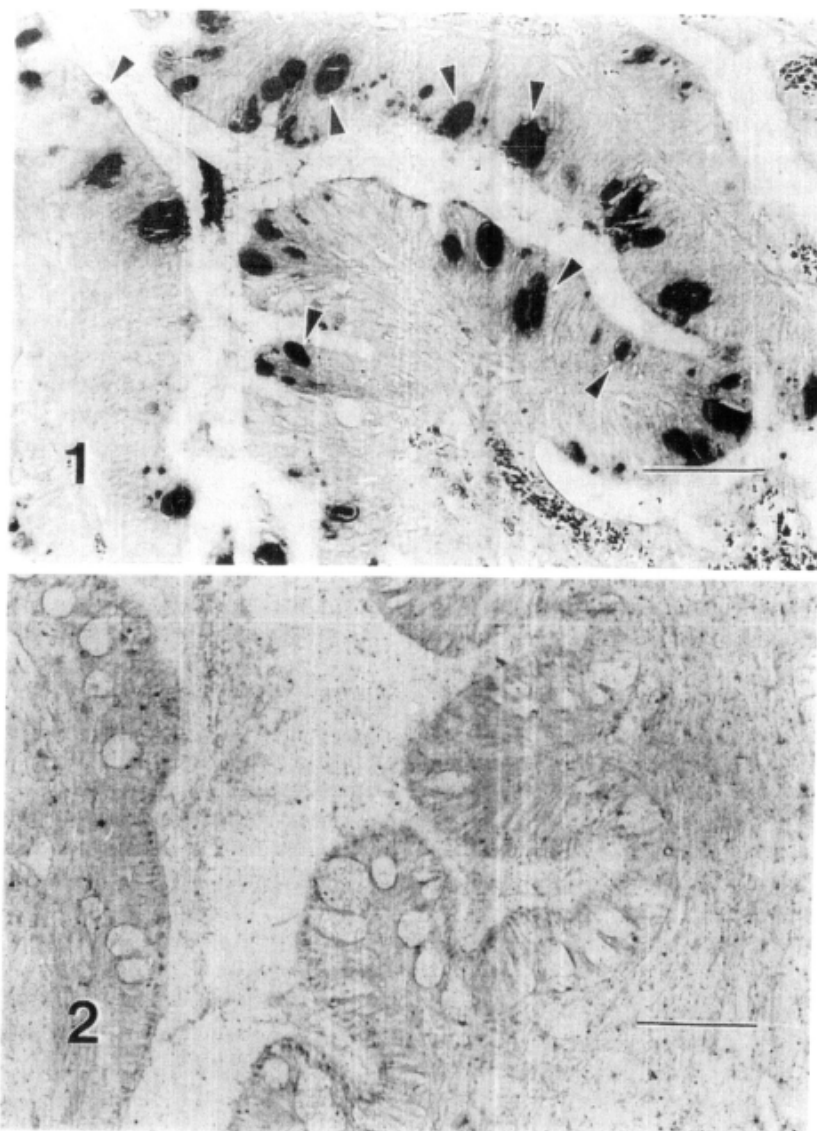
The specificity of the probe and the relationship of the RLP in abalone to other Rickettsiales-like organisms in shellfish and finfish were evaluated by ISH. The shellfish species tested included Geoduck clam, *Panope generosa*, and Pacific oyster, *Crassostrea gigas*. In addition, a single pink abalone, *Haliotis corrugata*, from Mexico showing inclusion bodies similar to those observed in black abalone was also included in the ISH trials. *Piscirickettsia salmonis* in coho salmon, *Oncorhynchus kisutch*, and a *P. salmonis*-like bacterium in white seabass, *Astracion nobilis*, were also tested for their ability to bind with the RLP DNA probe.

Binding of the labeled probes to the RLPs in infected black and red abalone tissues was evident in tissues of the alimentary tract (Fig. 1). The best results were obtained when the cocktail contained all four primers, as weaker binding was observed when only two or three primers were included. Hybridization signals were not observed in the tissues of all eight abalone examined from locations where the WS and the RLP have not been observed (Fig. 2).

The ISH protocol described by Antonio *et al.* (1998) was directly adopted for use in the current ISH trials without any significant modifications. Abalone tissues fixed in shellfish Davidson's solution showed more

intense signals than parallel tissues fixed in 10% neutral-buffered formalin. Moreover, hybridization and stringency washes at 40°C were effective for optimum binding of the probe and reducing backgrounds.

Positive hybridization signals were evident in inclusion bodies located in the epithelial cells of the alimentary system, including the esophagus, digestive gland, and intestines. However, the inclusions predominated in the epithelium of the postesophagus and digestive diverticula of infected abalone (Fig. 1). These inclusions ranged from small, focal, and deeply stained to large inclusion bodies with solid or diffuse precipitates. The distribution of the precipitates in the inclusion bodies



FIGS. 1 and 2. *In situ* hybridization of digestive diverticuli in black abalone, *Haliotis cracherodii*, following addition of the Rickettsiales-like prokaryote (RLP)-DNA probe labeled with digoxigenin-deoxyuridine-triphosphate. Tissues were fixed in shellfish Davidson's solution, paraffin-embedded, and then processed for routine histological procedures. Scale bar, 100 μ m. **Fig. 1.** Small and large inclusion bodies (arrowheads) in digestive diverticuli epithelium showing positive binding of RLP-DNA probe to homologous DNA. **Fig. 2.** Normal uninfected black abalone digestive diverticuli showing no hybridization signals.

may correspond to different developmental stages of the bacterium as described in the branchial Rickettsiales-like organisms found in the sea scallop, *Pecten maximus* (Le Gall *et al.*, 1988). The small or large deeply stained inclusions observed in abalone may contain rapidly multiplying early stages of the bacterium, resulting in a compact appearance. Alternatively, inclusion bodies showing diffuse precipitates may indicate slowly dividing RLPs in late stages of development.

The probe bound well to RLPs in inclusions found in black and red abalone, indicating that a similar or identical bacterium is infecting both abalone species. In addition, the RLP in the pink abalone from Mexico reacted positively with the WS RLP probes. Two protozoans commonly found in abalone, gregarines and the nonpathogenic coccidian (Friedman, 1990; Friedman *et al.*, 1993; Haaker *et al.*, 1992), were not recognized by the RLP-DNA probe. Although there was a mild nonspecific binding of the probe with the renal coccidian, they could be easily differentiated by their distinct shape, different host tissue, and absence of an inclusion body.

Rickettsiales-like bacteria found in other species of shellfish, including the Geoduck clam and Pacific oyster, did not bind with the RLP-DNA probe from abalone. Moreover, the RLP probe did not recognize *P. salmonis* in coho salmon or the *P. salmonis*-like organisms in white seabass.

The ISH technique for the RLP associated with WS should be useful in visualizing initial stages of infection with the prokaryotic organism in subclinically infected abalone. Early diagnosis of the RLPs is critical to control programs to prevent movements of infected wild or captive abalone or other shellfish species that may harbor the parasite. The procedure is currently being used to confirm the role of the RLP in the etiology of withering syndrome.

This work was funded, in part, by the Saltonstall-Kennedy Program of NOAA, Grant NA76FD0046, and the Marine Region of the California Department of Fish and Game. The views expressed herein are those of the authors and do not necessarily reflect the views of NOAA or any of its subagencies. The U.S. Government is authorized to reproduce and distribute this document for governmental purposes.

Key Words: black abalone; *Haliotis cracherodii*; Rickettsiales-like prokaryotes; RLPs; *in situ* hybridization.

REFERENCES

- Andree, K. B., Friedman, C. S., Moore, J. D., and Hedrick, R. P. 1999. A polymerase chain reaction assay for the detection of genomic DNA of a rickettsiales-like prokaryote associated with withering syndrome in black abalone (*Haliotis cracherodii*). *J. Shellfish Res.* [Submitted].
- Antonio, D. B., Andree, K. B., McDowell, T. S., and Hedrick, R. P. 1998. Detection of *Myxobolus cerebralis* in rainbow trout and oligochaete tissues by using a nonradioactive *in situ* hybridization (ISH) protocol. *J. Aquat. Anim. Health.* **10**, 338–347.
- Friedman, C. S. 1990. Coccidiosis of California abalone, *Haliotis* spp. *J. Shellfish Res.* **10**, 236.
- Friedman, C. S., Roberts, W., Kismohandaka, G., and Hedrick, R. P. 1993. Transmissibility of a coccidian parasite of abalone, *Haliotis* spp. *J. Shellfish Res.* **12**, 201–205.
- Friedman, C. S., Gardner, G. R., Hedrick, R. P., Stephenson, M., Cawthorn, R. J., and Upton, S. J. 1995. *Pseudoklossia haliotis* sp. n. (Apicomplexa) from the kidney of California abalone, *Haliotis* spp. (Mollusca). *J. Invertebr. Pathol.* **66**, 33–38.
- Friedman, C. S., Thomson, M., Chun, C., Haaker, P. L., and Hedrick, R. P. 1997. Withering syndrome of the black abalone, *Haliotis cracherodii* (Leach): Water temperature, food availability, and parasites as possible causes. *J. Shellfish Res.* **16**, 403–411.
- Fryer, J. L., Lannan, C. N., Giovanni, S. J., and Wood, N. D. 1992. *Piscirickettsia salmonis* gen. nov. sp. nov., the causative agent of an epizootic disease in salmonid fishes. *Int. J. Syst. Bacteriol.* **42**, 120–126.
- Fryer, J. L., and Lannan, C. N. 1994. Rickettsial and chlamydial infections of freshwater and marine fishes, bivalves, and crustaceans. *Zool. Studies* **33**, 95–107.
- Fryer, J. L., and Mauel, M. J. 1997. The rickettsia: An emerging group of pathogens in fish. *Emerging Infect. Dis.* **3**, 137–144.
- Gardner, G. R., Harsbarger, J. C., Lake, J. L., Sawyer, T. K., Price, K. L., Stephenson, M. D., Haaker, P. L., and Togstad, H. A. 1995. Association of prokaryotes with symptomatic appearance of withering syndrome in black abalone *Haliotis cracherodii*. *J. Invertebr. Pathol.* **66**, 111–120.
- Haaker, P. L., Richards, D. V., Friedman, C. S., Davis, G. E., Parker, D. O., and Togstad, H. A. 1992. Mass mortality and withering syndrome in black abalone, *Haliotis cracherodii*, in California. In "Abalone of the World: Biology, Fisheries, and Culture" (S. A. Shepherd, M. J. Tegner, and P. Guzman del Proo, Eds.), pp. 214–224. Blackwell Sci., Oxford.
- Humason, G. L. 1979. "Animal Tissue Techniques." Freeman, San Francisco.
- Le Gall, G., Chagot, D., Mialhe, E., and Grizel, H. 1988. Branchial Rickettsiales-like infection associated with a mass mortality of sea scallop *Pecten maximus*. *Dis. Aquat. Org.* **4**, 229–232.
- Mauel, M. J., Giovanni, S. J., and Fryer, J. L. 1996. Development of polymerase chain reaction assays for detection, identification, and differentiation of *Piscirickettsia salmonis*. *Dis. Aquat. Org.* **26**, 189–195.
- Moore, J. D., Robbins, T. T., and Friedman, C. S. 2000. Withering syndrome in farmed red abalone, *Haliotis rufescens*. *J. Aquat. Anim. Health*, in press.
- VanBlaricom, G., Ruediger, J., Woodard, D., Friedman, C. S., and Hedrick, R. P. 1993. Symptomatic appearance of withering syndrome at San Nicolas Island. *J. Shellfish Res.* **12**, 185–188.

Dolores B. Antonio*
Karl B. Andree*
James D. Moore†
Carolyn S. Friedman†
Ronald P. Hedrick*¹

*School of Veterinary Medicine, Department of Medicine and Epidemiology, University of California, Davis, California 95616; and
†California Department of Fish and Game and Bodega Marine Laboratory, University of California, 2099 Westside Road, Bodega Bay, California 94923

Received May 3, 1999; accepted September 13, 1999

¹To whom correspondence should be addressed. E-mail: rphedrick@ucdavis.edu.