

INTEGRATED™

SHOULDER SYSTEM FRACTURE TECHNIQUE



SURGICAL TECHNIQUE

PATIENT POSITIONING

The patient is placed in a modified beach chair position at 30 degrees of inclination after general or regional anesthetic has been induced and a prophylactic dose of a broad-spectrum antibiotic has been administered. The bladder is catheterized only when requested by the anesthesiologist for fluid management (Fig. 1). The patient is lateralized on the edge of the table so that the arm can be extended off the side.

APPROACH

The skin incision for an extended deltopectoral approach has been marked. The incision will begin over the clavicle, directly superior to the coracoid process, and pass over the coracoid, sweeping laterally and distally to end at the insertion of the deltoid onto the humerus (Fig. 2 and 3). This approach allows for detachment of part of the deltoid insertion if further mobilization of the deltoid is required.

As dissection proceeds, the cephalic vein will be sought as the landmark of the deltopectoral interval. This vein is usually identified by its surrounding fatty tissue (Fig. 4).

DISSECTION OF SOFT TISSUE

The cephalic vein is usually firmly embedded in the deltoid, and there are many feeders from the deltoid to the cephalic vein. For this reason, the vein should not be sacrificed, but should be reflected laterally with the deltoid muscle. The distal deltoid may be partially released from its humeral insertion, but the proximal origin should not be violated.

In fracture cases, it is especially important to identify and protect the musculocutaneous and axillary nerves. Palpate the musculocutaneous nerve as it comes from the plexus into the posteromedial aspect of the conjoined tendon (Fig. 5). With further dissection the medial branches of the cephalic vein that cross the incision are identified, divided, and cauterized. Next, the clavipectoral fascia will be divided and the conjoined tendon retracted, avoiding traction on the musculocutaneous nerve, which lies medial to the coracoid process. Usually the nerve penetrates the muscle one to two inches inferior to the tip of the coracoid process, but in some instances, the nerve has a higher penetration into the conjoint muscle tendon unit. It is important to remember the location of this nerve when retracting the conjoined tendon. A partial tenotomy will relax the tension on the nerve during exposure.

IDENTIFYING THE LESSER AND GREATER TUBEROSITY FRAGMENTS USING THE BICEPS

The biceps tendon and bicipital groove afford the most useful anatomic landmark for identification of the fractured tuberosity fragments. Place a pair of scissors into the sheath of the biceps tendon and use them to divide the transverse ligament (Fig. 6). Continuing proximally with the scissors, open the interval between the subscapularis and the supraspinatus tendons all the way up to the insertion of the biceps tendon into the supraglenoid tubercle. Even if the biceps tendon is ruptured, place the scissors into the bicipital groove and use them to open the interval between the subscapularis and the supraspinatus tendon. Next free up the lesser

This summary represents the surgical technique of Edward V. Craig, M.D. and George M. McCluskey III, M.D. Biomet, as the manufacturer of this device, does not practice medicine and does not recommend any particular surgical technique for use on a specific patient. The surgeon who performs any implant procedure is responsible for determining and utilizing the appropriate techniques for implanting the prosthesis in each individual patient. Biomet is not responsible for selection of the appropriate surgical technique to be utilized on an individual patient.

The Neer II™ was designed in conjunction with Charles S. Neer II, M.D.

The Modular II-C™ and Atlas® were developed in conjunction with Edward V. Craig, M.D. and Richard F. Kyle, M.D.




Figure 1

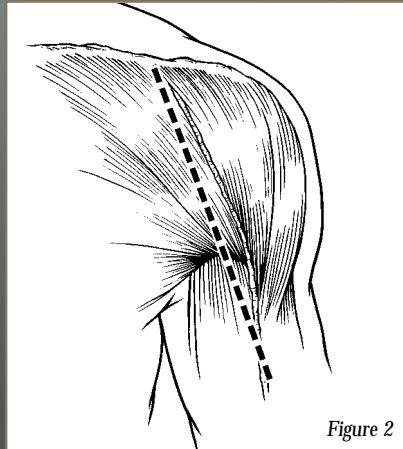


Figure 2

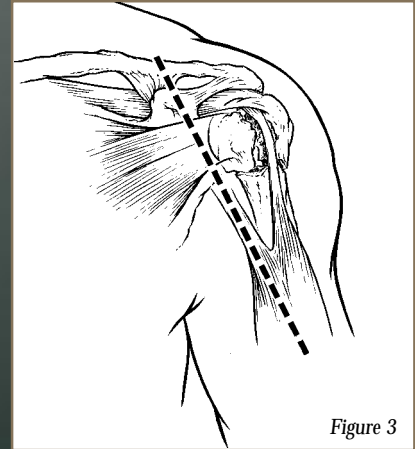


Figure 3

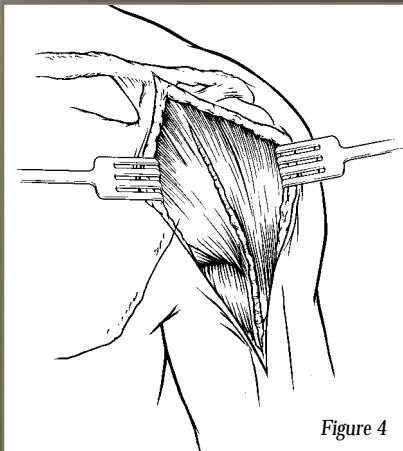


Figure 4

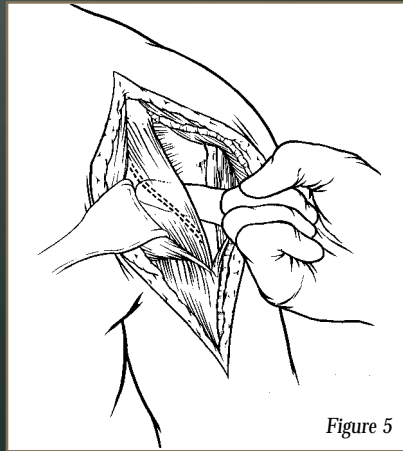


Figure 5

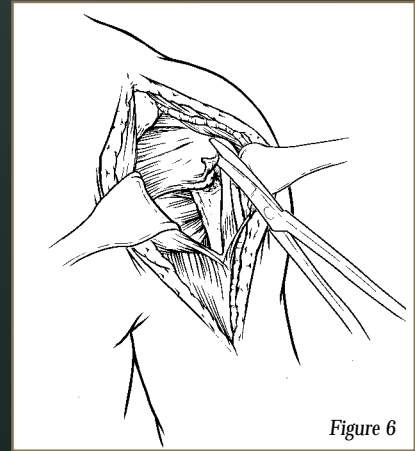


Figure 6

INTEGRATED™

SHOULDER SYSTEM FRACTURE TECHNIQUE

SURGICAL TECHNIQUE

tuberosity from the underlying humeral head and soft tissue (Fig. 7). The surgeon may need to complete the fracture with an osteotome or elevator. Be careful to protect the axillary nerve during mobilization of both the lesser and greater tuberosity and the attached subscapularis muscle tendon unit. Once the tuberosities have been identified, nonabsorbable tag sutures are placed in each. The greater and lesser tuberosity fragments must be sufficiently freed, so that they can be easily repaired around the prosthesis and to each other at the time of closure (Fig. 8).

HUMERAL HEAD OSTEOTOMY AND SIZING

The articular segment of the humeral head is identified and removed and is sized with calipers or by direct comparison to the modular head trials offered by the Integrated Shoulder System. The head size is selected using the resected humeral head as a template (Fig. 9). The actual head size is selected according to the ease of reconstruction of the tuberosities around the prosthetic replacement while the proper soft-tissue tension is maintained. In general, the largest head size that allows for closure of the rotator cuff and tuberosities around the fin should be selected. The Integrated Shoulder System has both fixed head stems and modular stems. The fixed heads would utilize the resected head as a template to measure the size of the humeral head. The modular stems can utilize a trial head to compare size to the resected head. Sequential trialing is begun until function is restored. The surgeon must assess the proximal humerus for shortening due to proximal comminution. The surgeon will need to consider this in placement of the prosthesis if comminution is present. At this point, one should evaluate the glenoid surface. If it is damaged significantly, glenoid replacement should be carried out.

HUMERAL SHAFT PREPARATION

The humeral shaft is now prepared. This is facilitated by extension and external rotation of the humerus. T-handle reamers are used to sequentially ream the canal to the correct size stem (Fig. 10). Often the medial calcar has been comminuted, leaving only a diaphyseal portion of the humerus intact. This bone loss must be recognized so that the prosthesis can be placed in appropriate anatomic position to recreate appropriate humeral length.

HUMERAL STEM INSERTION

After sequential reaming, the appropriate humeral stem size is selected according to the final reamer utilized. The proper stem

size is the stem diameter that will allow the humeral head to be seated to the proper depth, yet will be large enough to provide a measure of stability to the prosthesis. This is gauged three ways in fracture management cases. First, the humeral head should face directly toward the glenoid articular surface with the elbow flexed 90 degrees and the hand in the neutral position. Second, the forearm can be used as one limb of a goniometer and the second limb is the transverse axis of the elbow. The trial prosthesis is inserted in 30 to 35 degrees of retroversion with respect to the transverse axis of the elbow. To accurately estimate this it may be helpful to hyperextend the arm and look down at the prosthesis-elbow angle from above. If a chronic fixed posterior dislocation with associated humeral head of greater than 50 percent is being treated, then less retroversion will be necessary. Third, the fin of the prosthesis can be placed just posterior (lateral) to the bicipital groove. This will place the prosthetic head in the appropriate amount of retroversion. The trial prosthesis is also used to check for correct sizing and humeral length. This is done intraoperatively by attempting to sublux the humerus inferiorly. Normally the humeral component should travel 25 to 50 percent of the length of the glenoid with inferior traction. If more than that is possible during trialing then the prosthesis is seated too low. In this case the deltoid function will be poor because of instability and weakness (Fig. 11). If there is no inferior play, the humerus is too high and should be sunk deeper into the shaft. In this case the implant is prone to impingement on the acromion and can cause excessive wear on the superior glenoid surface with resultant stiffness and pain (Fig. 12).

Before cementing the appropriate stem, multiple drill holes are made in the lateral aspect of the humeral shaft and #5 nonabsorbable sutures are placed through the drill holes so that they emerge from the intramedullary canal. The sutures will be used later for lateral tuberosity attachment via a "figure 8" suture closure. After final check of the stem fit and placement with the trial implant, the canal is prepared and dried. The stem is cemented in the appropriate amount of retroversion (30 to 35 degrees). (There will be less retroversion in cases of fixed posterior dislocation.)

ATLAS ASSEMBLY SECTION

The Atlas® Shoulder System is a tri-modular design consisting of a proximal body, a distal stem extension, and a modular head. This design gives the surgeon the flexibility to size proximal and distal diameters independently allowing for more precise patient matching. (For example, the surgeon can use a 9.5mm proximal

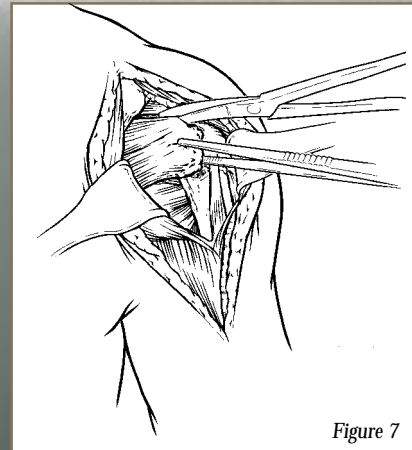


Figure 7

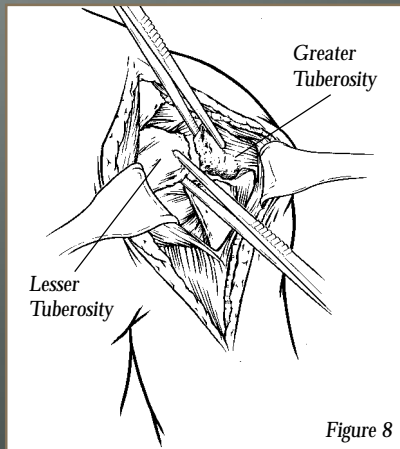


Figure 8

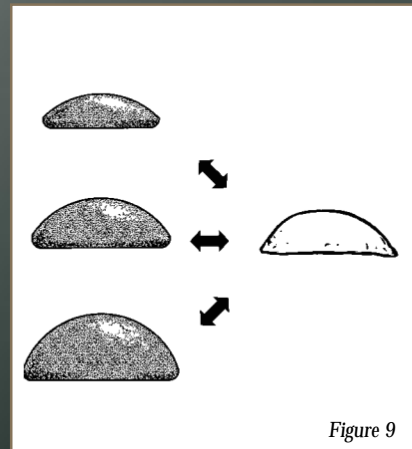


Figure 9

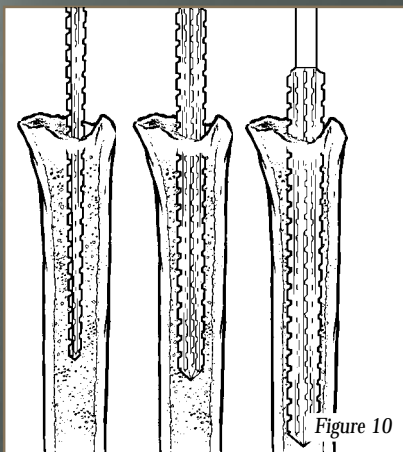


Figure 10

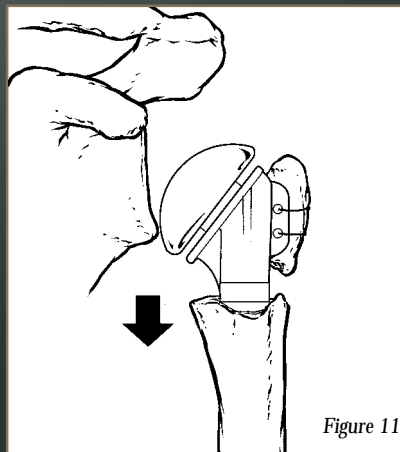


Figure 11

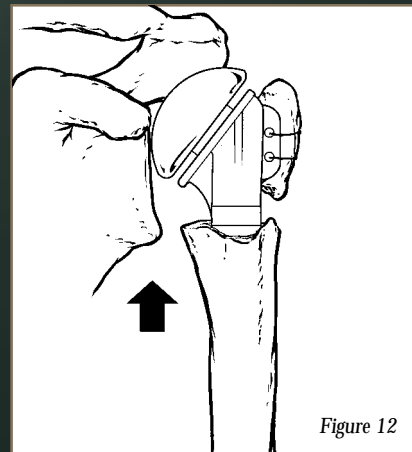


Figure 12

INTEGRATED™

SHOULDER SYSTEM FRACTURE TECHNIQUE

SURGICAL TECHNIQUE

body with a 12.7mm distal stem extension.) The canal is reamed until there is cortical chatter; this will be the stem diameter needed. It is not necessary to ream for the proximal body because it can be sized independently by inserting proximal trial bodies into the proximal portion of the humerus until there is a snug fit (Fig. 13). To assemble the Atlas, tighten the proximal body and distal stem extension together before implanting (Fig. 14).

TRIALING THE HUMERAL HEAD

Once the stem has been cemented, the trial modular head component is chosen. Using the measurements of the patient's own articular segment as a guide, the proper height of the humeral head trial is chosen. The trial is placed on the stem and the joint is reduced. With tension maintained in the tuberosities, anterior and posterior stability, and ROM are assessed. The surgeon should attempt to recreate a 50 percent override of the head anteriorly, posteriorly, and inferiorly with respect to the glenoid. In addition, a full range of forward flexion and abduction should be possible without tuberosity impingement. The surgeon will trial until all of the criteria are fulfilled. The humeral head implant is then impacted.

When using the Neer II fixed head prosthesis: first prepare the canal and insert a trial stem to obtain the proper amount of retroversion as previously discussed. The trial stem will now allow the surgeon to check for proper length of the humerus, height of the head, and version of the head. Once the proper position is found, the humeral implant will be cemented.

The proper height will permit reconstruction of the tuberosities around the fin of the prosthesis. The top of the head should rest a few millimeters superior to the top of the greater tuberosity. This position will usually ensure proper soft-tissue tension, keep the prosthesis stable, and allow for maximum rehabilitation of the muscles moving the implant.

TUBEROSITY REATTACHMENT

This is the most critical part of the procedure. There are many variations acceptable. However the goal is to securely fix the tuberosities to the shaft and to themselves. The tuberosities are fixed in place with nonabsorbable sutures. The tuberosities must not be excised because bone healing is essential to ensure the continuity of the rotator cuff tendon, and the tendons cannot be expected to heal to the metal implant. Therefore, despite what

may be very significant comminution, the tuberosities must be preserved. Three drill holes are made in each of the greater and lesser tuberosities (Fig. 15). A heavy, nonabsorbable suture is passed through each of the two more superior drill holes in the tuberosities. These sutures will be used to secure the tuberosities to one another and to the fin of the prosthesis. The most inferior drill holes in the tuberosities will be used to bring the humeral-shaft sutures through the tuberosities, securing the tuberosities to the humeral shaft. When the sutures have been tied to the fin of the prosthesis, bone graft from the humeral head is packed underneath the tuberosities. (Fig. 16 and 17). In cases of osteopenic bone or comminution, sutures may not have good fixation in the bone. The surgeon may need to put one fin suture through the bone-tendon junction. Figure 18 demonstrates an exploded view of suture placement in reattachment of the tuberosities.

The rotator interval is closed and the biceps tendon is replaced in its groove to complete reconstruction. The tuberosities should be positioned below the top of the humeral head component. Secure reconstruction of tuberosities to the humeral shaft and to each other is critical, because inadequate fixation may lead to mal-union or non-union.

The stability and security of the prosthesis is then checked intraoperatively by rotating the arm externally and internally and checking the security of bone-prosthetic attachments. At this point, the arm is brought up into forward elevation, and any tension on the sutures and tuberosities identified. This information is critical to establishing range of motion limitations during early rehabilitation. The tuberosity segments must be secured to one another and to the shaft if early range of motion is to be permitted. The sutures are closed securing the tuberosities to the humeral shaft and to one another (Fig. 19).

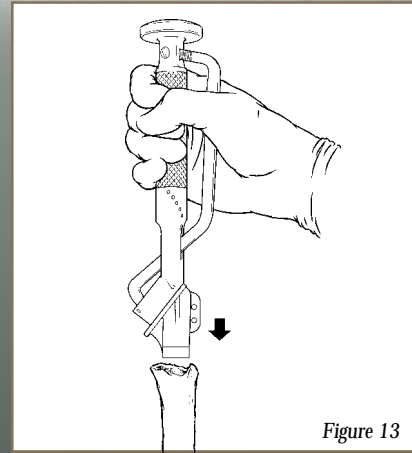


Figure 13

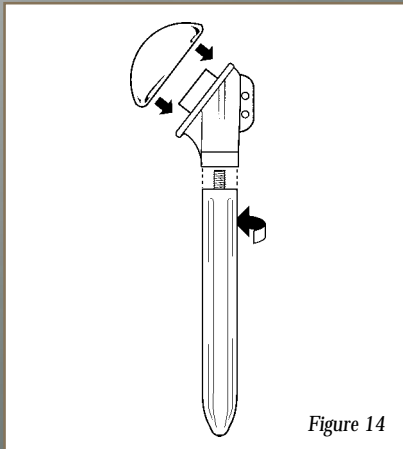


Figure 14

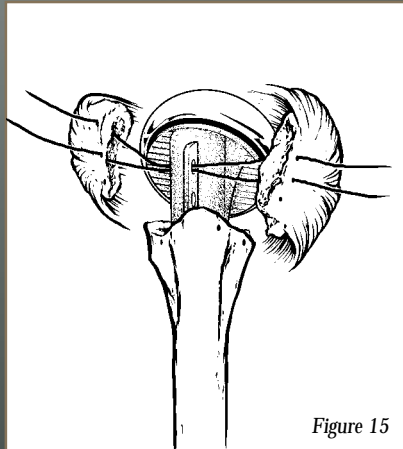


Figure 15

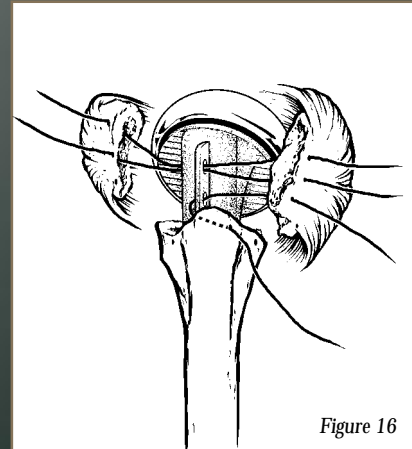


Figure 16

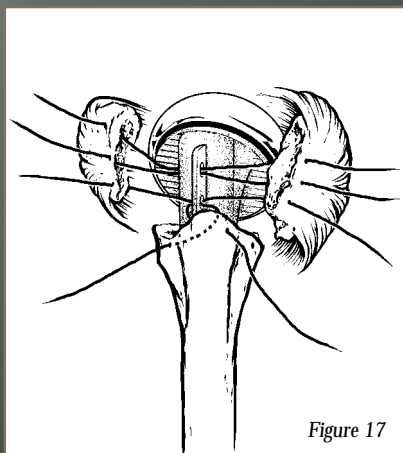


Figure 17

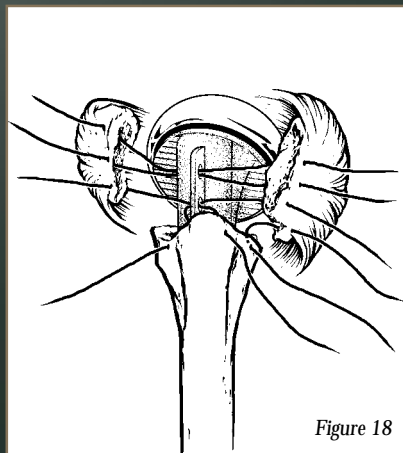


Figure 18

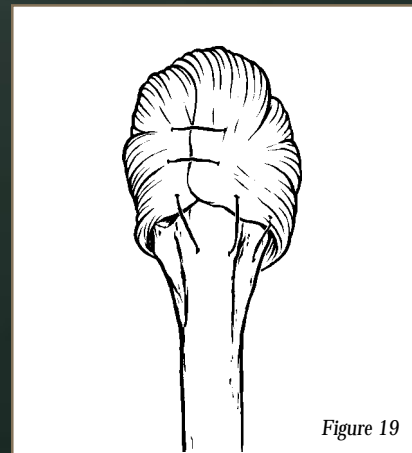


Figure 19

INTEGRATED™

SHOULDER SYSTEM FRACTURE TECHNIQUE

CLOSING

A drain is placed below the deltoid muscle, and the delto-pectoral interval is closed. The wound is then closed in layers.

REHABILITATION

Rehabilitation has been recognized as being critical for optimal results in all aspects of shoulder surgery.

FIRST PREOPERATIVE DAY

1. Passive and active ROM exercises for the elbow, hand, and wrist can be initiated.
2. The patient should perform pendulum exercises four to six times per day.
3. The patient should use his or her hand and arm for gentle everyday activities, such as eating, brushing teeth, and drinking.

SECOND AND THIRD POSTOPERATIVE DAY

The patient should continue to do passive flexion and external rotation exercises. The patient can begin use of an overhead pulley to increase passive flexion and continue to use the arm for everyday activity.

TWO TO SIX WEEKS POSTOPERATIVE

Attempt to gain 150 degrees of passive ROM in forward elevation within the first two weeks. If the patient does not have sufficient passive range of motion, institute more stretching exercises such as wall climbing, additional overhead stretching with the pulley, posterior capsule stretching, etc. Utilize arm more for everyday activities. Nonisometric resistance exercises using rubber tubing can begin at approximately 6 weeks.

*Integrated is a trademark of Biomet, Inc.
Atlas® is a registered of Biomet, Inc.*

U.S. Patent No. 5,507,817

SIX TO TWELVE WEEKS POSTOPERATIVE

1. Continue stretching exercises of the shoulder four to six times per day.
2. Gradually begin strengthening exercises of the deltoid and rotator cuff muscles with Therabands.
3. Exercise with light weights.

CONCLUSION

The reproduction of normal humeral length, appropriate retroversion of the humerus, and stable tuberosity fixation is mandatory for a successful result in hemiarthroplasty for acute fractures of the proximal humerus. Successful results can be expected if the patient agrees to undergo extensive rehabilitation after surgery, and all the criteria for a fracture of the proximal humerus are met.

